

# Treatment of Giant Arachnoid Cysts on Spinal Cord - Relevant Surgical Aspects

## *Tratamento do cisto aracnóideo gigante em medula espinhal - aspectos cirúrgicos relevantes*

Victor Rosseto Barboza<sup>1</sup> João Luiz Vitorino Araujo<sup>2,4</sup> Vinicius Ricieri Ferraz<sup>3</sup> Luciano Haddad<sup>1</sup>  
Vinicius Monteiro de Paula Guirado<sup>4</sup> José Carlos Esteves Veiga<sup>5</sup>

<sup>1</sup>Neurosurgeon, Neurosurgery, Santa Casa de São Paulo, São Paulo, SP, Brazil

<sup>2</sup>Neurosurgeon, Instituto do Câncer Arnaldo Vieira de Carvalho, São Paulo, SP, Brazil

<sup>3</sup>Resident, Neurosurgery, Santa Casa de São Paulo, São Paulo, SP, Brazil

<sup>4</sup>Assistant Physician, Neurosurgery, Santa Casa de São Paulo, São Paulo, SP, Brazil

<sup>5</sup>Professor, Neurosurgery, Santa Casa de São Paulo, São Paulo, SP, Brazil

Address for correspondence Vinicius Ricieri Ferraz, MD, Irmandade da Santa Casa de Misericórdia de São Paulo, São Paulo, SP, Brazil (e-mail: [viniciusferraz@hotmail.com](mailto:viniciusferraz@hotmail.com)).

Arq Bras Neurocir 2016;35:212–217.

### Abstract

**Objectives** The aim of the present study was to demonstrate that microsurgical resection of the posterior portion of giant spinal arachnoid cyst can be effective in the treatment of patients.

**Methods** We selected three cases that consecutively underwent spinal surgery with microsurgical technique who were admitted to our institution. They were treated and followed-up, rehabilitation being performed weekly and quarterly medical consultation. The three patients were informed about the research and ethical aspects and agreed to participate with the exposure of their complete medical history. All cases were approved by the Institutional Review Board. These three cases were used to illustrate the surgical treatment used by our team to discuss the best treatment option.

**Results** Three patients underwent microsurgical resection of the posterior portion of giant spinal arachnoid cyst. This surgical technique had its use justified by the possibility of reducing the incidence of CSF leak, since lesions were extradural. The treated patients presented clinical improvement, which was maintained for more than twelve months.

**Conclusion** Although some authors state that complete resection of the cyst is the best surgical option, we believe that, specifically on giant spinal arachnoid cysts, the resection of the posterior portion of the cysts may decrease postoperative CSF leak incidence. Furthermore, our series suggests that the adopted surgical treatment may lead to better functional outcomes while this treatment is performed for spinal decompression using a less invasive technique and, thus, leading to an earlier clinical improvement.

### Keywords

- ▶ arachnoid cyst
- ▶ spine surgery
- ▶ spinal cord
- ▶ microsurgery
- ▶ neurosurgery

received  
December 31, 2015  
accepted  
April 2, 2016  
published online  
May 23, 2016

DOI <http://dx.doi.org/10.1055/s-0036-1584201>.  
ISSN 0103-5355.

Copyright © 2016 by Thieme Publicações  
Ltda, Rio de Janeiro, Brazil

License terms



## Resumo

**Objetivos** O objetivo deste estudo é demonstrar que ressecção microcirúrgica da porção posterior de um cisto aracnóideo gigante na medula pode ser eficiente no tratamento de pacientes.

**Métodos** Três casos de pacientes admitidos em nossa instituição que foram submetidos à cirurgia da medula com técnica de microcirurgia, tratados e acompanhados com reabilitação realizada semanal e trimestralmente. Os três pacientes foram informados sobre a pesquisa e os aspectos éticos, concordando em participar com a publicação de seus históricos médicos. Todos os casos foram aprovados pelo Conselho Institucional de Revisão. Estes três casos foram usados para ilustrar o tratamento cirúrgico usado pela nossa equipe para discutir a melhor opção de tratamento.

**Resultados** Os três pacientes foram submetidos à ressecção microcirúrgica da porção posterior de um cisto aracnóideo gigante na medula. Esta técnica cirúrgica teve seu uso justificado pela possibilidade de redução da incidência de vazamento de líquido cerebrospinal (*CSF leak*), desde que as lesões sejam extradural. Os pacientes tratados apresentaram melhoria clínica, mantida por mais de doze meses.

**Conclusão** Apesar de alguns autores afirmarem que a ressecção completa do cisto é a melhor opção cirúrgica, acreditamos que, especificamente para cistos aracnóideos gigantes da medula, a ressecção da porção posterior do cisto deve reduzir a incidência de *CSF leak* pós-operatório. Além disso, nossos resultados sugerem que o tratamento cirúrgico adotado possa levar a resultados funcionais melhores enquanto este tratamento for usado para descompressão espinhal usando a técnica menos invasiva, consequentemente permitindo melhora clínica antecipada.

## Palavras-chave

- ▶ cisto aracnóideo
- ▶ cirurgia da espinha
- ▶ medula espinhal
- ▶ microcirurgia
- ▶ neurocirurgia

## Introduction

Spinal intradural cystic lesions are uncommon, often asymptomatic and identified incidentally by imaging methods. They can either be located in the intradural as in extradural compartment or may also be transdural. Patients, when symptomatic, present medullary neurological symptoms with progressive evolution. Cysts associated with spinal wraps are the most common, most notably those related to arachnoid membrane. The complexity and the particularity of the surgical treatment planning are primarily associated with changes in CSF hydrodynamics in the spinal compartment, the intimate relationship with eloquent anatomical structures such as the spinal motor and sensory rootlets, as well as the challenge of rebuilding the CSF flow preserving spinal and vertebral structures. We describe a type of surgical approach option exemplified by description of three cases emphasizing our microsurgical planning. The aim of the present study was to demonstrate that microsurgical resection of the posterior portion of giant spinal arachnoid cyst can be effective in the treatment of patients.

## Materials and Methods

Three cases consecutively underwent spinal surgery with microsurgical technique and were admitted to our institution. They received treatment and follow-up, undergoing rehabilitation weekly and quarterly medical consultation.

The three patients were informed about the research and ethical aspects and agreed to participate with the exposure of their complete medical history. These three cases were used to illustrate the surgical treatment used by our team to discuss the best treatment option.

## Results

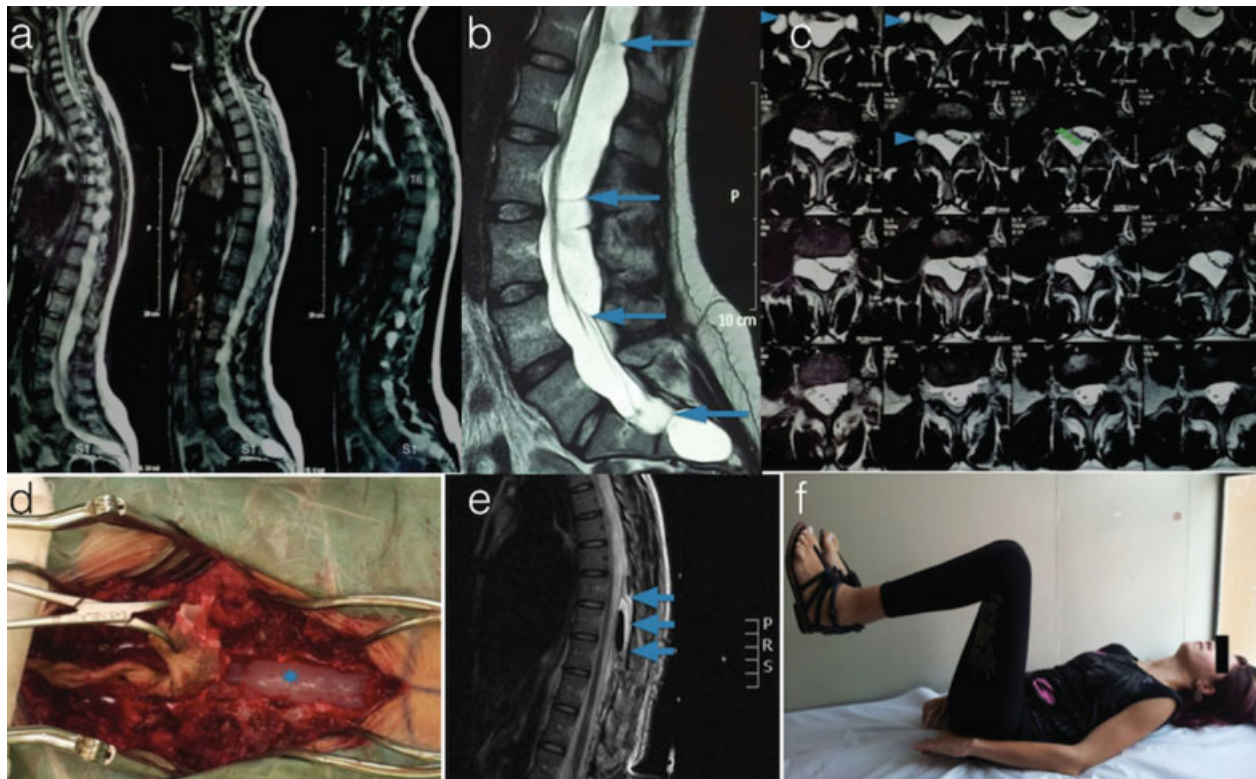
In this work, we discuss the options of neurosurgical treatment currently available for three patients operated, knowing that there is no consensus in the literature about the best treatment option to be adopted for the management of giant arachnoid cysts on spinal cord.

### Case 1

A 20-year-old woman presented complaining of back pain that had begun 10 months after admission; after 8 months she presented complaining of difficulty in walking and altered sensation in the lower limbs, characteristic of progressive evolution. After 9 months of onset, she could no longer walk.

Upon neurological examination, the patient was input bedridden with grade I/V muscle strength in all muscle groups of the lower limbs, with exalted reflexes and dense sensory level at T12.

We performed nuclear magnetic resonance, which showed lesions suggestive of extradural arachnoid cyst from T6 to S1, septate and posterior, associated with spinal cord compression and thinning of the adjacent vertebral bodies (▶ Fig. 1a, b, c).



**Fig. 1** (a) Sagittal sections of MRI T2 showing arachnoid cyst from T6 to S1. (b) Sagittal section of MRI T2 showing in detail the cyst septa by the blue arrows. (c) Axial sections of MRI T2 showing extramedullary arachnoid cyst compressing the spinal cord anteriorly and to the left as shown by the green arrows. Arachnoid cyst insinuating the intervertebral foramen as shown by the blue arrows. (d) Laminotomy showing septate cystic extradural lesion. Blue mark corresponds to the cyst. (e) Sagittal section of MRI T2 showing postoperative residual lesion on T6 and T7 (blue arrows) but with satisfactory spinal decompression. (f) Patient with improvement in strength from 1/5 to 4/5 at 15th postoperatively.

The patient underwent surgery the same week of admission and underwent extensive laminectomy from T8 to L3, with subsequent excision of the posterior cyst wall and fenestration of the remaining septa (►Fig. 1d). An inspection was performed on the dura for possible flaws that have externalized the cyst, but this was not found.

The patient continued deficits in the immediate postoperative period. We performed MRI that showed satisfactory spinal decompression, with small residual lesion at T6 and T7 (►Fig. 1e). The patient began physical therapy and had gradual improvement in strength. Fifteen days postoperatively the patient had grade 4 muscle strength in the lower limbs, walking without support, with improvement in back pain but complaining of numbness on the anterior surface of bilateral thigh (►Fig. 1f).

The patient is currently in the sixteenth month postoperatively with no recurrence of symptoms.

### Case 2

A 61-year-old woman presented complaining of back pain that started 5 months before admission. After three months, she presented dysphonia, which progressed after one month with urinary retention.

The patient underwent T4-T5 laminectomy with partial improvement of symptoms. At the end of the same year, she had worsened and returned to preoperative clinical status.

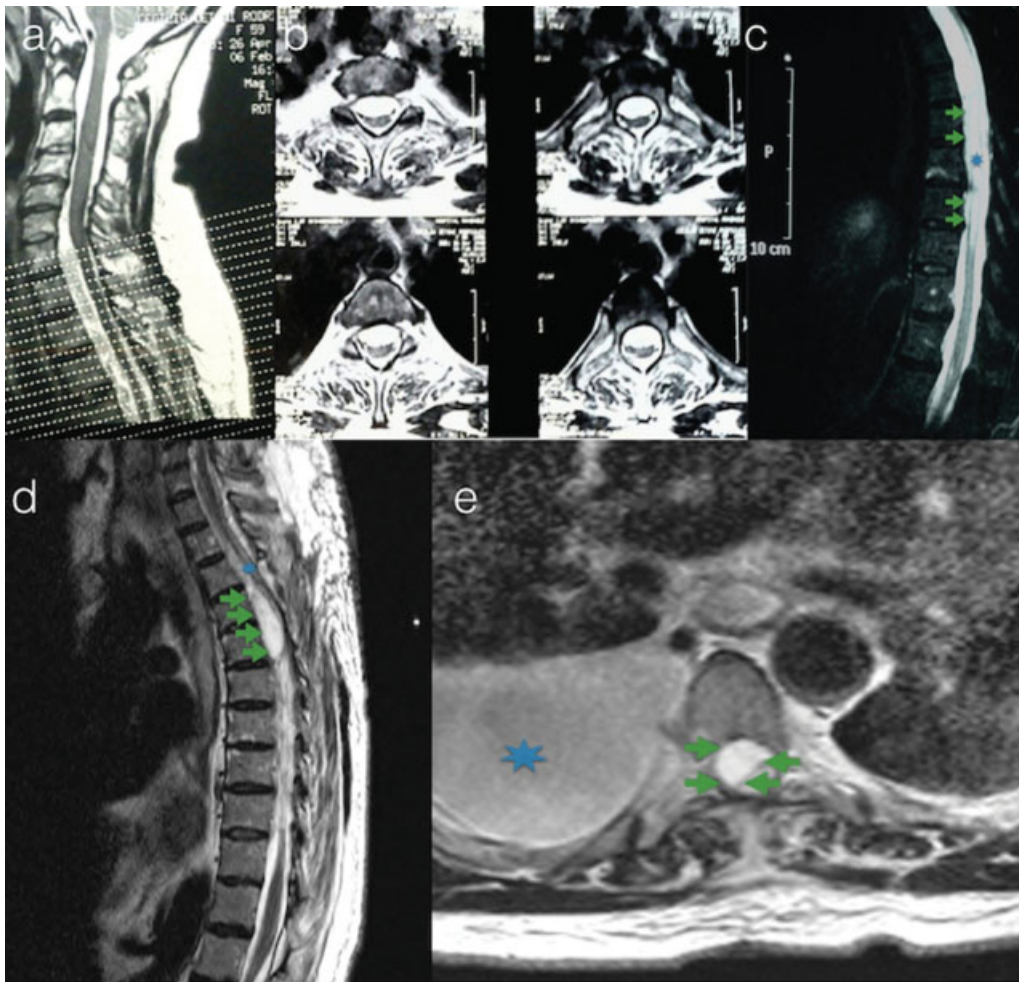
After one year, the patient was admitted at our emergency service on a wheelchair with paraparesis associated grade II/V muscle strength, dense sensory level at T8, and use of urinary catheter (►Fig. 2a, b, c).

She underwent surgical treatment with excision of the posterior cyst wall and a cyst-pleural shunt placement. The patient evolved postoperatively with dyspnea for 24 hours and worsening of strength in the lower limbs (grade I/V muscle strength), which reversed after 15 days, showing the end of this period grade III/V muscle strength in the lower limbs, but always keeping the dependence of urinary catheter (►Fig. 2d, e).

### Case 3

A 14-year-old girl felt difficulty walking. She was treated in another medical service with steroids administered orally, presenting temporary improvement of symptoms. After one month, she presented clinical worsening, when she came to our hospital. She had the following abnormalities at neurological examination: spastic paraparesis grade IV/V, with dense sensory level bilaterally T10 (►Fig. 3a).

The patient underwent three levels laminectomy with subsequent resection of the posterior cyst wall and fenestration of the remaining septa, evolving with improved strength, while maintaining spasticity without further worsening until the last follow-up (►Fig. 3b).



**Fig. 2** (a) Cervical pre-operative sagittal MRI of case 2. (b) Axial sections of preoperative thoracic spine MRI of Case 2. (c) Sagittal section of preoperative thoracic spine MRI of Case 2. It can be observed subdural arachnoid cyst (green arrows) and a significant edema (blue mark). (d) Postoperative sagittal MRI showing residual cyst (green arrows) and maintenance of medullary edema (blue mark). (e) Axial postoperative MRI showing right pleural effusion (blue mark), causing temporary dyspnea. Residual cyst located ventrally and to the right of the spinal cord (green arrows)

## Discussion

The arachnoid cysts are usually found in the brain, with an incidence on imaging diagnostics methods of 0.8–1.7%. Its intradural location is rarer, as is more common in the thoracic segment of the spinal cord.<sup>1</sup>

They are characterized by abnormal fluid accumulation similar of cerebrospinal fluid within the arachnoid, separating the layers of this membrane. Other associated findings are the thinning of bone and adjacent dura.<sup>1</sup>

Its origin may be associated with trauma or inflammation in the meninges, but with an idiopathic majority. It is suspected that these lesions that are actually idiopathic may be congenital lesions that occur in the 15<sup>th</sup> week of gestation, when the incomplete separation of the leptomeninges, arachnoid, and pia mater occur. In favor of this theory is the fact that the cysts are usually in tanks (most common in the sylvian fissure), where there is a greater distance between the pia mater and the arachnoid.<sup>1–4</sup>

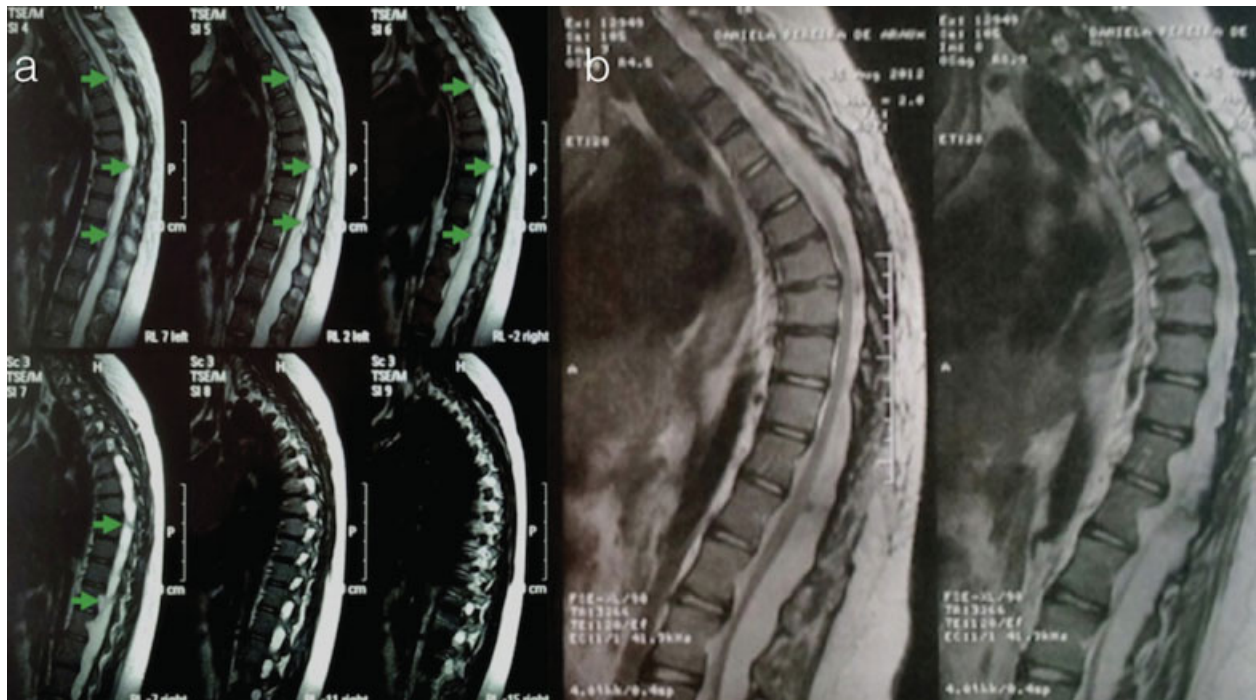
Some genetic disorders are associated with increased frequency of these injuries, such as Marfan Syndrome, Neurofibromatosis Type I, and Polycystic Kidney Disease, in that the latter has a very high incidence of arachnoid cysts of 8%.<sup>1</sup>

Clinical symptoms are often pain and neurological deficit. The spinal cord compression syndrome with signs of involvement of the pyramidal tracts demonstrating upper motor neuron syndrome and sensory deficits are habitual below the level of injury, which initially manifested as a complaint of difficulty gait and abnormal sphincter function.<sup>2,3</sup>

As a congenital lesion in most cases and having later and progressive symptoms, cyst expansion mechanisms are observed. The two main mechanisms proposed were: the secretion of serous fluid through the walls of the cyst, similar to the CSF, and a mechanism for “ball valve” through small fenestrations in the cyst wall, which operate with unidirectional flow of CSF into the cyst.

We confirmed the diagnosis with imaging in the main modalities: in the MRI, we observed a hypointense lesion on





**Fig. 3** (a) Preoperative T2 sagittal MRI showing extradural cyst extending from T5 to T12 (green arrows). (b) Postoperative T1 sagittal MRI showing the resection of the posterior wall of the cyst.

T1 and hyperintense on T2, similar to CSF; the myelotomography showed a mass lesion with delayed contrast enhancement. In both diagnostic exams, we observed a narrowing of the vertebral bodies.<sup>3</sup>

A particularity of intradural arachnoid cysts is the fact that, unlike the intracranial lesions, they may be located beyond the subdural space, on the epidural space. The latter are infrequent, but are remarkable for being localized lesions within the arachnoid, which is intradural, but outwards into the epidural space. Regarding size, there are reports of giant lesions extending between 4 and 12 vertebral bodies. There is no consensus on the definition of when a spinal arachnoid cyst can be considered gigantic; some authors suggest that a minimum of 6 vertebral bodies be established to define an injury as a giant.<sup>2</sup>

Patients undergoing surgical treatment showed clinical improvement, especially when treated early. The surgery to stop the compressive effect caused by these lesions on the spinal cord, resulting in rapid clinical improvement, was well exemplified in this small series of cases.

An important question is the choice of appropriate technical procedure to decompress the spinal cord without causing spinal instability and also to prevent recurrence of the lesions. The literature emphasizes that the complete excision of the cyst is the best surgical option.<sup>2,3</sup> But in cases with very extensive longitudinal lesions, there is greater risk of a vertebral deformity occurring. Other technical options are excision of the cyst only at the point of greatest compression,<sup>3</sup> cyst-pleural or cyst-peritoneal shunt, as well as resonance-guided puncture and endoscopy, proposed by the minority of experts.<sup>5-7</sup>

In the cases presented, the patients underwent spinal surgery with microsurgical technique for excision of the posterior

portion of the cysts. This choice was justified by the expectation of decreasing the risk of cerebrospinal fluid leak, since lesions were extradural. There was clinical improvement that was maintained for more than twelve months, emphasizing the efficacy of the adopted surgical intervention.

Although some authors state that complete excision of the cyst is the best surgical option, we believe that, on giant spinal arachnoid cysts, the excision of the posterior portion of the cysts decreases CSF leak. Furthermore, our series confirms that this surgical treatment presents good functional results when the surgery is done to stop the compressive effect caused by these lesions on the spinal cord, resulting in rapid clinical improvement.

## Conclusion

Although some authors state that complete resection of the cyst is the best surgical option, we believe that, specifically on giant spinal arachnoid cysts, the resection of the posterior portion of the cysts may decrease postoperative CSF leak incidence. Furthermore, our series suggests that the adopted surgical treatment may lead to better functional outcomes while this treatment is performed for spinal decompression using a less invasive technique and, thus, leading to an earlier clinical improvement.

## References

- 1 Wetjen NM, Walker ML. Arachnoid cysts. In: Winn HR, editor. Youmans Neurological Surgery. 6th ed. Philadelphia: WB Saunders; 2011:1911-17

- 2 Furtado SV, Thakar S, Murthy GK, Dadlani R, Hegde AS. Management of complex giant spinal arachnoid cysts presenting with myelopathy. *J Neurosurg Spine* 2011;15(1):107–112
- 3 Petridis AK, Doukas A, Barth H, Mehdorn HM. Spinal cord compression caused by idiopathic intradural arachnoid cysts of the spine: review of the literature and illustrated case. *Eur Spine J* 2010;19(Suppl 2):S124–S129
- 4 Joaquim AF, da Silva EG, dos Santos MJ, Honorato DC. Giant cervico-thoracic extradural arachnoid cyst. *Arq Neuropsiquiatr* 2009;67(1):117–118
- 5 Takahashi S, Morikawa S, Egawa M, Saruhashi Y, Matsusue Y. Magnetic resonance imaging-guided percutaneous fenestration of a cervical intradural cyst. Case report. *J Neurosurg* 2003;99(3, Suppl):313–315
- 6 Endo T, Takahashi T, Jokura H, Tominaga T. Surgical treatment of spinal intradural arachnoid cysts using endoscopy. *J Neurosurg Spine* 2010;12(6):641–646
- 7 Kahraman S, Anik I, Gocmen S, Sirin S. Extradural giant multiloculated arachnoid cyst causing spinal cord compression in a child. *J Spinal Cord Med* 2008;31(3):306–308