

# Posttraumatic Contusion: Clinical and Radiologic Factors for Progression in Early Postinjury Period

Mukesh Sharma<sup>1</sup> R. S. Mittal<sup>1</sup> Achal Sharma<sup>1</sup> Ashok Gandhi<sup>1</sup>

<sup>1</sup>Department of Neurosurgery, SMS Medical College, Jaipur, Rajasthan, India

Address for correspondence Mukesh Sharma, MS, Department of Neurosurgery, SMS Medical College, Jaipur, Rajasthan, India (e-mail: dr\_mukki@yahoo.co.in).

Indian J Neurotrauma 2016;13:1–6.

## Abstract

**Objective** To identify clinical and radiological factors to predict progression of contusion and its impact on clinical deterioration of neurological status, which will ultimately help deciding surgical intervention in initially conservatively managed patients.

**Methods** This is a prospective, observational study containing a total of 110 patients who had contusions after traumatic brain injury with size of  $\geq 2$  mL by computed tomographic (CT) scan, managed conservatively in initial period, and had at least two subsequent CT scans within 72 hours after injury. Significant radiological progression was defined as  $>30\%$  increase in volume from baseline in CT scan.

**Results** The progression of contusion was significantly associated with age, sex, contusion volume in initial CT, effacement of cistern, subdural hematoma (SDH), subarachnoid hemorrhage (SAH), and coagulopathy. SDH and SAH ( $p < 0.05$ ) were found to be as independent risk factors for contusion progression. The need for surgery after initial conservative management was required in 11.81% cases, and the deterioration of Glasgow coma scale (GCS) volume in the second CT were found to be significant independent predictors for the surgical intervention ( $p < 0.05$ ).

**Conclusions** About half of the patients presenting with TBI managed conservatively in initial period show significant progression of contusion mostly within 24 hours after injury. Patients with SAH, SDH and deranged coagulation profile are particularly at high risk for progression of contusion.

## Keywords

- ▶ TBI
- ▶ contusion progression
- ▶ predictors

## Introduction

Traumatic brain injury (TBI) is one of the most common causes of mortality and morbidity, leading to lifelong physical, cognitive, behavioral, and emotional impairments.<sup>1,2</sup> TBI results in sequence of events leading to secondary brain damage in which hemorrhagic expansion is certainly one of the most important and devastating.<sup>3</sup>

When head trauma results in a contusion, the hemorrhagic lesion often expands or a new hemorrhagic lesion may develop remotely from the original contusion during the early hours

after injury.<sup>4</sup> Contusions can appear in computed tomographic (CT) scan as solid hematoma or a classic salt-and-pepper appearance, and these lesions contribute significantly in patients of closed-head injury.<sup>5</sup> Progression of these lesions is highly variable and has unpredictable course with few lesions remaining unchanged for several days and some enlarging rapidly causing catastrophic outcome.<sup>6,7</sup>

Previous studies showed that approximately half of the patients with contusions demonstrated hemorrhagic progression on serial CT scans, and generally these progressions occurred in first 12 hours and some can be

received  
August 3, 2015  
accepted  
February 5, 2016  
published online  
April 29, 2016

© 2016 Neurotrauma Society of India

DOI <http://dx.doi.org/10.1055/s-0036-1580717>.  
ISSN 0973-0508.

delayed up to 3 to 4 days.<sup>8,9</sup> However, previous studies showing hemorrhagic progression of contusions were mostly retrospective. There is lack of data in Indian population about this dreaded complication.

The aim of our present study was to identify clinical and radiologic factors to predict progression of contusions and its impact on clinical deterioration of neurologic status, which will ultimately help in deciding surgical intervention in initially conservatively managed patients.

## Methods

This prospective, observational study was conducted at our medical college hospital in one of its neurosurgery units. The patients were enrolled during the period from April 2014 to March 2015. After the informed consent was obtained, all the patients who had contusions after TBI with size of  $\geq 2$  mL by CT scan, managed conservatively in initial period, and had at least two subsequent CT scans within 72 hours after injury were included. Of the patients who were operated after first CT scan, those who were admitted but who did not undergo follow-up CT scans were excluded.

A detailed patient history related to mode of injury, date and time of injury, age, sex, etc. was recorded. Glasgow coma scale (GCS) was obtained after resuscitation at the time of admission. Laboratory data regarding prothrombin time (PT) with international normalized ratio (INR) and platelet counts were collected. Normal coagulation values as per our laboratory standard were  $\leq 13.2$  seconds for PT,  $< 1.2$  for INR, and  $\geq 100,000/\mu\text{L}$  for platelet count.

The initial CT scan was performed immediately upon presentation, and subsequent CT scans were done at 24 hours and 72 hours after injury. Additional CT scans were done as advised by senior consultant as and when required.

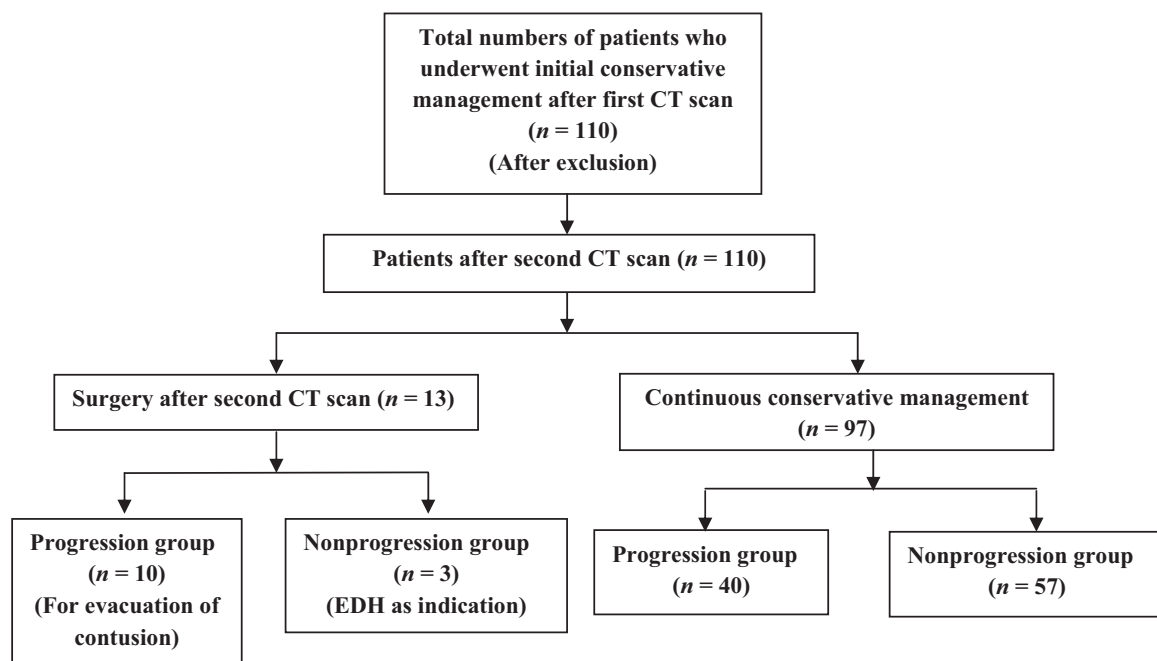
Types of hematomas coexisting with contusion were recorded as EDH (epidural hematoma), SDH (subdural hematoma), SAH (subarachnoid hemorrhage), and IVH (intraventricular hemorrhage). Contusions were classified as lobar (frontal, temporal, parietal, occipital) and deep (brainstem, basal ganglia). The initial contusion volume was evaluated by using the ABC/2 method.<sup>9</sup> Progression in contusion was defined as  $\geq 30\%$  increase in contusion volume from the baseline (progression group). This criterion was used because similar cutoff was used in previous studies.<sup>7</sup>

## Statistical Analysis

Statistical analyses were done using computer software (SPSS version 20 and primer, IBM, Armonk, New York). The qualitative data were expressed in proportion and percentages, and the quantitative data expressed as mean and standard deviations. The difference in proportion was analyzed by using chi-square test and the differences in means were analyzed by using student *t*-test. Multivariate logistic regression was used to find out the predictors of progression of contusion. Significance levels for tests were determined as 95% ( $p < 0.05$ ).

## Results

Total 110 patients were enrolled (**► Fig. 1**). Mean age of study population was  $37.55 \pm 14.83$  and 76.3% were males. Mode of injury was road traffic accident (RTA) in 83.6% cases, fall from height (FFH) in 14.55% cases, and assault in 1.8% cases. Mean GCS score at the time of admission was  $12.77 \pm 3.01$  (**► Table 1**). Out of total four patients who died in this study, three were from nonprogression group.



**Fig. 1** Flowchart regarding patients included in this study. CT, computed tomography; EDH, epidural hematoma.

**Table 1** Clinical-demographic profile of the study population

	No.	%
Total patients	110	
Male	84	76.36
Female	26	23.64
Mean age (y): mean $\pm$ SD (range)	37.55 $\pm$ 14.83 (2–75)	
Mode of injury		
RTA	92	83.64
FFH	16	14.55
Assault	2	1.82
Initial GCS score (mean $\pm$ SD)	12.77 $\pm$ 3.01	
GCS grade		
3–8	10	9.09
9–12	29	26.36
13–15	71	64.55
Deterioration in GCS	18	16.36
INR (mean $\pm$ SD)	1.25 $\pm$ 0.34	
Abnormal	30	27.27
Normal	80	72.73
Radiographic findings in initial CT scan		
Effacement of cistern	35	31.82
SAH	35	31.82
SDH	29	26
EDH	7	6.36
IVH	2	1.82
Contusion size (mean $\pm$ SD)	8.99 $\pm$ 6.98	
2–10	73	66.36
11–25	30	27.27
26–50	7	6.36

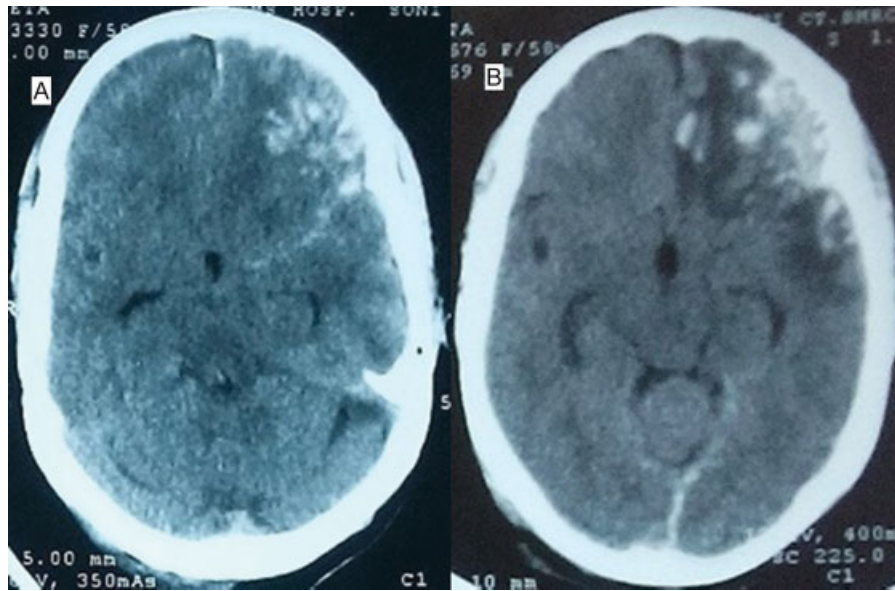
Abbreviations: CT, computed tomography; EDH, epidural hematoma; FFH, fall from height; GCS, Glasgow coma scale; IVH, intraventricular hemorrhage; RTA, road traffic accident; SAH, subarachnoid hemorrhage; SD, standard deviation; SDH, subdural hematoma.

Total 147 contusions were found in 110 patients being 96.6% lobar and 3.40% deep. The most common location was frontal lobe (43.54%), followed by temporal (36.73%), parietal (14.29%), occipital (2%), brainstem (2%), and basal ganglia (1.36%). The range of contusion volume found to be 2 to 10 mL in 66.36%, 11 to 25 mL in 27.27%, and 26 to 50 mL in 6.36% patients. Among the associated CT findings, SAH was found to be most common (31.82%), followed by SDH (26%), EDH (6.36%), and IVH (1.82%). Abnormal INR ( $>$  1.2) was found in 27.27% cases.

The significant radiologic increase in contusion size was found in 45.45% cases. ( $\rightarrow$  **Figs. 2 and 3**). The mean contusion volume found in initial, second, and third CT scans was, respectively, 10.43  $\pm$  17 mL, 20.78  $\pm$  9.78 mL, and 12  $\pm$  7.77 mL in progression group, which was significantly different as compared with initial CT ( $p <$  0.001). The mean contusion volume in initial CT was 7.8  $\pm$  6.81 mL and this increased to 8.51  $\pm$  7.59 mL in second CT in nonprogression group. There

was 10.35  $\pm$  9.58 mL increase in volume from baseline to second CT scan at 24 hours in progression group while volume change was found to be only 0.714  $\pm$  1.99 mL in nonprogression group. In intergroup analysis, significantly higher initial mean contusion volume was observed in progression group as compared with nonprogression group ( $p <$  0.001S) ( $\rightarrow$  **Table 2**).

On univariate analysis for progression of contusion, significant association was observed with age, sex, contusion volume in initial CT, effacement of cistern, SDH, SAH, and abnormal coagulation profile, but the progression was not significantly associated with initial GCS score, EDH, and IVH ( $\rightarrow$  **Table 3**). On the multivariate logistic regression analysis coagulopathy, SDH and SAH ( $p <$  0.05) made a significant contribution to prediction of contusion progression. One unit change in the significant predictors, the log odds of increase in progression was found to be by 7.03 times (for INR), 2.83 times (for SDH), and 3.44 times (for SAH) ( $\rightarrow$  **Table 4**).



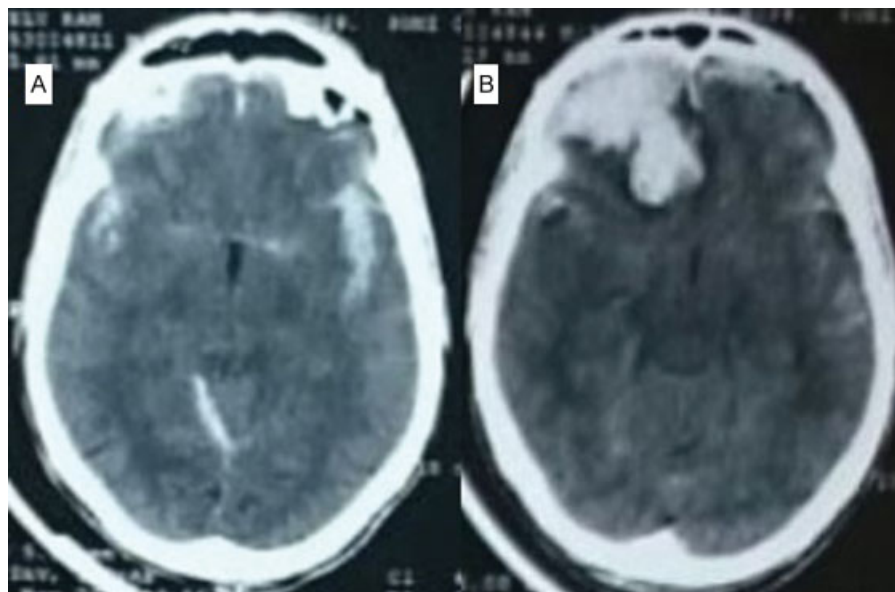
**Fig. 2** Computed tomographic (CT) scans showing contusion progression in a 58-year-old woman after road traffic accident. Patient required surgical intervention. (A) Initial CT scan. (B) CT scan after 24 hours.

The conservative management failed in 13 patients and required surgical intervention, of whom 10 were from progression group and 3 from nonprogression group. On univariate analysis for operative versus conservative management in contusion progression group, the surgical intervention had significant association with contusion volume in second CT scan, change in contusion volume (from initial to second CT), and SDH ( $p < 0.05$ ), but it was not associated with age, sex, initial GCS score, contusion volume in initial CT scan, coagulopathy, effacement of cistern, SAH, and EDH. On the multivariate logistic regression analysis, deterioration of GCS (odds ratio [OR] = 48.25) and volume in second CT (OR = 1.24) were significant independent predictors for the surgical intervention ( $p < 0.05$ ) (→Table 5).

## Discussion

TBI is one of the most common causes of death in patients with trauma. Studies of progression of contusion are lacking in Indian population. As per our study, in approximately 45% patients managed conservatively contusion volume would be later progressed in subsequent CT. Similar rate of progression was found in other studies. Narayan et al reported 51%, Oertel et al 51%, whereas Alahmadi et al reported 45% incidence of progression of contusion volume.<sup>4,7,10</sup> Among the patients in whom contusions were progressed, approximately 90% showed contusion progression in first 24 hours.

We found that female sex and elderly age were significantly associated with progression of contusion as



**Fig. 3** Computed tomographic (CT) scans showing example of progression of contusion associated with subarachnoid hemorrhage in a 45-year-old man after road traffic accident. Patient required surgical intervention. (A) Initial CT scan. (B) CT scan after 24 hours.

**Table 2** Traumatic contusion volume progression

	Initial CT	2nd CT	3rd CT
Progression group (> 30% progression)			
<i>n</i>	50	50	40
Mean ± SD (mL)	10.43 ± 17.080	20.78 ± 9.78	11.3 ± 12.779
Contusion volume increase from initial CT		10.35 ± 9.58 ( <i>p</i> < 0.001)	6.54 ± 4.65 ( <i>p</i> < 0.001)
Nonprogression group			
<i>n</i>	60	60	57
Mean ± SD (mL)	7.80 ± 6.81	8.51 ± 7.59	7.25 ± 5.29
Contusion volume increase from initial CT		0.714 ± 1.99	0.356 ± 0.914
Intergroup comparison <i>p</i> value		< 0.001	0.005

Abbreviations: CT, computed tomography; SD, standard deviation.

**Table 3** Univariate analysis of factors for contusion progression versus nonprogression

	<i>p</i> Value
Age	0.001
Sex	0.035
GCS score	0.918
Contusion volume in initial CT	0.049
Effacement of cistern	< 0.001
SDH	0.003
SAH	0.007
Coagulopathy	0.003
EDH	0.3
IVH	0.58

Abbreviations: CT, computed tomography; EDH, epidural hematoma; GCS, Glasgow coma scale; IVH, intraventricular hemorrhage; SAH, subarachnoid hemorrhage; SDH, subdural hematoma.

**Table 4** Independent risk factors for progression of contusion (multivariate analysis)

Variables	<i>p</i> Value	Odds ratio	95% confidence interval	
			Minimum	Maximum
GCS scale	0.13	1.14	0.96	1.36
Coagulopathy <sup>a</sup>	0.02	7.03	1.43	34.7
Contusion volume in initial CT scan	0.95	1	0.93	1.07
SDH	0.04	2.83	1.05	7.63
SAH	0.01	3.44	1.3	9.14

Abbreviations: CT, computed tomography; GCS, Glasgow coma scale; SAH, subarachnoid hemorrhage; SDH, subdural hematoma.

<sup>a</sup>Abnormal INR.

also reported in previous studies.<sup>7</sup> Coagulopathy, SDH, SAH, and initial contusion volume were significantly associated with progression of contusion. On multivariate analysis only SDH, SAH, and coagulopathy were found to be independent predictors of progression of contusion, and of them, coagulopathy was found to be the strongest predictor. One

unit change in INR, the log odds of increase progression was found to be by 7.03 times. Similar finding is also reported by Oertel et al, Stein et al, and Yadav et al.<sup>7,11,12</sup> SAH was also strongly and independently predicted radiologic progression but less than coagulopathy. This was found in other studies too.<sup>13,14</sup> SDH was also reported as significant predictor of



**Table 5** Evolving lesions in traumatic SAH: Prospective study of 110 patients with emphasis on the role of ICP monitoring

Variables	p Value	Odds ratio	95% confidence interval	
			Minimum	Maximum
Contusion volume in 2nd CT	0.041	1.242	1.009	1.530
Change in contusion volume from initial CT to 2nd CT	0.608	0.998	0.990	1.006
SDH	0.090	16.457	0.644	420.792
Deterioration of GCS	0.015	48.254	2.132	1,092.373
Effacement of cistern	0.117	0.008	0.000	3.392
SAH	0.746	0.659	0.053	8.208
Coagulopathy <sup>a</sup>	0.809	0.651	0.020	21.353

Abbreviations: CT, computed tomography; GCS, Glasgow coma scale; ICP, intracranial pressure; SAH, subarachnoid hemorrhage; SDH, subdural hematoma.  
<sup>a</sup>Abnormal INR.

progression and we found similar finding in our study,<sup>8</sup> but in some cases SDH might be due to secondary to burst lobe from underlying large expanding contusion.

A large initial contusion size has more chances of progression than the smaller contusion, as shown in our study. Other previous literature also reveals the same factor.<sup>4,8,14</sup>

Failure of initial conservative management leading to surgical intervention occurred in 11.81% cases, and deterioration of GCS and contusion size on CT at 24 hours after injury was found to be independent risk factors for this, which was also found in other studies.<sup>5,8</sup> All patients who underwent surgical intervention in nonprogression group required surgery for evacuation of EDH whereas those from progressive contusion group required evacuation of contusion due to expanding contusion. Four patients died in our study, and of them three were from nonprogression group. Deep location of contusion (basal ganglia and brain stem) may have caused higher mortality in this group.

## Conclusion

About half of the patients presenting with TBI managed conservatively showed significant progressions of contusion volume, and most of these progressions occurred within 24 hours after injury showing the significance of repeat CT scan particularly within 24 hours. SAH, SDH, and deranged coagulation profile were found to be independent predictors of progression of contusion, and of them, coagulopathy was found to be the strongest predictor. The monitoring of these parameters will help in early detection of progression of contusion and its consequences, and can guide in early intervention. The worsening of neurologic status was significantly associated with expanding hematoma that also implies the importance of repeat CT scan within 24 hours after injury.

## References

- Langlois JA, Rutland-Brown W, Wald MM. The epidemiology and impact of traumatic brain injury: a brief overview. *J Head Trauma Rehabil* 2006;21(5):375–378
- Selassie AW, Zaloshnja E, Langlois JA, Miller T, Jones P, Steiner C. Incidence of long-term disability following traumatic brain injury hospitalization, United States, 2003. *J Head Trauma Rehabil* 2008;23(2):123–131
- Clifton GL, Grossman RG, Makela ME, Miner ME, Handel S, Sadhu V. Neurological course and correlated computerized tomography findings after severe closed head injury. *J Neurosurg* 1980;52(5):611–624
- Alahmadi H, Vachhrajani S, Cusimano MD. The natural history of brain contusion: an analysis of radiological and clinical progression. *J Neurosurg* 2010;112(5):1139–1145
- Bullock R, Golek J, Blake G. Traumatic intracerebral hematoma— which patients should undergo surgical evacuation? CT scan features and ICP monitoring as a basis for decision making. *Surg Neurol* 1989;32(3):181–187
- Naff NJ, Williams MA, Rigamonti D, Keyl PM, Hanley DF. Blood clot resolution in human cerebrospinal fluid: evidence of first-order kinetics. *Neurosurgery* 2001;49(3):614–619, discussion 619–621
- Oertel M, Kelly DF, McArthur D, et al. Progressive hemorrhage after head trauma: predictors and consequences of the evolving injury. *J Neurosurg* 2002;96(1):109–116
- Chang EF, Meeker M, Holland MC. Acute traumatic intraparenchymal hemorrhage: risk factors for progression in the early post-injury period. *Neurosurgery* 2006;58(4):647–656, discussion 647–656
- Kothari RU, Brott T, Broderick JP, et al. The ABCs of measuring intracerebral hemorrhage volumes. *Stroke* 1996;27(8):1304–1305
- Narayan RK, Maas AI, Servadei F, Skolnick BE, Tillinger MN, Marshall LF; Traumatic Intracerebral Hemorrhage Study Group. Progression of traumatic intracerebral hemorrhage: a prospective observational study. *J Neurotrauma* 2008;25(6):629–639
- Stein SC, Spettell C, Young G, Ross SE. Delayed and progressive brain injury in closed-head trauma: radiological demonstration. *Neurosurgery* 1993;32(1):25–30, discussion 30–31
- Yadav R, Basoor A, Jain G, Nelson A. Expanding traumatic intracerebral contusion/hematoma. *Neurol India* 2006;54(4):377–381
- Servadei F, Antonelli V, Giuliani G, Fainardi E, Chierigato A, Targa L. Evolving lesions in traumatic subarachnoid hemorrhage: prospective study of 110 patients with emphasis on the role of ICP monitoring. *Acta Neurochir Suppl (Wien)* 2002;81:81–82
- Chierigato A, Fainardi E, Morselli-Labate AM, et al. Factors associated with neurological outcome and lesion progression in traumatic subarachnoid hemorrhage patients. *Neurosurgery* 2005;56(4):671–680, discussion 671–680