

Tumour-adapted Reduction Mammoplasty – a New (Old) Breast Conserving Strategy: Review

Die tumoradaptierte Reduktion – eine neue (alte) Operationsmethode zur brusterhaltenden Therapie: Übersichtsarbeit

Authors

M. Eichbaum¹, A. Dietrich¹, J. Reinhard¹, R. Steinwasser¹, C. Eichbaum²

Affiliations

¹ Frauenklinik St. Marienkrankenhaus Frankfurt am Main, Frankfurt am Main
² Frauenklinik Klinikum Darmstadt, Darmstadt

Key words

- tumour-adapted reduction
- breast carcinoma
- breast conserving surgery
- Dufourmentel-Mouly mammoplasty
- modified B technique

Schlüsselwörter

- tumoradaptierte Reduktion
- Mammakarzinom
- brusterhaltende Operation
- Dufourmentel-Mouly-Mammoplastik
- modifizierte B-Plastik



Deutsche Version unter:
[www.thieme-connect.de/
ejournals/gebfra](http://www.thieme-connect.de/ejournals/gebfra)

received 9.11.2014
revised 23.9.2015
accepted 18.10.2015

Bibliography

DOI <http://dx.doi.org/10.1055/s-0035-1568170>
Geburtsh Frauenheilk 2016; 76:
31–36 © Georg Thieme
Verlag KG Stuttgart · New York ·
ISSN 0016-5751

Correspondence

Prof. Dr. med.
Michael H. R. Eichbaum,
MHBA, Chefarzt der Frauenklinik,
Leiter des Brustzentrums
St. Marienkrankenhaus
Richard-Wagner-Straße 14
60437 Frankfurt am Main
m.eichbaum@
katharina-kasper.de

Abstract

Today over 70% of patients treated for primary breast carcinoma in certified breast centres are managed with breast conserving surgery. The classical semicircular incision directly above the tumour, though in many cases easily carried out and associated with good cosmetic results, does have limitations. Unsatisfactory aesthetic results often occur when tumour location is unfavourable or when there is unfavourable tumour size relative to breast size. Distortion of the nipple, changes to breast shape and retraction of skin overlying surgical defects can occur. Tumour-adapted reduction mammoplasty/mastopexy or the “modified B technique” offer excellent chances of combining the oncological demands of breast surgery with satisfactory symmetrical cosmetic results. This article reviews a traditional, old operative technique that has been re-embraced in various new forms.

Zusammenfassung

An einem zertifizierten Brustzentrum können heute mehr als 70% der Patientinnen mit einem primären Mammakarzinom brusterhaltend operiert werden. Der in vielen Fällen gut durchführbare und von guten kosmetischen Ergebnissen begleitete, klassische Semizirkulärschnitt oberhalb des Tumorsitzes hat allerdings auch seine Limitationen. Bei ungünstigem Tumorsitz oder ungünstiger Relation zwischen Tumor- und Brustgröße kommt es häufig zu einem unbefriedigendem ästhetischen Ergebnis mit Verziehung der Mamille, Veränderung der Brustform oder Einziehung der Brustkontur durch den entstandenen Defekt. Um dies erfolgreich zu vermeiden, bietet die tumoradaptierte Reduktion bzw. Mastopexie oder auch modifizierte B-Plastik exzellente Möglichkeiten, die notwendigen onkologischen Anforderungen an die Brustkrebsoperation mit guten, seitengleichen ästhetischen Ergebnissen zu verbinden. Mit dieser Übersichtsarbeit soll diese eigentlich traditionelle, ältere Operationsmethode, die in verschiedenen neuen Variationen wieder aufgegriffen wurde, vorgestellt werden.

Introduction

In Germany 72 000 women are newly diagnosed with breast carcinoma annually [1]. Most often tumour surgery forms part of primary treatment, either immediately or following neoadjuvant chemotherapy.

For decades radical or modified radical mastectomy was considered to be the only surgical option, however a paradigm shift has taken place starting in the 1960s with the introduction of postoperative radiation based on the work of B. Fisher, and culminating in breast conserving surgery [2,3]. Veronesi and his Milan working

group subsequently expanded on these seminal studies [4,5].

Today breast conserving surgery is achievable in over 70% of cases treated in certified breast centres [6]. Breast conserving operative techniques (BCO) must provide oncological safety/certainty, i.e. definite complete tumour excision, as well as aesthetically pleasing results and postoperative patient satisfaction [7,8].

The classical, original operation involves a semicircular incision directly over the tumour site. The pathology is removed via a segmental resection of breast tissue including the overlying skin (● Fig. 1) as well as a portion pectoralis major fascia at the segment base. In many cases this is still a

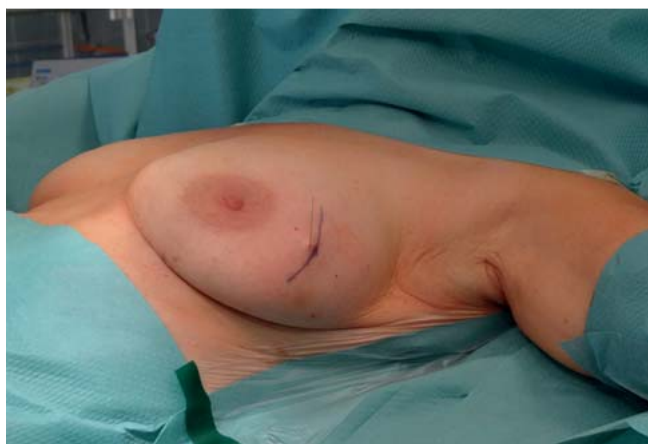

Fig. 1 Planning a breast conserving operation using the classical semi-circular incision.

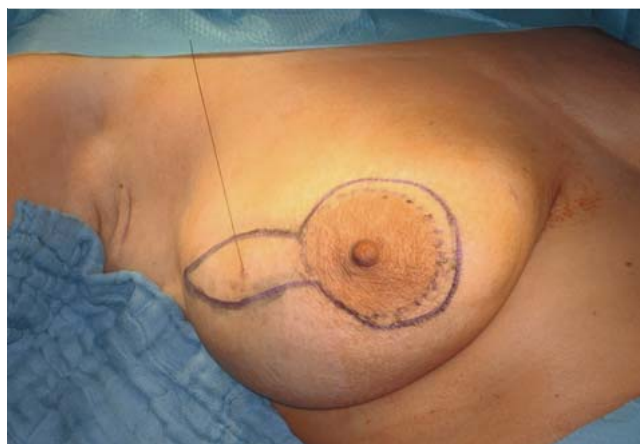

Fig. 2 Preoperative skin incision pattern aided by stereotactic clip markers.

Table 1 Comparison of the distinctive characteristics of tumour-adapted reduction mammoplasty, segmental resection and reduction mammoplasty after Ribeiro-Backer.

	Tumour-adapted reduction mammoplasty	Segmental resection	Plastic surgical breast reduction after Ribeiro-Backer
Breast shape	Identical to opposite breast	Usually the same as opposite side	Form always upright and compact; in the presence of ptosis not a good option without adaption of opposite breast
Scar	Moderately large	Small	Large and wide, wound healing more problematic
Nipple	Good position, symmetrical with opposite side	Possible divergence/offset	Good, symmetrical position
Breast contour	Smooth	Occasional skin retraction, "dent"	Smooth
Post-radiation	No skin retraction	Scar often retracted	No skin retraction

suitable, effective and easily performed method. It provides a good excision result and satisfactory aesthetic outcomes particularly for tumours in the upper outer quadrant where 55% of all breast carcinomas occur. Its utility is limited however with smaller breasts or unfavourable breast-to-tumour size since extensive mammary gland mobilisation is necessary to fill the tumour defect via intramammary, local glandular advancement flaps. Upward lateral nipple divergence also sometimes occurs. For tumours in the other three quadrants and those located near the nipple achieving an adequate aesthetic result using breast conserving surgery is far more difficult, and simple tumour excision often produces unsatisfactory unattractive skin depression and retractions.

Dufourmental and Mouly therefore developed the tumour-adapted reduction mammoplasty [9–11]. Initially termed "méthode oblique", the procedure involved an oblique lateral approach with excision of mammary gland tissue and medial pedicle transposition of the nipple-areola complex (NAC) with limited skin undermining. This technique was widely used in the 1960s especially in French speaking countries.

Tumour-adapted plastic surgical breast reduction, based on the reduction mammoplasty technique first described by the Brazilians Ribeiro and Backer [12], is considered a completely separate entity where the focus is plastic surgical breast reduction with tumour excision being incorporated into the operative concept. Various authors have developed Dufourmental-Mouly's concept of tumour-adapted reduction mammoplasty further and it has

been described in a number of variations as the "modified B technique" [13].

• **Table 1** compares important aspects of the various methods.

Various Skin Incision Patterns

▼ A first crucial step in the operative process is preoperative planning, which includes drawing the skin incision pattern onto the patient. This should ideally be performed the day before surgery with the patient in the supine position and the arm abducted to 90°. Here ultrasound can provide helpful information on exact tumour location. If stereotactic tumour marking is necessary (usually performed immediately before surgery) the incision pattern should be drawn taking marker clips and respective mammograms into account (• **Fig. 2**). Once drawn, the pattern should be checked with the patient in the upright position (sitting or standing).

When the incision pattern is drawn the areola edges as well as an island of skin covering the segment of breast tissue to be removed are marked e.g. with a dotted line. The size of necessary skin island varies and must be adapted to the size of underlying tumour and relative size of the involved breast on an individual basis. Depending on tumour location and amount of skin removal required, the geometric course of the usually tapered skin segment can vary from a straight, radiating form to a more undulating incision e.g. to avoid the cleavage (• **Fig. 3 a to d**).

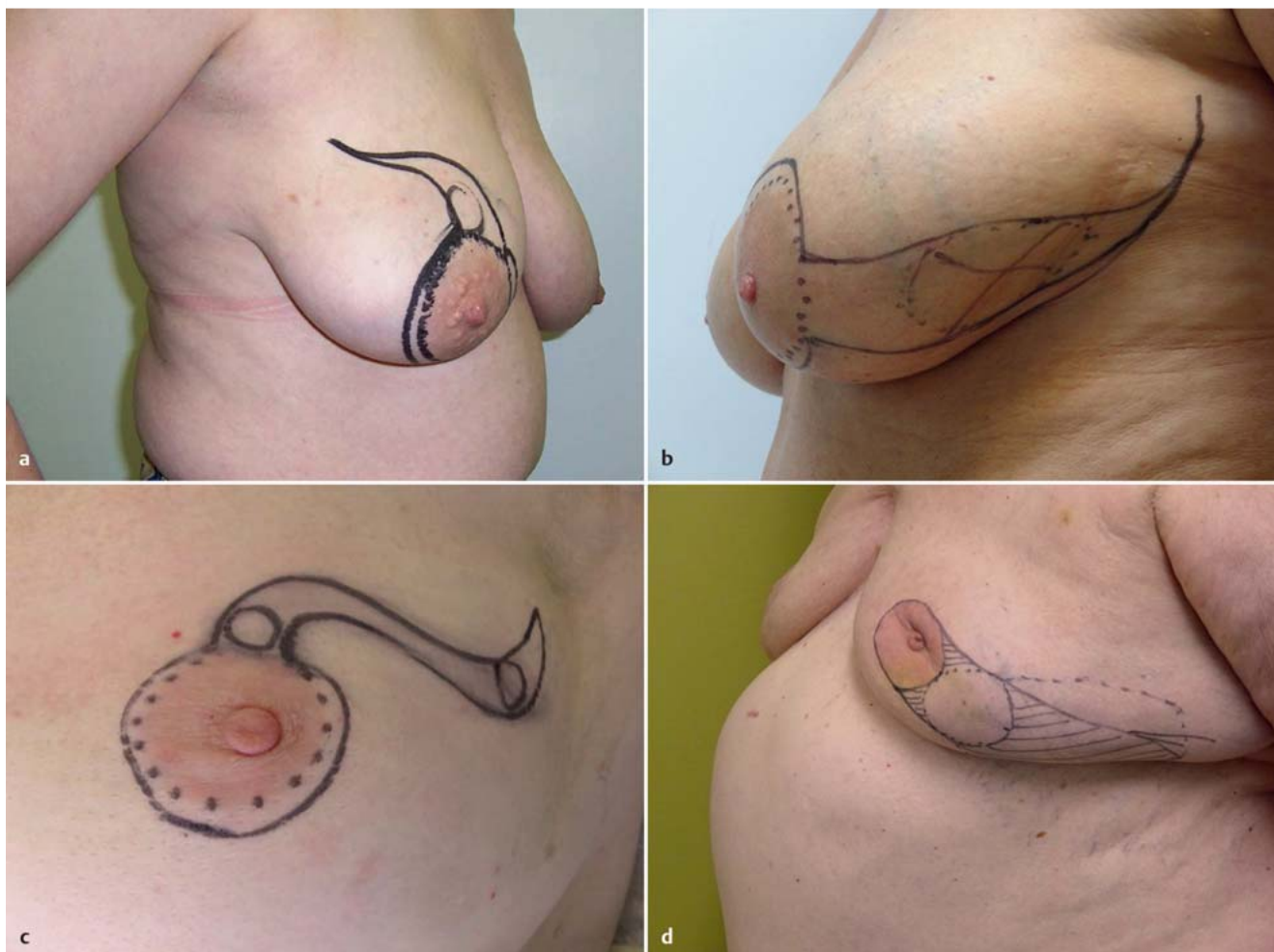


Fig. 3 a to d Various skin incisions dependant on tumour location. **a** Tumour upper/medial segment. **b** Large tumour bed following neoadjuvant chemotherapy. **c** Incision for multifocal tumour. **d** An example of a planned central segment with defined skin island as neo-nipple.

A half-moon shaped eccentric area of skin is defined and marked from the allocated skin island over the breast segment peripherally around the areola. Proper measurement of the various distances is crucial: the area of skin diametrically opposite the segment should be approximately half the width of the skin to be removed from above the breast segment.

The skin incision pattern can thus vary greatly depending on the individual circumstances (e.g. planned central segment including a pivotal skin island as neo-nipple (► Fig. 3 d)). The highest priority of any surgical BCO technique is, of course, complete tumour excision. Ensuring and preserving breast symmetry (breast shape) is a further goal of the technique described here and for this purpose the inframammary fold should also be drawn in as an orientation aid.

Operative Steps

The sterile preparation and draping of the whole upper body with both breasts exposed is important for ensuring symmetry (breast form, nipple projection). The patient should be positioned with the upper body slightly raised and, depending on the circumstances, should be sat up repeatedly during the operation in order to evaluate the breast's natural fall in the upright position.

In this way skin retractions can be recognised and corrected as required.

After scalpel incision along the preoperatively drawn skin markings the next step is linear deepithelialisation and resection of the skin around the areola (► Fig. 4 a). To ensure exact preservation of the areola contour a suitably chosen stencil/mould can be used to assist the incision around the nipple. The dermis must always be left intact to avoid neural desensitisation of the nipple and most importantly to ensure intact vascularisation of the NAC. At this point the designated breast segment can usually be electrosurgically resected. Assessment of the extent of resection is then performed with a palpating finger or a sterile draped, intraoperative ultrasound probe [14]. The resection includes the skin island designated preoperatively and all tissue in the segment down to the level of the pectoral fascia, some of which is also excised (► Fig. 4 b). The breast segment is then measured, weighed and topographically marked e.g. with ink of various colours. After haemostasis and drain insertion the breast gland is mobilised to various extents depending on the size of operative defect. The breast tissue is then approximated usually in two layers using vicryl single sutures in strictly upright orientation. A check for skin retractions is then carried out with the patient in the upright position. If present these can then easily be corrected via mobilisation. It may be necessary to prepare and ma-

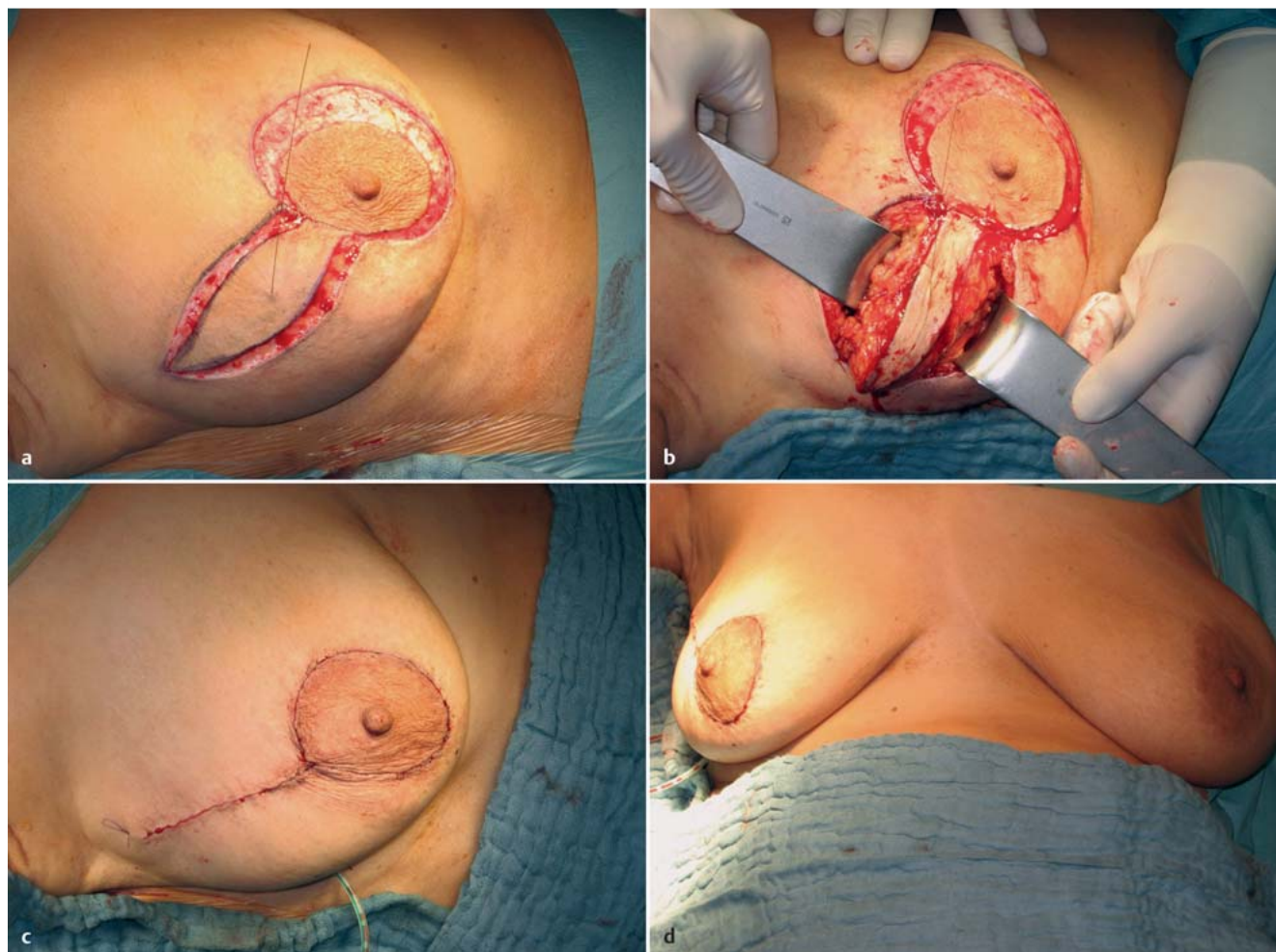


Fig. 4a to d Operative steps for tumour-adapted reduction mammoplasty. **a** Circular incision and deepithelialisation of skin. **b** Breast segment resection. **c** Immediate postoperative result after intradermal and skin closure. **d** Good symmetry after wound closure.

noeuvre a number of intramammary breast tissue flaps for fixation in the operative defect to compensate for tissue loss. The dermis and skin are then closed separately (► Fig. 4c). Occasionally it is necessary to partially divide the remaining, previously untouched periareolar dermis at the base in order to better mobilise the nipple. In most cases the nipple will be in the correct position automatically through simple adherence to the above-mentioned preparatory steps. If not, symmetrical nipple position/projection can easily be achieved through subsequent deepithelialisation (► Figs. 4d and 5a to f).

Discussion

Tumour-adapted reduction mammoplasty or the “modified B technique” is a reliable operative procedure for the excision of various volumes of tissue from almost all parts of the breast that provides reliable, complete excision of breast tumours. The time investment required for this procedure (preoperative planning, length of operation itself) is somewhat greater than for simple segmental resection via semicircular incision in the vicinity of the tumour and surgical scars are often longer because of the special incision patterns. In addition, the nipple must always be mobilized. However according to current patient survey-based

studies scar length is not a decisive factor for patient satisfaction following breast surgery. Women regard the preservation of breast shape/contour and the avoidance of retractions and asymmetry as far more important [15–20]. It should be noted though that the final, definitive aesthetic and functional result can only be appreciated months after the operation after surgical wounds have healed and radiotherapy, which is often required, completed. Radiation induced fat necrosis can cause shrinkage and distortion of the breast despite satisfactory initial postoperative results. Nevertheless, this operative technique does generally provide a good basis for favourable aesthetic outcomes in the long term.

Another advantage of tumour-adapted reduction mammoplasty is access to the axilla. By mobilizing the mammary gland appropriately from the pectoral muscles sentinel lymph node biopsy (SNB) and axillary dissection can be performed via the same incision. This is only more difficult with very immobile breasts and tumours located in the lower inner quadrant. According to the author’s own patient survey postoperative pain and movement restriction correlate more closely with the type of surgical access (separate axillary incision vs. access via tumour-adapted reduction method) than the extent of surgery in the axilla. Although in most cases tumour-adapted reduction mammoplasty provides an oncologically reliable breast conserving tumour excision with

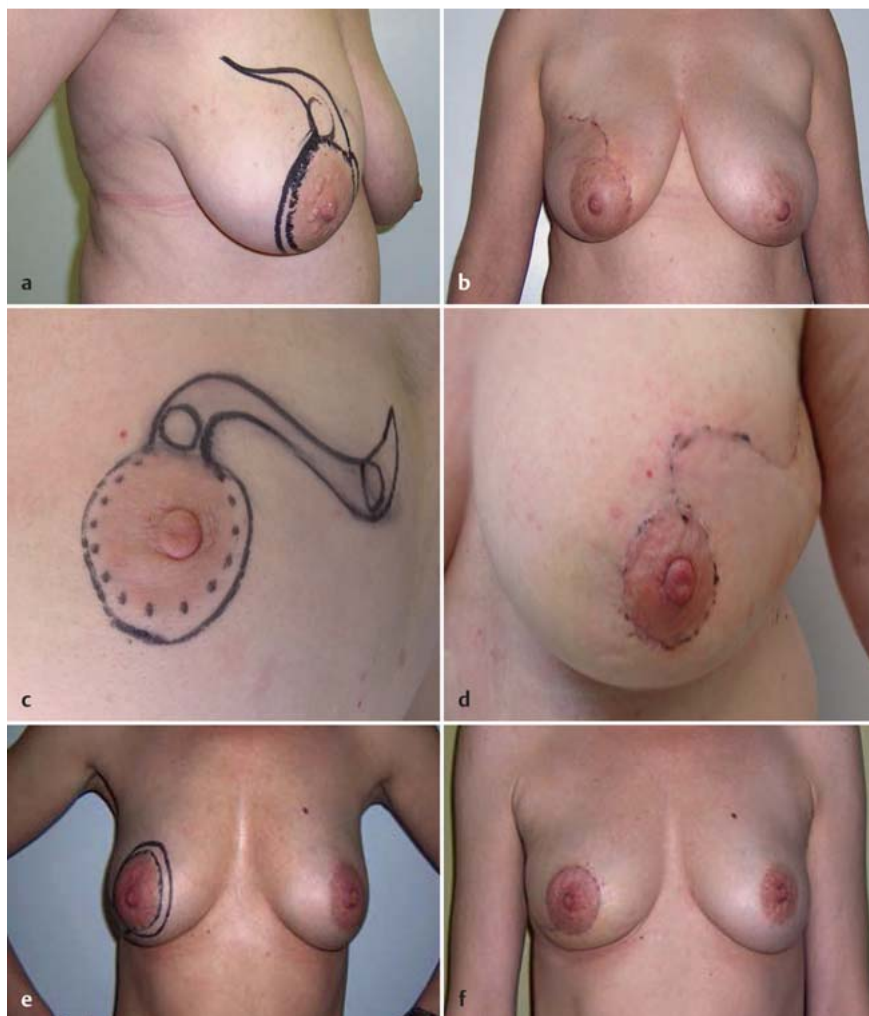


Fig. 5a to f Comparison of various pre- and postoperative findings following tumour-adapted reduction mammoplasty.

a Tumour in right upper/inner quadrant, incision markings on patient in standing position 1 day prior to surgery, semi-side on view.

b Postoperative findings in the same patient after 14 days, frontal view with patient standing.

c Undulating, S-shaped incision for multifocal breast carcinoma in the left upper/outer quadrant, incision markings 1 day prior to surgery with patient standing, semi-side on view.

d Postoperative findings in the same patient after 14 days, frontal view with patient standing.

e Tumour in right lower/outer quadrant, incision markings 1 day prior to surgery with patient standing, frontal view.

f Postoperative findings in the same patient after 14 days, frontal view with patient standing.

good aesthetic results, it does have some limitations. In individual cases with unfavourable breast-to-tumour size a skin-sparing mastectomy with its associated reconstruction options may be the better option overall, and especially from the point of view of oncological safety.

Conclusion

Tumour-adapted reduction mammoplasty/mastopexy (or the “modified B technique”), based on original work by Dufourmentel-Mouly, is a breast conserving operation for the treatment of breast carcinoma that offers an excellent chance of combining oncological certainty with convincing cosmetic results. The preservation of breast shape and nipple position is key.

Conflict of Interest

None.

References

- 1 Online: <http://www.gekid.de>; last access: 15.10.2014
- 2 Fisher B, Montague E, Redmond C et al. Findings from NSABP Protocol No. B-04-comparison of radical mastectomy with alternative treatments for primary breast cancer. I. Radiation compliance and its relation to treatment outcome. *Cancer* 1980; 46: 1–13
- 3 Fisher B, Wolmark N, Redmond C et al. Findings from NSABP Protocol No. B-04: comparison of radical mastectomy with alternative treatments. II. The clinical and biologic significance of medial-central breast cancers. *Cancer* 1981; 48: 1863–1872
- 4 Veronesi U, Salvadori B, Luini A et al. Breast conservation is a safe method in patients with small cancer of the breast. Long-term results of three randomised trials on 1,973 patients. *Eur J Cancer* 1995; 31A: 1574–1579
- 5 Veronesi U, Marubini E, Del Vecchio M et al. Local recurrences and distant metastases after conservative breast cancer treatments: partly independent events. *J Natl Cancer Inst* 1995; 87: 19–27
- 6 Heil J, Gondos A, Rauch G et al. Outcome analysis of patients with primary breast cancer initially treated at a certified academic breast unit. *Breast* 2012; 21: 303–308
- 7 Dieterich M, Dieterich H, Moch H et al. Re-excision rates and local recurrence in breast cancer patients undergoing breast conserving therapy. *Geburtsh Frauenheilk* 2012; 72: 1018–1023
- 8 Heil J, Fuchs V, Golatta M et al. Extent of primary breast cancer surgery: standards and individualized concepts. *Breast Care (Basel)* 2012; 7: 364–369
- 9 Dufourmentel C, Mouly R. [Recent developments in mammaplasty by the lateral oblique method]. *Ann Chir Plast* 1965; 10: 227–241
- 10 Dufourmentel C, Mouly R. Mammaplasty by the oblique method. *Ann Chir Plast* 1961; 6: 45–58

- 11 Schatten WE, Hartley JH jr., Hamm WG. Reduction mammoplasty by the Dufourmentel-Mouly method. *Plast Reconstr Surg* 1971; 48: 306–310
- 12 Ribeiro L. A new technique for reduction mammoplasty. *Plast Reconstr Surg* 1975; 55: 330–334
- 13 Regnault P. Reduction mammoplasty by the “B” technique. *Plast Reconstr Surg* 1974; 53: 19–24
- 14 Haloua MH, Krekel NM, Coupé VM et al. Ultrasound-guided surgery for palpable breast cancer is cost-saving: results of a cost-benefit analysis. *Breast* 2013; 22: 238–243
- 15 Haloua MH, Krekel NM, Winters HA et al. A systematic review of oncoplastic breast-conserving surgery: current weaknesses and future prospects. *Ann Surg* 2013; 257: 609–620
- 16 Heil J, Czink E, Golatta M et al. Change of aesthetic and functional outcome over time and their relationship to quality of life after breast conserving therapy. *Eur J Surg Oncol* 2011; 37: 116–121
- 17 Heil J, Dahlkamp J, Golatta M et al. Aesthetics in breast conserving therapy: do objectively measured results match patients' evaluations? *Ann Surg Oncol* 2011; 18: 134–138
- 18 Heil J, Holl S, Golatta M et al. Aesthetic and functional results after breast conserving surgery as correlates of quality of life measured by a German version of the Breast Cancer Treatment Outcome Scale (BCTOS). *Breast* 2010; 19: 470–474
- 19 Eggemann H, Krockner J, Elling D et al. Die B-Plastik – Eine retrospektive Studie zur Wertigkeit und Patientenzufriedenheit einer brusterhaltenden Therapie bei zentralem Sitz des Mammakarzinoms. *Geburtsh Frauenheilk* 2010; 70 – FV6
- 20 Rose M, Manjer J, Ringberg A et al. Surgical strategy, methods of reconstruction, surgical margins and postoperative complications in oncoplastic breast surgery. *Eur J Plast Surg* 2014; 37: 205–214