Undetected Dural Leaks Complicated by Accidental Drainage of Cerebrospinal Fluid (CSF) can Lead to Severe Neurological Deficits

Intrakranielle Hypotension und schwere neurologische Defizite nach akzidenteller Drainage von Liquor bei zuvor undetektierten Duraverletzungen

Authors P. B. Sporns, W. Schwindt, C. D. Cnyrim, W. Heindel, T. Zoubi, S. Zimmer, U. Hanning, T. U. Niederstadt

Affiliation Department of Clinical Radiology, University Hospital Münster, Germany

Key words
- dural tear
- accidental drainage
- negative pressure suction
- overdrainage
- cranial hypotension

Zusammenfassung

Ziel: Ausgeprägte intrakranielle Hypotension wurde bereits mehrfach als Komplikation akzidenteller Liquordrainage nach chirurgischen Eingriffen beschrieben. Der Einsatz von Vakuum-basierten Drainagesystemen (Wunddrainagen, VAC®-Wundsystemen, Thoraxdrainagen) führte in diesen Fällen zu lebensbedrohlichen Komplikationen wie intrakraniellen Blutungen und zerebraler Herniation. Im vergangenen Jahr konnten die Autoren 2 Fälle mit akzidenteller spinaler Drainage von Liquor diagnostizieren. Beide Patienten zeigten schwere neurologische Defizite, welche nach Entfernung des Sogs der Drainage komplett rückläufig waren.

Material und Methoden: Systematische Recherche in der Datenbank PubMed im Zeitraum 1. Januar 1980 – 1. Oktober 2015 zur Erfassung der Häufigkeit und Varietät der beschriebenen Symptome.

Ergebnisse: Die Literaturrecherche erbrachte 24 Fallberichte mit insgesamt 27 Fällen von posttraumatischem oder postoperativem Liquorverlust, welche zu neurologischen Defiziten führten. Die 15 Patienten, bei denen Drainagen mit Unterdruck verwendet wurden, zeigten schwere neurologische und radiologische Symptome wie Koma, zerebrale Herniation und intrakranielle Blutungen. Bei allen Patienten waren die Symptome nach Entfernung des Sogs der Drainagen schnell rückläufig. Bei den Patienten ohne Applikation von Unterdruck-Drainagen zeigten sich vorwiegend leichtere Symptome, wie Kopfschmerzen und Irritationen von Hirnnerven. Zusätzlich gibt diese Arbeit einen Überblick über aktuelle Empfehlungen zur kranialen und spinalen Bildgebung bei Verdacht auf intrakranielle Hypotension und zum Ausschluss spinaler Liquorleckagen.

Schlussfolgerung: Undetektierte Liquorleckagen kompliziert durch akzidentelle postoperative/posttraumatische Drainage von Liquor können zu schweren neurologischen Defiziten bei den betroffenen Patienten führen. Die zunehmende Ver-

Abstract

Purpose: Intracranial hypotension has been reported as a complication of accidental drainage after surgical treatment in several cases. Application of negative pressure systems (wound drains, VAC®-therapy, chest tube drainage) had typically led to severe intracranial hypotension including intracranial hemorrhage and tonsillar herniation. In the last year the authors observed 2 cases of accidental spinal drainage of CSF in patients with neurological deficits, regressing after reduction of the device suction.

Material and Methods: We conducted a systematic PubMed-based research of the literature to study the variety and frequency of the reported symptoms from 1st of January 1980 until 1st of October 2015.

Results: Reviewing the literature 24 relevant citations including 27 reported cases of posttraumatic or postoperative loss of CSF leading to neurological symptoms were identified. All 15 reported cases in which a negative pressure suction device had been applied showed severe neurological and radiological symptoms such as coma or brain herniation and intracranial hemorrhage. In all cases patients recovered rapidly after removal of the suction device. Milder symptoms were observed in the patients without negative pressure suction, mainly only presenting with headaches or cranial nerve involvement.

Additionally, we give an overview about current recommendations regarding cranial and spinal imaging to rule out dural laceration and cranial hypotension.

Conclusion: Patients with dural laceration complicated by accidental drainage of CSF can present with life-threatening conditions. Increasing use of negative pressure suction devices makes the reported condition an important differential diag-

received 29.10.2015
accepted 7.12.2015

Bibliography
DOI http://dx.doi.org/10.1055/s-0035-1567034
Published online: 4.2.2016
Fortschr Röntgenstr 2016; 188: 451–458 © Georg Thieme Verlag KG Stuttgart · New York · ISSN 1438-9029

Correspondence
Dr. med Peter Bernhard Sporns
Institut für Klinische Radiologie, Universitätsklinikum Münster
Albert-Schweitzer-Campus 1
Gebäude A1
48149 Münster
Germany
Tel.: ++ 49/2 51/8 34 73 01
Fax: ++ 49/2 51/8 34 96 56
peter.sporns@hotmail.de

wendung von Vakuum-basierten Drainagesystemen führt zu einer hohen Relevanz dieses Krankheitsbildes, welches somit eine wichtige Differentialdiagnose darstellt.

Kernaussagen:

- Undetektierte Liquorleckagen kompliziert durch akzidentelle postoperative/posttraumatische Drainage von Liquor können zu lebensbedrohlichen Symptomen führen.
- Die zunehmende Verwendung von Vakuum-basierten Drainagesystemen führt zu einer hohen Relevanz der Differentialdiagnose „Liquorunterdrucksyndrom“.

nosis. A precise radiological examination can help to rule out dural laceration and intracranial hypotension.

Key Points:

- Undetected dural laceration complicated by negative pressure suction drains can induce life-threatening symptoms.
- Increasing use of negative pressure suction devices makes the reported condition an important differential diagnosis for radiologists

Citation Format:

- Sporns PB, Schwindt W, Cnyrim CD et al. Undetected Dural Leaks Complicated by Accidental Drainage of Cerebrospinal Fluid (CSF) can Lead to Severe Neurological Deficits. Fortschr Röntgenstr 2016; 188: 451–458

Introduction

Intracranial hypotension may ensue spontaneously after dural puncture or accidental (intraoperative) surgical opening of the dura [1 – 3]. As a complication of this, several cases of accidental drainage after surgical treatment and application of negative pressure systems (wound drain, VAC®-therapy, chest tube drainage) have been reported. Under these circumstances severe intracranial hypotension leading to tonsillar herniation and subdural hemorrhage has been reported [4 – 7]. In the last year the authors noticed 2 cases of accidental drainage of CSF in which patients showed neurological deficits which were regressive after reduction of the device suction. In times of increasing use of negative pressure suction devices, the reported condition presents an important differential diagnosis. To the authors´ knowledge this is the first review that systematically investigates the frequency and variety of emerging symptoms.

Methods

An English-language PubMed database search using combinations of the descriptors “intracranial hypotension”, “intracranial hypovolemia”, “spinal CSF leak”, “lumbar drain”, “subdural hematoma”, “subdural hygroma”, “tonsillar herniation”, “overdrainage”, “coma”, “suction”, “dural tear”, “accidental drainage” and “cerebrospinal fluid” was conducted regarding the period from 1st of January1980 until 1st of October 2015.

Results

Reviewing the literature, 24 relevant citations including 27 reported cases of posttraumatic or postoperative loss of CSF leading to neurological symptoms were identified (**Table 1**). All 15 reported cases in which a negative pressure suction device had been applied showed severe neurological symptoms. Milder symptoms were observed in the 10 patients without negative pressure suction. In 2 patients it could not be clearly determined from the literature whether a suction drain had been applied.

Etiology

Fractures of the skull base [8] and the spine [9] can cause traumatic dural tears. In addition spontaneous CSF leaks may occur in approximately 5/100 000 patients [2, 3, 10, 11]. If the loss of CSF exceeds its production, intracranial hypotension may ensue [2, 9]. Traumatic dural tears mostly occur after severe spinal trauma. In a retrospective observational study 13 % of all patients with traumatic cervical spine injury featured a dural tear [12]. Patients with initial poor neurological state and disruption of the ligamentum flavum were more often affected [11]. Likewise, 25 % of lumbar burst fractures exhibited dural tears; all of these patients showed a neurological deficit [12]. Despite the dural tear, none of the studied patients exhibited critical intracranial hypotension [13].

Clinical Presentation

Clinical presentation of intracranial hypotension is heterogenous [1]. Typical neurological symptoms of CSF overdrainage include nausea, emesis, diplopia, orthostatic headaches, dizziness, difficulties in hearing, visual blurring [2, 10] and cranial nerve palsy [14, 15]. Current publications report on reversible coma, intracranial vasospasms [17] or even stroke and death due to intracranial hypotension [11].

After a loss of CSF of around 10 % a dilatation of cerebral sinuses, a sagging of the brain and therefore tension on sensible vessels, nerves and meninges leads to headaches [18].

Reported complications by application of negative pressure suction devices

Postoperative wound drains

Several reports of patients with severe neurological symptoms after spinal surgery and application of suction drains exist [5, 16, 20 – 24]. An overview of a few cases of postsurgical intracranial hypotension after mainly cranial and only in 2 cases spinal surgery reports about similar symptoms after opening of the dura [19]. Of sixteen patients who remained unconscious or did not become fully responsive after surgery, 4 died and 2 showed brain stem signal intensity changes in MRI. All patients had rapid intraoperative/postoperative CSF loss documented on CT and/or MR imaging studies. The authors came to the conclusion that intracranial hypotension after intracranial and spinal surgery with dural opening is potentially life threatening if patients are left with a subfascial suction drainage.

Similar cases about comatose patients with secondary pseudohypoxic brain swelling after lumbar laminectomy [5] and after thoracic and lumbar spondylodiscitis surgery have been reported [25]. The initial operative procedure in these cases was extradural. In all cases epidural suction drains (Jackson-Pratt drains) were placed in the tissue bed and the initially oriented patients became comatose. Cranial imaging showed subarachnoid hemorrhage and signs suggestive of cerebral anoxia. The fluid from the drain in one case was positive for β-2 transferrin indicating CSF [5]. This patient fully returned to baseline postoperatively, MRI normalized [5]. The radiographic findings in all cases were re-

Table 1 Patients with postsurgical and posttraumatic intracranial hypotension.

Tab. 1 Patienten mit postoperativer und posttraumatischer intrakranieller Hypotension.

posttraumatic/ postoperative	suction/ device	symptoms	imaging signs	therapy	outcome	author
postoperative, brachial plexus avulsion and reconstructive surgery	pleural drain	postural headaches, headaches worsened after aspiration of the pleural effusion	CT: tonsillar herniation and syringomyelia C1 to C7	surgical closure of the dural tear	headaches immediately resolved, MRI 4 months later: resolution of cerebellar tonsil herniation, regression of the syrinx	Scholsem [26]
posttraumatic, isolated gunshot wound to the midaxillary line through the tenth intercostal space and a complete spinal cord injury at T12	pleural drain	initially oriented, comatose with complete absence of brainstem reflexes 3 hours after admission	MRI: diffuse cerebral edema, occlusion of the bilateral posterior cerebral arteries, tonsillar herniation	none	death	Kalani [6]
postoperative, thoracic laminectomy/fusion	pleural drain	severe neurological deterioration	CT: bilateral subdural hematomas, tonsillar herniation	evacuation of subdural hematomas and bony decompression of the foramen magnum with a cerebellar tonsillectomy	regained full consciousness	Oudeman [23]
posttraumatic	VAC®	sudden neurological deterioration, coma	narrowing of basal cisterns, tonsillar cerebellar herniation	dural patch	discharge without neurologic sequelae	Sporns [7]
postoperative, decompressive laminectomies and lumbosacral arthrodesis L2-S1	subfascial wound drains	severe headache, generalized tonic clonic convulsion	CT: acute and chronic subdural and intraventricular hemorrhages	burr hole over the right parietal skull	recovered completely	Huh [36]
postoperative, posterior lumbar interbody fusion L1-L2	hemovac drain	severe headache with nausea and vomiting	CT: acute subdural hematomas	dural patch	recovered completely	Jung [37]
postoperative, bilateral L3-L4 interlaminectomies and L3-L4 discectomy	hemovac drain	left side weakness accompanied with nausea and severe headache	CT: acute cranial epidural hematoma	evacuation of the hematoma, minor dural tear was repaired	recovered completely	Grahovac [24]
postoperative, Laminectomy L4 / L5	Jackson-Pratt drain	15 s period of asystole, comatose for 3 days postoperatively	CT: traces of subarachnoid hemorrhage and signs suggestive of cerebral anoxia	removal of the drain	fully recovered on hospital day 10, MRI on hospital day 8 normalized	Fehnel [5]
postoperative, Harrington rod placement for lumbar scoliosis	Jackson-Pratt drain	abrupt deterioration in mental status	CT: tonsillar herniation with superior cerebellar infarction	removal of the drain	mental status improved slowly after removal of the drain, remained quadriparetic	Andrews [20]
postoperative, craniotomy for resection of cavernous malformation with intraoperative lumbar drainage	lumbar drain	drowsy, opened eyes to commands, oriented only to name	CT: cerebellar tonsillar herniation	lumbar blood patch, decompressive suboccipital craniectomy and C-1 laminectomy with duroplasty	lasting neuropathic pain and cervical cord signal changes on MRI	Sugrue [4]
postoperative, clipping of a ruptured aneurysm	lumbar drain	coma, signs of cranial nerves involvement, brain stem and cerebellar dysfunction	MRI: brain sagging and cerebellar tonsillar herniation	epidural blood patch, ventricular drainage, and Trendelenburg position	discharged without sequelae	Bloch [21]
postoperative, lumbar spinal surgery	lumbar drain	neurological deterioration, coma	CT: thrombosis of the superior sagittal sinus, the right transverse sinus, the right sigmoid sinus, and the right jugular vein	dural patch	recovered completely	Lourenço Costa [38]
tap test with continued CSF flow for almost 30 min	CSF tap	sudden neurological deterioration, pupils sluggishly reacting to light and generalized tonic-clonic seizures	CT: multiple infra- and supratentorial intracerebral hemorrhages with irruption into the ventricular system	ventilatory assistance	death	Ruiz-Sandoval [39]

Table 1 (Continuation)

posttraumatic/ postoperative	suction/ device	symptoms	imaging signs	therapy	outcome	author
postoperative, thoracic spondylodiscitis surgery	epidural suction drain	epileptic seizures, coma	pseudohypoxic brain swelling	removal of the drain	subsequent recovery	Parpaley [22]
postoperative, lumbar spondylodiscitis surgery	epidural suction drain	sudden neurological deterioration, coma	CT: basal ganglia, cerebellar and brainstem infarction	removal of the drain	death	Parpaley [22]
postoperative, thoracic schwannoma resection	no	intermittent headaches, right ptosis, cranial nerve III palsy	CT: small subdural hematoma MRI: diffuse leptomeningeal enhancement and crowding of the foramen magnum	conservative treatment	fully recovered	Lau [40]
postoperative, thoracic disc excision	no	acute diplopia, cranial nerve VI palsy	CT: bilateral subdural effusion	conservative treatment	recovered completely in 3 months	Khurana [41]
postoperative, thoracic disc excision	no	diplopia, occasional headaches, cranial nerve VI palsy	no	conservative treatment	recovered completely over a period of 5 months	Khurana [41]
postoperative, microscopic discectomy L5-S1	no	delayed postural headache and photophobia	MRI: enhancement of the pachymeninges CT-myelography: CSF leak	epidural blood patch, eventually direct suture plication	discharge without sequelae	Kundu [42]
postoperative, lumbar surgery for failed back syndrome	no	expressive aphasia, headache	CT: acute subdural hematoma	evacuation of the hematoma, operative dural patch	discharged without sequelae	Sciubba [16]
postoperative, incidental durotomy	no	–	extensive but reversible cerebral vasospasm	operative dural tear repair	discharged without sequelae	Chaves [17]
postoperative, spinal instrumentation surgery for scoliosis 3 months prior to her admission	no	headaches	CT: thoracic pedicle screw penetrating and transversing the dura mater at the T3-T4 level	dural patch, revision of the screw	recovered completely	Albayram [43]
postoperative, surgery for a nerve sheet tumor originating at the level of the right second neural root	no	horizontal diplopia occurred, palsy of the left abducens nerve	cranial MRI: diffuse pachymeningitis thoracic MRI: pseudomeningocele around the second intervertebral foramen	conservative management	complete recovery 6 months later	Bobbio [44]
postoperative, spinal surgery for severe myelodysplastic scoliosis	no	aphasic, somnolent	CT: massive subdural hematoma, pneumocephalus, pneumorrachis and a malpositioned pedicular screw	cranial decompression and spinal reoperation with dural tear repair	recovered completely	Nowak [45]
caudal epidural injection	no	orthostatic headache with generalized weakness and syncopal episodes	no	epidural blood patch	recovered completely	Thomas [46]
postoperative, spondylodiscitis T6/7	–	–	CT: compressed ambient cisterns, basal ganglia hypoattenuation	–	recovered completely	Hadizadeh [19]
postoperative, Spondylodiscitis L4/5, spinal fixation	–	–	MRI: brain stem and thalamic/basal ganglia lesions	–	death	Hadizadeh [19]

No = no drain used, – = no information available.

ported to be most consistent with acute intracranial hypotension relating to acute loss of CSF.

Two patients in the literature presented with neurogenic shock after posterior lumbar interbody fusion (PLIF). One patient showed bradycardia and the other developed cardiac arrest just after the surgical incision was closed and the drainage tube opened. In these cases incarceration of multiple cauda equina rootlets after the accidental dural tear by suction drainage seems to have caused a sudden decrease of cerebrospinal fluid pressure and traction of the cauda equina, which may have led to the vasovagal reflex. This shows that not only cranial but other life-threatening conditions can occur.

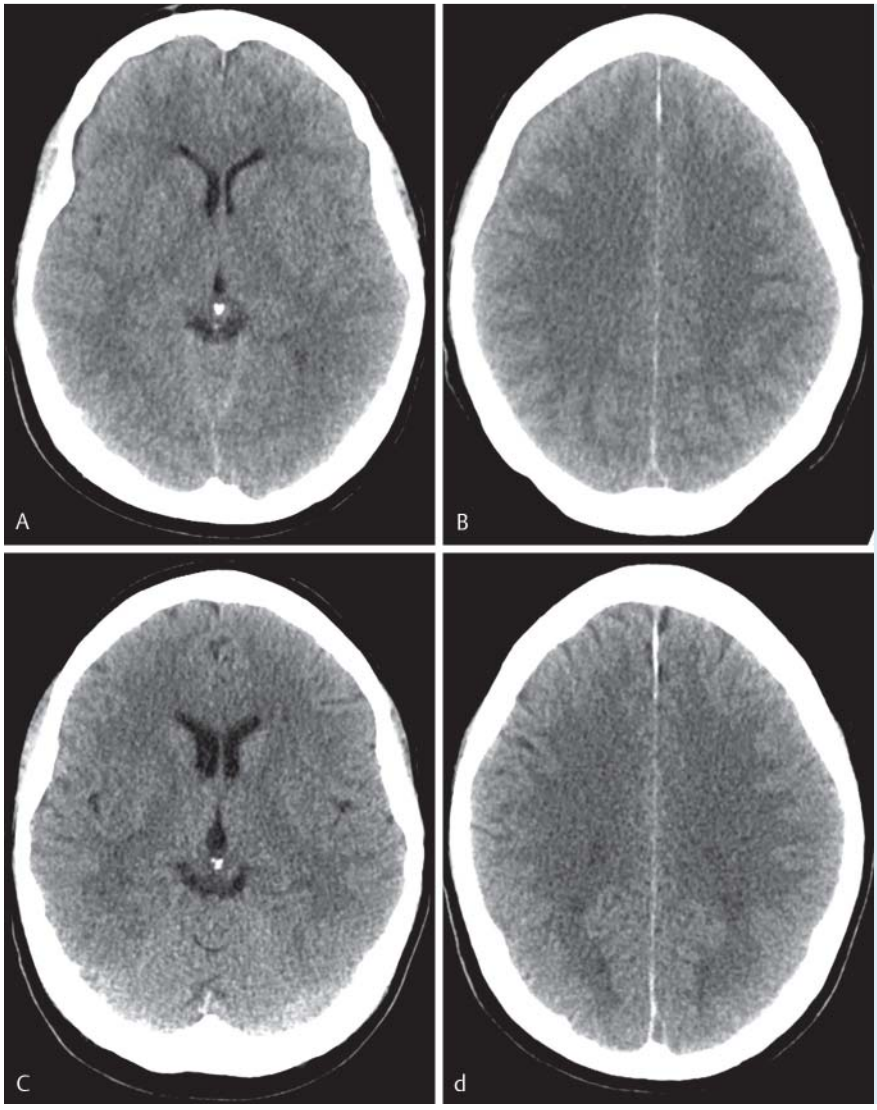

Fig. 1 Previously unreported case of a patient who underwent lumbar stabilization. After application of a suction drain the cranial CT shows a frontal hygroma **A+B** on the right and effacement of the sulci **B**. After removal of the drain the cranial CT three days later is normal; ventricular size has increased **C+D**.

Abb. 1 Noch nicht veröffentlichter Fall eines Patienten nach lumbaler, dorsaler Stabilisierung. Nach Anlage einer lumbalen Unterdruckdrainage zeigt das axiale Schädel-CT ein frontales Hygrom rechts **A+B** und ein Verstreichen der Sulci **B**.Nach Entfernung der Drainage ist das Kontroll-CT 3 Tage später wieder normal, die Ventrikelweite hat wieder zugenommen **C+D**.

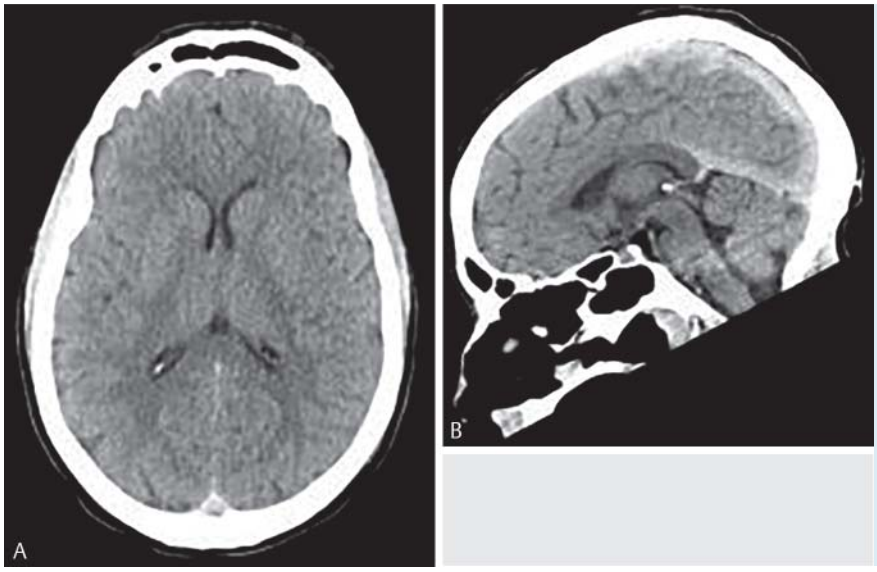

Fig. 2 Previously reported case of a patient who had severe intracranial hypotension after VAC® wound therapy. Computed tomography (CT) of the head before VAC® application; **A** Head axial and **B** Head sagittal MPR showing a normal cranial CT.

Abb. 2 Bereits vorab veröffentlichter Fall eines Patienten mit schwerer intrakranieller Hypotension nach Anlage eines VAC-Wundverbandes. Das CT vor VAC-Applikation ist unaufällig **A+B**.

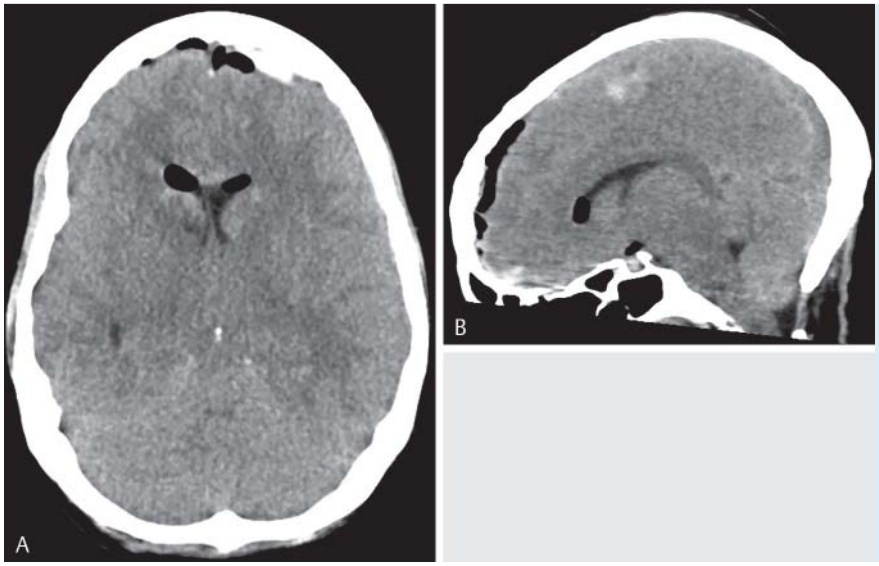

Fig. 3 CT-scan head after VAC® application; **A** axial showing an effacement of the basal cisterns and intracranial/intraventricular air after implantation of an EVD. Note the "slit like" ventricles. **B** (sagittal MPR) is showing a sagging of the brain with lowering of the cerebellar tonsils (tonsillar herniation).

Abb. 3 Das CT nach VAC-Applikation; **A** axial zeigt ein Verstreichen der basalen Zisternen und intrakranielle/intraventrikuläre Luft nach Anlage einer EVD. Zudem sind die Ventrikel nur noch schlitzförmig abgrenzbar. **B** (sagittale MPR) zeigt das Tiefertreten des Hirns mit Verlagerung der Kleinhirntonsillen in das Foramen magnum (Tonsilläre Herniation).

Report of a new Case

A previously unreported patient underwent lumbar stabilization. A suction drain was applied in the tissue bed and in the postoperative course the patient developed a global aphasia and disorientation. The head CT showed a frontal hygroma on the right and an effacement of the sulci (▶ **Fig. 1A, B**). The drain was removed immediately and the neurological symptoms of the patient fully recovered on the same day. A control CT three days later was normal (▶ **Fig. 1C, D**).

VAC® therapy

Recently we have reported about a polytraumatized patient with a life-threatening event of intracranial hypotension after VAC® wound therapy [7]. This patient had suffered a pelvic fracture after a motor vehicle accident. Initial cranial CT was normal (▶ **Fig. 2**). After application of a VAC® wound dressing, the initially oriented patient became nonresponsive. The following cranial CT showed signs of intracranial hypotension (▶ **Fig. 3**). Pneumorrhachis in native CT indicated a dural tear (▶ **Fig. 4**) which was confirmed by CT myelography at L5/S1 level (▶ **Fig. 5**) and consequently the VAC® was removed. After application of a dural patch the patient was oriented post-operatively and the cranial CT improved to a normal state (▶ **Fig. 6**).

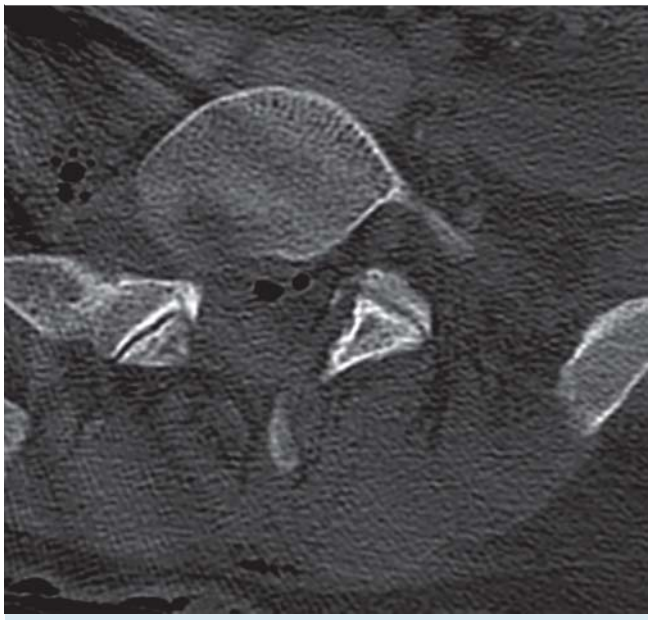

Fig. 4 The axial CT is showing intrathecal air called "pneumorrhachis".

Abb. 4 Das axiale CT zeigt intrathekale Luft; „Pneumorrhachis".

Chest tube drainage

Posttraumatic CSF loss with loss of consciousness and tonsillar herniation has been reported as a complication of chest tube drainage after spinal injury [6]. The patient presented to the trauma service awake, alert, and oriented with an isolated gunshot wound leading to a complete spinal cord injury at T12. A chest tube was placed, and the patient was found to be comatose with complete absence of brainstem reflexes 3 hours after admission. MRI and autopsy revealed diffuse cerebral edema, occlusion of the bilateral posterior cerebral arteries, and tonsillar herniation extending several centimeters below the foramen magnum, with petechial hemorrhages and absence of gliosis.

Another case of tonsillar herniation and syringomyelia after brachial plexus avulsion and reconstructive surgery with a cerebrospinal fluid leak between the cervical subarachnoid space and the pleural cavity has been reported [26]. The patient showed a persistent right pleural effusion for about four months after reconstructive surgery for a right brachial plexus avulsion. Initially present headaches had worsened considerably after two aspirations of the pleural effusion. MRI demonstrated signs of chronic intracranial hypotension and tonsillar herniation with a presyrinx cavity from vertebral level C1 to C7. Plexus brachial MRI confirmed the presence of a cerebrospinal fluid leak between the avulsed root of C8 and the pulmonary apex. After dural closure, the patient's headaches immediately resolved, and MRI four months later showed resolution of cerebellar tonsillar herniation and regression of the syrinx.

Radiological Examination

Cranial Imaging

Typical imaging signs of intracranial hypotension which can be depicted in CT and MRI include "slit like" lateral ventricles, subdural fluid collections and effacement of sulci, as well as the downward

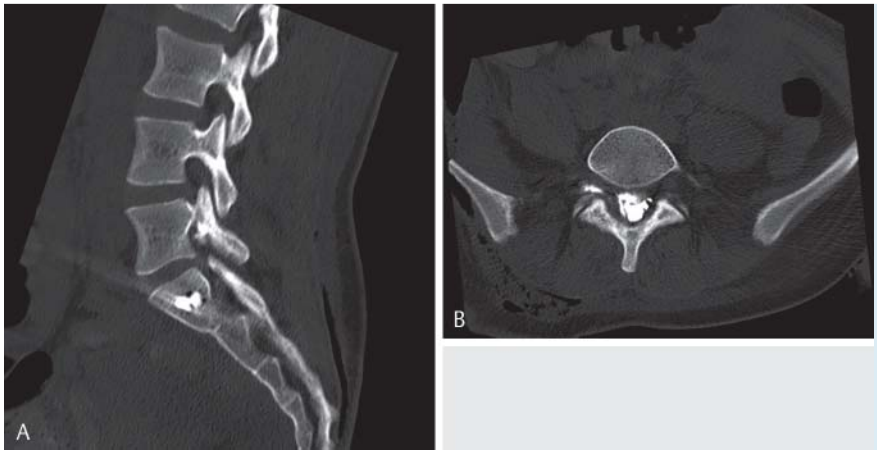

Fig. 5 CT-myelography; **A** sagittal and **B** axial MPR show a CSF leak L5 / S1 on the right.

Abb. 5 Die CT-Myelographie; **A** sagittale und **B** axiale MPR zeigt ein Liquorleck auf Höhe L5/S1 rechts.

Fig. 6 CT-scan head; the sagittal MPR five days after removal of the VAC shows a regressive lowering of the cerebellar tonsils.

Abb. 6 Das abschließende Schädel-CT fünf Tage nach Entfernung des VAC zeigt eine Zurückverlagerung der Kleinhirntonsillen in die ursprüngliche Position.

transtentorial herniation of the brain with the "sagging brain" appearance [1, 19, 27]. Imaging modality of choice is an MRI of the head. Features include thickening and enhancement of the dura after contrast application, enlargement of venous structures with dilation of the intracranial dural sinuses and spinal epidural plexuses, and engorgement of the pituitary gland [1, 19]. Moreover hyperintensities in the thalamus/basal ganglia, brain stem, and cerebellum have been reported as a possible result of impaired drainage through the internal cerebral veins and the vein of Galen into the straight sinus [19, 25].

Subdural hygromas, often bihemispheric and with an infratentorial predominance, usually are named as a typical imaging finding [3, 19]. However, they were only found in 30 % of patients and did not correlate with clinical outcome parameters [19].

Spinal Imaging

A possible indication for traumatic dural laceration may be pneumorrhachis, well discernible in CT [13, 28]. With MRI, dural tears can be detected using fluid-sensitive and fat-suppressive sequences. Typical are fluid collections along the paravertebral tissue and spinal nerves [29]. MRI is the modality of choice for depicting plexus injuries and nerve root avulsions which can be associated with dural laceration [30, 31]. For this purpose MR neurography shows first promising results [32, 33]. Using CT or MR myelography with adjunction of intrathecal contrast medium loss of CSF can directly be detected [7, 34, 35]. However, this contains a risk of herniation or postpunctional CSF depletion.

Conclusion

In most of the cases with severe neurological symptoms, in addition to the dural tear, extra negative pressure had been applied. This implies that apart from the dural tear, additional factors such as suction of cerebrospinal fluid are needed to induce severe symptoms. In conclusion, patients with suspected dural laceration complicated by accidental drainage of CSF can present with life-threatening conditions. Increasing use of negative pressure suction devices makes the reported condition an important differential diagnosis so that acute intracranial hypotension should be considered as an explanation of postoperative coma after cranial or spinal surgery. A precise radiological examination can help to rule out dural laceration and intracranial hypotension.

References

1 *Urbach H.* Intracranial hypotension: Clinical presentation, imaging findings, and imaging-guided therapy. Curr Opin Neurol 2014; 27: 414 – 424
2 *Mokri B.* Spontaneous CSF leaks: Low CSF volume syndromes. Neurol Clin 2014; 32: 397 – 422
3 *Hoffmann J, Goadsby PJ.* Update on intracranial hypertension and hypotension. Curr Opin Neurol 2013; 26: 240 – 247
4 *Sugrue PA, Hsieh PC, Getch CC et al.* Acute symptomatic cerebellar tonsillar herniation following intraoperative lumbar drainage. J Neurosurg 2009; 110: 800 – 803
5 *Fehnel CR, Razmara A, Feske SK.* Coma from wall suction-induced CSF leak complicating spinal surgery. BMJ Case Rep 2014; 2014 10.1136/bcr,2014-203801
6 *Kalani MY, Filippidis A, Martirosyan NL et al.* Cerebral herniation as a complication of chest tube drainage of cerebrospinal fluid after injury to the spine. World Neurosurg 2013; 79: 798.E17 – 798.E19

7 *Sporns PB, Zimmer S, Hanning U et al.* Acute tonsillar cerebellar herniation in a patient with traumatic dural tear and VAC therapy after complex trauma. Spine J 2015; 15: e13 – e16
8 *Baugnon KL, Hudgins PA.* Skull base fractures and their complications. Neuroimaging Clin N Am 2014; 24: 439 – 465, vii-viii
9 *Luszczyk MJ, Blaisdell GY, Wiater BP et al.* Traumatic dural tears: What do we know and are they a problem? Spine J 2014; 14: 49 – 56
10 *Mokri B.* Spontaneous low pressure, low CSF volume headaches: Spontaneous CSF leaks. Headache 2013; 53: 1034 – 1053
11 *Schievink WI.* Stroke and death due to spontaneous intracranial hypotension. Neurocrit Care 2013; 18: 248 – 251
12 *Lee SE, Chung CK, Jahng TA et al.* Dural tear and resultant cerebrospinal fluid leaks after cervical spinal trauma. Eur Spine J 2014; 23: 1772 – 1776
13 *Oertel MF, Korinth MC, Reinges MH et al.* Pathogenesis, diagnosis and management of pneumorrhachis. Eur Spine J 2006; 15: 636 – 643
14 *Rahman M, Bidari SS, Quisling RG et al.* Spontaneous intracranial hypotension: Dilemmas in diagnosis. Neurosurgery 2011; 69: 4 – 14; discussion 14
15 *Khemka S, Mearza AA.* Isolated sixth nerve palsy secondary to spontaneous intracranial hypotension. Eur J Neurol 2006; 13: 1264 – 1265
16 *Sciubba DM, Kretzer RM, Wang PP.* Acute intracranial subdural hematoma following a lumbar CSF leak caused by spine surgery. Spine (Phila Pa 1976) 2005; 30: E730 – E732
17 *Chaves C, Freidberg SR, Lee G et al.* Cerebral vasospasm following intracranial hypotension caused by cerebrospinal fluid leak from an incidental lumbar durotomy. Case report. J Neurosurg 2005; 102: 152 – 155
18 *Thomke F, Bredel-Geissler A, Mika-Gruttner A et al.* Spontaneous intracranial hypotension syndrome. Clinical, neuroradiological and cerebrospinal fluid findings. Nervenarzt 1999; 70: 909 – 915
19 *Hadizadeh DR, Kovacs A, Tschampa H et al.* Postsurgical intracranial hypotension: Diagnostic and prognostic imaging findings. Am J Neuroradiol 2010; 31: 100 – 105
20 *Andrews RT, Koci TM.* Cerebellar herniation and infarction as a complication of an occult postoperative lumbar dural defect. Am J Neuroradiol 1995; 16: 1312 – 1315
21 *Bloch J, Regli L.* Brain stem and cerebellar dysfunction after lumbar spinal fluid drainage: Case report. J Neurol Neurosurg Psychiatry 2003; 74: 992 – 994
22 *Parpaley Y, Urbach H, Kovacs A et al.* Pseudohypoxic brain swelling (postoperative intracranial hypotension-associated venous congestion) after spinal surgery: Report of 2 cases. Neurosurgery 2011; 68: E277 – E283
23 *Oudeman EA, Nandoe Tewarie RD, Jobsis GJ et al.* Complications corner: Anterior thoracic disc surgery with dural tear/CSF fistula and low-pressure pleural drain led to severe intracranial hypotension. Surg Neurol Int 2015; 6: S137 – S139
24 *Grahovac G, Vilendecic M, Chudy D et al.* Nightmare complication after lumbar disc surgery: Cranial nontraumatic acute epidural hematoma. Spine (Phila Pa 1976) 2011; 36: E1761 – E1764
25 *Van Roost D, Thees C, Brenke C et al.* Pseudohypoxic brain swelling: A newly defined complication after uneventful brain surgery, probably related to suction drainage. Neurosurgery 2003; 53: 1315 – 1326; discussion 1326–1327
26 *Scholsem M, Scholtes F, Belachew S et al.* Acquired tonsillar herniation and syringomyelia after pleural effusion aspiration: Case report. Neurosurgery 2008; 62: E1172 – E1173; discussion E1173
27 *Loya JJ, Mindea SA, Yu H et al.* Intracranial hypotension producing reversible coma: A systematic review, including three new cases. J Neurosurg 2012; 117: 615 – 628
28 *Gelalis ID, Karageorgos A, Arnaoutoglou C et al.* Traumatic pneumorrhachis: Etiology, pathomechanism, diagnosis, and treatment. Spine J 2011; 11: 153 – 157
29 *Medina JH, Abrams K, Falcone S et al.* Spinal imaging findings in spontaneous intracranial hypotension. Am J Roentgenol 2010; 195: 459 – 464
30 *Caranci F, Briganti F, La Porta M et al.* Magnetic resonance imaging in brachial plexus injury. Musculoskelet Surg 2013; 97: S181 – S190
31 *Sporns PB, Fortmann T, Zimmer S et al.* Traumatische Plexusläsion mit zervikothorakalen Wurzelausrissen und vertikaler Lazeration des Myelons. Fortschr Röntgenstr 2015; 187: 938 – 939
32 *Chhabra A, Thawait GK, Soldatos T et al.* High-resolution 3T MR neurography of the brachial plexus and its branches, with emphasis on 3D imaging. Am J Neuroradiol 2013; 34: 486 – 497
33 *Soldatos T, Andreisek G, Thawait GK et al.* High-resolution 3-T MR neurography of the lumbosacral plexus. Radiographics 2013; 33: 967 – 987
34 *Schievink WI.* Spontaneous spinal cerebrospinal fluid leaks and intracranial hypotension. JAMA 2006; 295: 2286 – 2296
35 *Mokri B.* Cerebrospinal fluid volume depletion and its emerging clinical/imaging syndromes. Neurosurg Focus 2000; 9: e6
36 *Huh J.* Burr hole drainage: Could be another treatment option for cerebrospinal fluid leakage after unidentified dural tear during spinal surgery? J Korean Neurosurg Soc 2013; 53: 59 – 61
37 *Jung YY, Ju CI, Kim SW.* Bilateral subdural hematoma due to an unnoticed dural tear during spine surgery. J Korean Neurosurg Soc 2010; 47: 316 – 318
38 *Lourenco Costa B, Shamasna M, Nunes J et al.* Cerebral venous thrombosis: An unexpected complication from spinal surgery. Eur Spine J 2014; 23: 253 – 256
39 *Ruiz-Sandoval JL, Campos A, Romero-Vargas S et al.* Multiple simultaneous intracerebral hemorrhages following accidental massive lumbar cerebrospinal fluid drainage: Case report and literature review. Neurol India 2006; 54: 421 – 424
40 *Lau D, Lin J, Park P.* Cranial nerve III palsy resulting from intracranial hypotension caused by cerebrospinal fluid leak after paraspinal tumor resection: Etiology and treatment options. Spine J 2011; 11: e10 – e13
41 *Khurana A, Brousil J, Russo A et al.* Intracranial hypotension with a sixth cranial nerve palsy subsequent to massive thoracic CSF hygroma: A rare complication of thoracic disc excision. Eur Spine J 2013; 22: 2047 – 2054
42 *Kundu A, Sano Y, Pagel PS.* Case report: Delayed presentation of postural headache in an adolescent girl after microscopic lumbar discectomy. Can J Anaesth 2008; 55: 696 – 701
43 *Albayram S, Ulu MO, Hanimoglu H et al.* Intracranial hypotension following scoliosis surgery: Dural penetration of a thoracic pedicle screw. Eur Spine J 2008; 17: S347 – S350
44 *Bobbio A, Hamelin-Canny E, Roche N et al.* Abducens nerve palsy after schwannoma resection. Ann Thorac Surg 2015; 99: 694 – 695
45 *Nowak R, Maliszewski M, Krawczyk L.* Intracranial subdural hematoma and pneumocephalus after spinal instrumentation of myelodysplastic scoliosis. J Pediatr Orthop B 2011; 20: 41 – 45
46 *Thomas R, Thanthulage S.* Intracranial hypotension headache after uncomplicated caudal epidural injection. Anaesthesia 2012; 67: 416 – 419