

Heart-Failing Jehovah's Witness Patient Successfully Treated by Minimally Invasive LVAD Implantation without Any Blood Transfusions

Jasmin S. Hanke¹ Murat Avsar¹ Axel Haverich¹ Jan D. Schmitto¹

¹Department of Cardiac, Thoracic, Transplantation and Vascular Surgery, Hannover Medical School, Hannover, Germany

Thorac Cardiovasc Surg Rep 2015;4:21–24.

Address for correspondence PD Dr. Jan D. Schmitto, Department of Cardiac, Thoracic, Transplantation and Vascular Surgery, Hannover Medical School, Carl Neuberg Str 1, Hannover 30625, Germany (e-mail: hanke.jasmin@mh-hannover.de).

Abstract

Left ventricular assist device (LVAD) implantation without the use of any blood products is considered as a challenge. We present a 48-year-old patient (175 cm, 75 kg, body mass index 24.5 kg/m²) who was admitted to our clinic due to end-stage heart failure. The patient is a Jehovah's witness. He declined full blood transfusion as well as use of coagulation factors. Therefore, we interdisciplinary decided to implant an LVAD via minimally invasive technique. The patient experienced an uneventful intrahospital stay and was successfully discharged home on his 17th postoperative day, proving that LVAD implantation without blood transfusions is possible by using a minimally invasive technique. This benefits not only Jehovah's witness patients, but also all patients in need of an LVAD.

Keywords

- ▶ minimally invasive
- ▶ LVAD
- ▶ left ventricular assist device
- ▶ Jehovah's witness

Introduction

Minimally invasive left ventricular assist device (LVAD) implantation has proven in the past years that it is a superior technique to conventional LVAD implantation.¹ The less invasive procedure has several benefits such as reducing right heart failure, reducing wound infection, and shorter duration of procedure as well shorter intrahospital stay for the patient. Also, it is associated with a diminished usage of blood products due to less bleeding complications.^{2,3}

Surgery on Jehovah's witnesses is always a challenge for surgeons, too. This society has remarkably grown and counts over 7 million followers worldwide today. According to Jehovah's witnesses' interpretation of the Bible, it is prohibited to ingest blood of any kind. It is up to the conscious of each individual to accept transfusions of fractionations of the primary components.^{4,5} Especially cardiac surgeries have a higher risk for blood loss with the need of blood transfusions. This creates a difficult situation for the patient and for the doctor who is legally bound to provide best medical care to every patient. Therefore, a minimally invasive LVAD implan-

tation technique was used when a Jehovah's witness was referred to our clinic with end-stage heart failure.

Results

We present a 48-year-old patient (175 cm, 75 kg, body mass index 24.5 kg/m²) who was admitted to our clinic due to acute decompensation of dilative cardiomyopathy. The patient presented the signs of hypotonic pressures, dyspnoea, tachycardia, and acrocyanosis.

Echocardiography was performed and showed a severe decrease of left ventricular ejection function (13% [Simpson]) and a reduced right ventricular function as well as a second-degree mitral valve insufficiency. Laboratory parameters showed decreased liver and renal function. Due to respiratory insufficiency, noninvasive ventilation became necessary. The history of the patient showed a possible case of viral myocarditis 18 years ago. Dilated cardiomyopathy was diagnosed 8 years ago. After multiple attempts to medically stabilize the condition of the patient, the case was presented

received
July 13, 2015
accepted after revision
August 10, 2015
published online
October 29, 2015

DOI <http://dx.doi.org/10.1055/s-0035-1564614>.
ISSN 2194-7635.

© 2015 Georg Thieme Verlag KG
Stuttgart · New York

License terms



to the cardiovascular surgery department (►Fig. 1). In an interdisciplinary discussion, it was decided to implant a mechanical assist device. The patient was a Jehovah's witness and approved LVAD implantation but declined the use of any blood products even in emergency situations.

The procedure was performed with our minimally invasive LVAD implantation technique, which combines an upper ministernotomy with an anterolateral thoracotomy.¹ Via anterolateral thoracotomy, the sewing ring of the HVAD (HeartWare) was sewed onto the beating heart. The venous line of the heart–lung machine was placed in the femoral vein. The arterial line was placed via ministernotomy to the ascending aorta. After starting of the heart–lung machine, the assist device was placed into the left ventricle. The outflow graft cannula was tunneled through the pleural cavity and sewed onto the ascending aorta. The weaning from the heart–lung machine was completely uneventful. The procedure was performed without any use of blood products including thrombocytes, fresh frozen plasma, or any other coagulation factors (►Fig. 2).

Laboratory parameters showed preoperative blood hemoglobin (Hb) and hematocrit (Hct) just before the operation of 11.3 g/dL and 33.1%, respectively. Mean Hb during the preoperative hospital stay (16 days) was 9 g/dL with standard deviation (SD) of 0.50 mg/dL and mean Hct was 35% with SD of 1.49%. The first parameters obtained immediately after the operation were 9.3 g/dL and 27% for Hb and Hct, respectively. Postoperative data showed mean Hb of 8.53 g/dL with SD of 1.79 g/dL and mean Hct of 25.70% with SD of 5.21%. The patient was discharged after a completely uneventful intrahospital stay on postoperative day 17. Hb and Hct on the day of discharge were 13.1 g/dL and 37.5%, respectively. Mean Hb of 9.31 g/dL with SD of 2.11 g/dL and mean Hct of 27.87% with SD of 6.01% were calculated from data obtained during the total hospital stay of 35 days (►Fig. 3).

Discussion

The reduction of blood loss is a goal for all surgeries. Especially LVAD implantations are considered to be prone to high blood loss

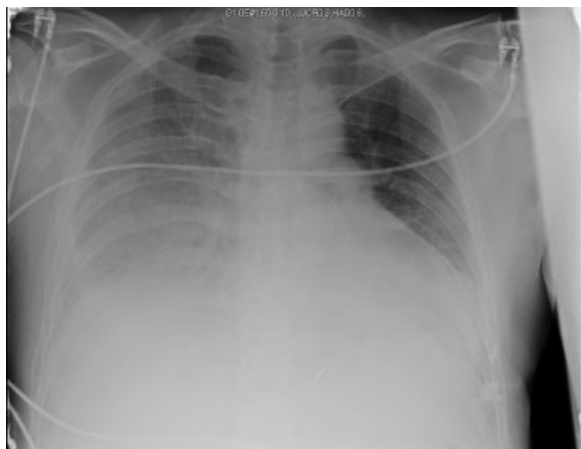

Fig. 1 Chest X-ray before LVAD implantation.

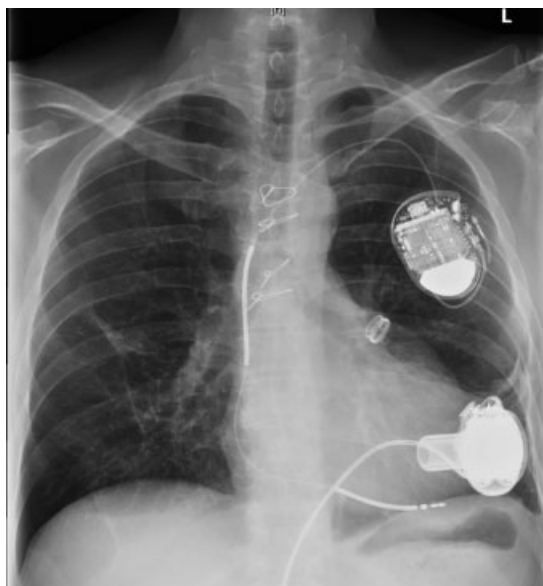


Fig. 2 Chest X-ray after LVAD implantation.

and high usage of coagulation factors. Even though tested multiple times before transfusion, blood products still contain risks for allergic reactions to transfusion of infectious diseases. Furthermore, economic costs for blood products are one of the major contributors for the high costs of LVAD implantation. Therefore, the reduction of usage of blood products is one of the keys to lowering the cost for LVAD programs.

Minimally invasive LVAD implantation, first described by our group, has already proven itself to be associated with several positive effects. It has been shown that the total number of blood transfusion was reduced by implanting an LVAD via a minimally invasive technique.^{1–3} Now, it is proven that it is even possible to implant an LVAD minimally invasively without the use of any blood products. As devices become smaller, incision sites should reduce in size as well.

Despite the excellent result of this procedure, the surgical approach as well as the risk and consequences of blood loss must be intensively discussed with the patient. In our case, the patient accepted blood transfusions only in the case of imminent death due to blood loss. Although a case of heart transplantation in a Jehovah's witness has been described,⁶ the therapeutic goal of our patient is destination therapy with LVAD support. In case of reoperation, our strategy is minimally invasive LVAD exchange without the use of the heart–lung machine.⁷

Conclusion

It has been proven that minimally invasive LVAD implantation without blood transfusion is possible. This benefits not only Jehovah's witness patients but also all patients in the need of a ventricular assist device. Yet, the course of the patients has to be kept in mind, which may require further interventions with the need of blood transfusion. Therefore, LVAD implantation in Jehovah's witnesses should be a critically evaluated procedure.

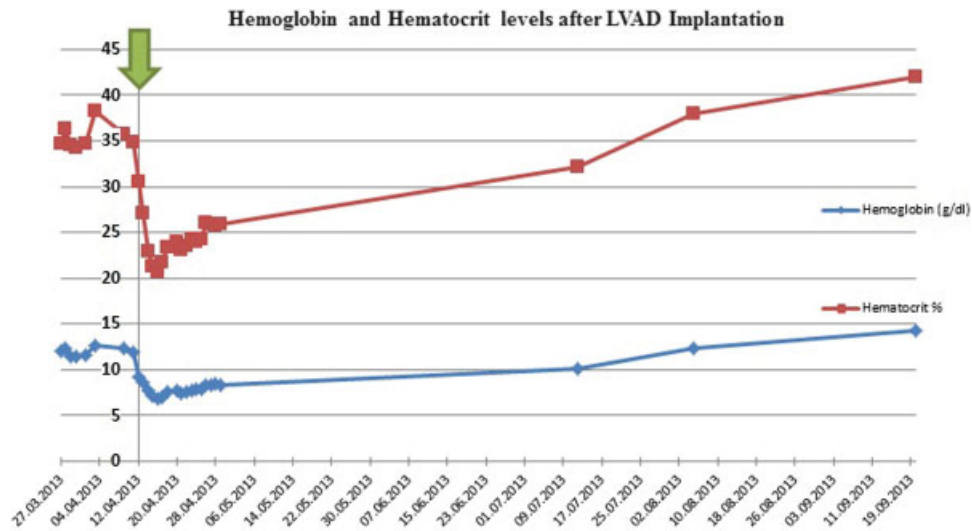


Fig. 3 Charts showing the hemoglobin and hematocrit values during the hospital stay.

Disclosures

The authors have no disclosures.

References

- Schmitto JD, Molitoris U, Haverich A, Strueber M. Implantation of a centrifugal pump as a left ventricular assist device through a novel, minimized approach: upper hemisternotomy combined with anterolateral thoracotomy. *J Thorac Cardiovasc Surg* 2012; 143(2):511–513
- Schmitto JD, Rojas SV, Hanke JS, Avsar M, Haverich A. Minimally invasive left ventricular assist device explantation after cardiac recovery: surgical technical considerations. *Artif Organs* 2014; 38(6):507–510
- Haberl T, Riebandt J, Mahr S, et al. Viennese approach to minimize the invasiveness of ventricular assist device implantation. *Eur J Cardiothorac Surg* 2014;46(6):991–996, discussion 996
- Vaislic CD, Dalibon N, Ponzio O, et al. Outcomes in cardiac surgery in 500 consecutive Jehovah's Witness patients: 21 year experience. *J Cardiothorac Surg* 2012;7:95
- Jassar AS, Ford PA, Haber HL, et al. Cardiac surgery in Jehovah's Witness patients: ten-year experience. *Ann Thorac Surg* 2012; 93(1):19–25
- Dallas T, Welsby I, Bottiger B, Milano C, Daneshmand M, Guinn N. Bloodless orthotopic heart transplantation in a Jehovah's witness. *AA Case Rep* 2015;4(10):140–142
- Rojas SV, Avsar M, Khalpey Z, Hanke JS, Haverich A, Schmitto JD. Minimally invasive off-pump left ventricular assist device exchange: anterolateral thoracotomy. *Artif Organs* 2014;38(7):539–542

Editor's Commentary

Heart Failing Jehovah Witness Patient Successfully Treated by Minimally-Invasive Left Ventricular Assist Device Implantation without any Blood Transfusions

Andreas Böning¹ Christof Schmid²¹

Klinik für Herz-, Kinderherz- und Gefäßchirurgie, UKGM, Standort Giessen, Germany
Klinik für Herz-, Thorax- und Herznahe Gefäßchirurgie, Universitätsklinikum Regensburg, Regensburg, Germany

Address for correspondence Prof. Dr. Andreas Böning, Klinik für Herz-, Kinderherz- und Gefäßchirurgie, UKGM, Standort Giessen, Germany (e-mail: andreas.boening@chiru.med.uni-giessen.de).

What sounds like a headline of a newspaper is the title of a case report regarding cardiac surgery in a high-risk patient, namely, a patient undergoing left ventricular assist device (LVAD) implantation for heart failure treatment. The authors were courageous enough to implant a LVAD in a Jehovah witness, a Christian denomination whose members categorically refuse blood transfusions. They have to be congratulated upon this minimally invasive procedure.

Nowadays, cardiac surgeons usually do not have a problem performing coronary artery bypass graft surgery (off- or on-pump, probably with a mini-extracorporeal circulation) without blood transfusion. The same is true for isolated aortic valve replacement.

However, LVAD implantation is a different story: Even if the primary implantation is successful without blood transfusions, the risk with the currently most-used LVADs (Heartmate II, Heartware) is still high that transfusion may be required. Several reports show that gastrointestinal bleeding occurs in 30 to 40% of LVAD recipients and,

moreover, the threat of thromboembolism calls for repeated alteration of anticoagulation and transfusion of red blood cells and clotting factors after LVAD implantation. Another major problem is device infection, which can usually only be treated by device replacement. Can this be done without transfusion?

Moreover, at a young age of 48 years it is foreseeable that this patient will suffer severe device complications rendering heart transplantation as the only and final option.

Will the authors do the transplantation as a reoperation with an LVAD without transfusion as well?

Considering these questions, it may not be fair convincing Jehovah witnesses that LVAD implantation can be safely performed without the risks of blood loss and—subsequently—transfusion, and that LVADs assure a better quality of life in the long-term. Finally, in case of bleeding, again the old ethical dilemma for the treating surgeons arises: to give the patient a blood transfusion against his explicit will or to let the patient die.