Polyethylene Tibial Post Fracture in a Posterior Stabilized (Genesis II) Total Knee Arthroplasty

Stephen A. Rodes, MD[1] Angelo J. Colosimo, MD[1] Kimberly A. Hasselfeld, MS[1]

[1] Department of Orthopaedics and Sports Medicine, University of Cincinnati College of Medicine, Cincinnati, Ohio

J Knee Surg Rep 2015;1:60–63.

Address for correspondence Kimberly Hasselfeld, MS, Department of Orthopaedics and Sports Medicine, University of Cincinnati, PO Box 670212, Cincinnati, OH 45267-0212 (e-mail: hasselky@uc.edu; kim.hasselfeld@gmail.com).

Abstract

This study reports the case of a fractured polyethylene tibial post in a 49-year-old white male patient at 4 years status post a left posterior stabilized total knee arthroplasty. The patient was doing extremely well postoperatively until he felt pain in the left knee while completing personal resistance squats. He was found to have anterior/posterior instability in flexion as well as midflexion instability. The patient underwent removal of the fractured polyethylene insert and replacement with a thicker insert. The patient had immediate resolution of his preoperative pain and instability. To our knowledge, this is the first reported case of a polyethylene tibial post fracture in a Genesis II total knee system (Smith and Nephew; Memphis, TN).

Keywords
- Genesis II
- posterior stabilized knee
- tibial post fracture

Posterior stabilizing knee prostheses have been increasing in popularity recently due to some studies showing excellent long-term survivorship, more consistent kinematics, technical ease, and higher range of motion.[1,2] The posterior stabilized knee relies on a cam and post mechanism to replicate native femoral rollback. One of the major potential complications of this system is post fracture. This occurs in less than 1% of most total knees.[3] These patients usually present with a history of a "pop," effusion, and instability. Diagnosis is usually made clinically or by arthroscopic evaluation. Treatment is typically with a polyethylene liner exchange.[4]

Case Report

A 45-year-old white male patient presented with left knee osteoarthritis. He presented with a 10-degree varus deformity of his left knee and range of motion was from full extension to 110 degrees of flexion. He also had an incompetent anterior cruciate ligament and posterior cruciate ligament by physical examination. He failed treatment with anti-inflammatories, physical therapy, and injections. Due to the pain and resulting physical disability, the patient underwent a left total knee arthroplasty using a Genesis II total knee system (Smith and Nephew; Memphis, TN). A size 7 Oxinium (Smith and Nephew) femoral component, size 6 tibial component, 38 mm patella button, and 13 mm high flexion posterior stabilized polyethylene insert were used. Intraoperatively, the patient was found to have good stability to varus/valgus as well as anterior/posterior testing. The patella tracked well and there were no signs of midflexion instability. Range of motion intraoperatively was full extension to 120 degrees of flexion. The surgery went without complication, and the patient did well in the postoperative period. Approximately 4 years later, the patient felt pain in the left knee while completing personal resistance squats at the gym. He continued to experience multiple episodes of his knee locking up with continuing pain. Physical examination showed increased posterior sag and laxity with evidence of midflexion instability. X-rays did not show any signs of loosening of any components or signs of instability (►**Fig. 1A, B**). Based on the clinical findings and the patient's symptoms, he was taken back to the operating room for open exploration and possible revision.

The patient's previous midline incision and medial parapatellar arthrotomy were utilized. Immediately upon exposing the joint, the fractured post was found sitting anterior to the polyethylene insert and tibial component (►**Fig. 2**). The femoral, tibial, and patellar components were inspected and found to be stable and well fixed. The insert was then

received
April 14, 2014
accepted after revision
April 12, 2015
published online
September 1, 2015

DOI http://dx.doi.org/10.1055/s-0035-1555014.
ISSN 2326-2729.

Copyright © 2015 by Thieme Medical Publishers, Inc., 333 Seventh Avenue, New York, NY 10001, USA. Tel: +1(212) 584-4662.

License terms

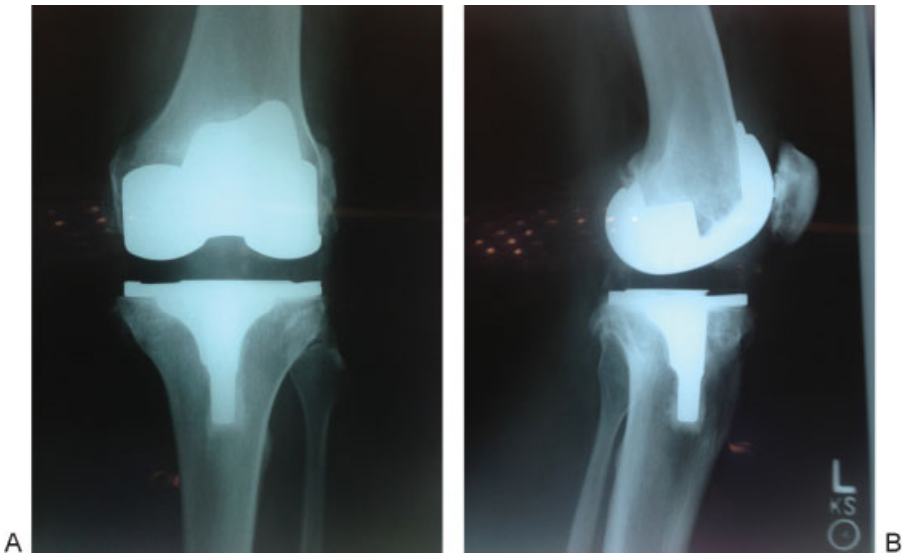

Fig. 1 (A) Anteroposterior radiograph of knee after injury. (B) Lateral radiograph of knee after injury.

removed from the knee and examined. There were no signs of significant wear along the medial or lateral compartments. The post also showed no signs of increased wear (►**Fig. 3A, B**) A size 18 posterior stabilized polyethylene insert was then inserted into the knee (►**Fig. 4**). The knee was examined for varus/valgus, anterior/posterior, and midflexion stability and was found to be stable. Patellar tracking was midline. At follow-up, patient was doing well with significantly improved pain and function of his left knee (►**Fig. 5A, B**).

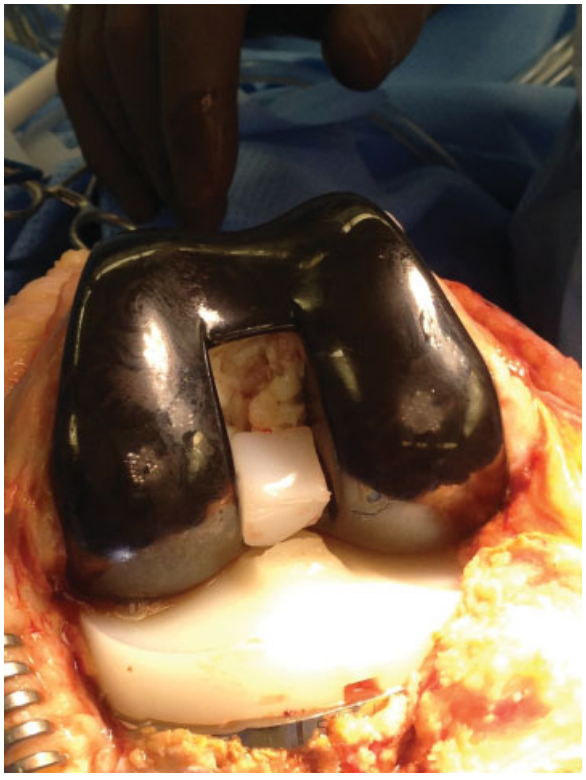

Fig. 2 Photograph of fractured polyethylene tibial post discovered during surgical exposure.

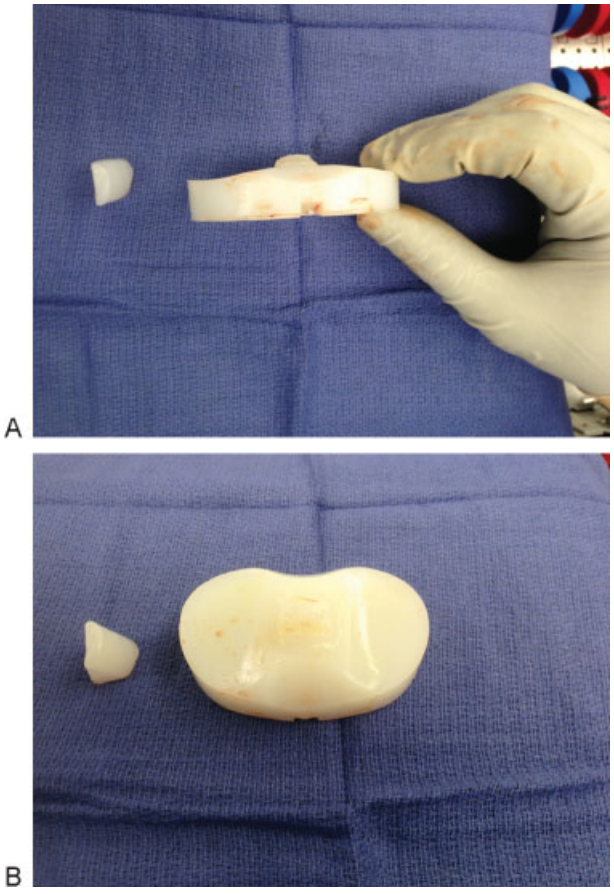

Fig. 3 (A) Anterior aspect of the polyethylene insert showing the post fracture. (B) Superior view of the polyethylene insert with fractured post.

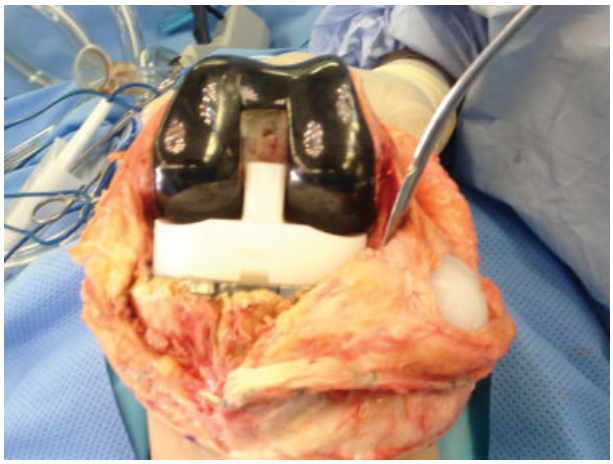

Fig. 4 Photograph of knee after polyethylene exchange.

Discussion

Posterior stabilized knee prostheses have the design feature of a cam and post to replicate native kinematics. The cam engages the post during flexion and results in femoral rollback. However, this mechanism increases the potential for higher wear and failure especially in the setting of anterior post impingement. This can be the result of placing the femoral component in flexion, cutting the tibia with increased posterior slope, knee hyperextension, posterior placement of the femoral component, or anterior tibial tray placement.[3] The post is also at risk with deep flexion as this can place significant shear stress across the post.[5] Multiple reports of post fracture have been published, and anterior impingement and deep flexion mechanisms have been consistently described.[4–9]

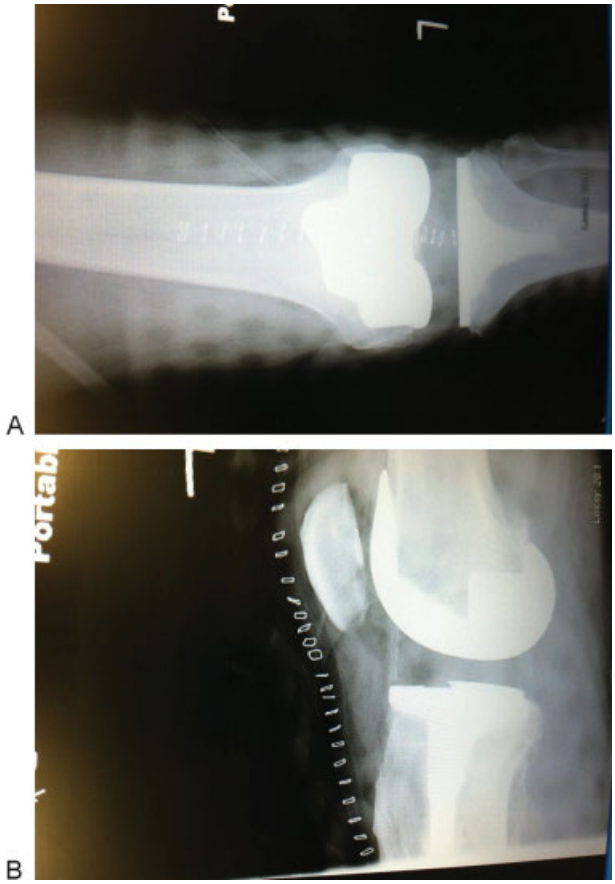

Fig. 5 (A) Anteroposterior radiograph after revision surgery. (B) Lateral radiograph after revision surgery.

Our patient is an active individual who is employed in a management position for a commercial management company. He had a regular workout routine approximately three or four times per week involving personal resistance squats and other lower extremity strengthening exercises such as knee extensions and calf exercises utilizing light weights. The implant failure occurred while he was at the gym performing squats. This is consistent with other reports in the literature of failure due to high flexion mechanisms.[7] Before the injury, the patient's knee was stable to all clinical testing, and components were in good position radiographically. Examination of the polyethylene tibial post intraoperatively showed no signs of significant wear due to post impingement. Failure of the post in this case appears to be due to its inability to sustain the shear forces placed across it during squat exercises. Although there have been described failures due to high flexion injuries, our patient's active lifestyle mechanism is unique to the literature. Total joints are being performed in increasingly younger and more active patients due to the improving technology and surgical techniques. It is imperative to determine what the limitations of these implants are in the younger and more active population.

There have been examples of post failure in numerous types of total knee prostheses (Scorpio, Stryker, Mahwah, NJ; Insall Bursein II, Zimmer, Swindon, UK; NexGen, Zimmer, Warsaw, IN; Genesis, Smith & Nephew, Memphis, TN; PFC, DePuy Synthes, Warsaw, IN; and PFC Sigma Knee System (Johnson & Johnson, New Brunswick, NJ; etc).

References

1 Maruyama S, Yoshiya S, Matsui N, Kuroda R, Kurosaka M. Functional comparison of posterior cruciate-retaining versus posterior stabilized total knee arthroplasty. J Arthroplasty 2004;19(3): 349–353
2 Morgan H, Battista V, Leopold SS. Constraint in primary total knee arthroplasty. J Am Acad Orthop Surg 2005;13(8): 515–524
3 Callaghan JJ, O'Rourke MR, Goetz DD, Schmalzried TP, Campbell PA, Johnston RC. Tibial post impingement in posterior-stabilized total knee arthroplasty. Clin Orthop Relat Res 2002;(404): 83–88
4 Lachiewicz PF. How to treat a tibial post fracture in total knee arthroplasty? A systematic review. Clin Orthop Relat Res 2011; 469(6):1709–1715
5 Jung KA, Lee SC, Hwang SH, Kim SM. Fractured polyethylene tibial post in a posterior-stabilized knee prosthesis presenting as a floating palpable mass. J Knee Surg 2009;22(4): 374–376

6 Chiu YS, Chen WM, Huang CK, Chiang CC, Chen TH. Fracture of the polyethylene tibial post in a NexGen posterior-stabilized knee prosthesis. J Arthroplasty 2004;19(8):1045–1049
7 Sands KC, Silver JW. Fracture of the polyethylene tibial post in a posterior stabilized PFC total knee arthroplasty. Orthopedics 2005;28(10):1203–1204
8 Lim HC, Bae JH, Hwang JH, Kim SJ, Yoon JY. Fracture of a polyethylene tibial post in a Scorpio posterior-stabilized knee prosthesis. Clin Orthop Surg 2009;1(2):118–121
9 Mestha P, Shenava Y, D'Arcy JC. Fracture of the polyethylene tibial post in posterior stabilized (Insall Burstein II) total knee arthroplasty. J Arthroplasty 2000;15(6):814–815