

Diagnosing Cervical Spine Injury in Severe Head Injury: A Case for Replacing Plain Radiography With Computed Tomographic Scan of the Cervical Spine

Shanky Singh¹ Ravi Garg² Paramjit Singh³ Pravin Salunke² Sunil Gupta²

¹Department of General Surgery, Gian Sagar Medical College and Hospital, Banur, Punjab, India

²Department of Neurosurgery, Postgraduate Institute of Medical Education and Research, Chandigarh, Punjab, India

³Department of Radiodiagnosis, Postgraduate Institute of Medical Education and Research, Chandigarh, Punjab, India

Address for correspondence Dr. Ravi Garg, MCh (Neurosurgery), Department of Neurosurgery, Postgraduate Institute of Medical Education and Research, Chandigarh, Punjab 160012, India (e-mail: ravi_piseces@yahoo.co.in).

Indian J Neurotrauma 2015;12:35–40.

Abstract

Introduction The diagnosis and management of cervical spine injuries in head-injured patients is problematic due to an altered level of consciousness and the overall critical nature of their injuries. It is a routine practice in most of the hospitals to get plain radiography for detection of bony spinal injuries which can miss some cases of fractures and fracture dislocations. It is imperative not to miss a cervical spine injury in patients with severe head injury. The aim of our study was to find which modality offers the greatest accuracy as the initial diagnostic test among patients suspected of having sustained a cervical spine surgery following severe head injury: plain radiography or computed tomography (CT) of cervical spine.

Patients and Methods This is a prospective study conducted on patients with severe head injury. In this study, 50 patients with severe head injuries were investigated by both plain X-rays and CT scan of the cervical spine. In these patients, the level and type of cervical spine injury were compared between plain X-ray and CT scan.

Results Plain X-rays detected cervical spine injury in 20%, while CT scan demonstrated spinal injury in 26% of the patients. Four patients of cervical spine fracture missed by plain radiography were diagnosed by CT cervical spine. In one patient in whom plain radiography showed fracture-dislocation at C5–C6 level was found to have degenerative changes at that level. C6–C7 was the most common site of fracture-dislocation (40.0%) followed by C5–C6 (20.0%), C4–C5 (20.0%), and C3–C4 (10.0%). C2 is the most common site of fracture diagnosed by CT scan which was missed by plain radiograph.

Conclusion It was concluded that it would be prudent to replace the practice of routine plain radiography with routine use of CT scans for detection of spinal bony injuries.

Keywords

- ▶ severe head injury
- ▶ cervical spine injury
- ▶ CT scan

Introduction

Cervical spine injury (CSI) occurs in approximately 2.4 to 4% of severe head injury patients.^{1,2} A missed CSI can be

devastating to the patient because of the magnitude of disability that can follow; also the costs to the provider can be enormous, particularly if the patient suffers long-term neurological impairment. Clearly, timely and accurate

received

October 12, 2014

accepted

December 8, 2014

published online

June 11, 2015

© 2015 Neurotrauma Society of India

DOI <http://dx.doi.org/>

10.1055/s-0035-1554995.

ISSN 0973-0508.

diagnosis of CSI is essential for optimal management of trauma patients.² Traditionally, the standard radiographic investigation in patients with suspected CSI is plain radiography. However, several studies^{3–12} have shown that plain radiography can frequently miss CSI with potentially devastating consequences. This has led some researchers to recommend the use of computed tomography (CT) with plain radiography as the initial imaging method for patients with suspected CSI.^{4,6,7} Failure to recognize unstable cervical injuries during initial evaluation can result in serious neurological worsening. Increased neurological deficits have been reported to occur in 3 to 10% of patients with spinal cord injury after arriving at the hospital.¹² The present study was conducted as a preliminary study to assess the basis for replacing routine cervical spine plain radiography with CT scan of the cervical spine.

Patients and Methods

A prospective nonrandomized study was carried out in the emergency trauma services at our hospital. Patients of severe head injury from January 1, 2011, to December 31, 2011, were studied. Patients of both the sexes and >18 and <65 years of age were included in the study.

Inclusion Criteria

1. Head injury patients with Glasgow coma scale (GCS) score <8.
2. Hemodynamically stable patients.

Exclusion Criteria

1. Head injury associated with obvious major vascular injury (i.e., external hemorrhage, pulseless extremity).
2. Head injury associated with burns, drowning, hanging, and lightning injuries.
3. Head injury associated with thoracolumbar spine injuries.

All patients with head injury were evaluated thoroughly in accordance with the standard practice, which included thorough history taking, general examination, systemic examination including detailed neurological examination, appropriate lab investigations, and imaging studies. On receiving, the patients were resuscitated and evaluated for the severity of injury. Based upon the clinical assessment, head injury were classified into mild, moderate, and severe according to GCS. A total of 50 patients of severe head injury

were studied. In all these patients assessment of neurological status and limb function and power was done. Plain radiography and CT scan of cervical spine were done in addition to CT scan of head.

Plain radiography included digital radiographs and the following views:

1. Antero posterior view
2. Lateral view

Shoulders were pulled down for adequate exposure.

CT scan included the following:

1. Noncontrast (NC) CT head
2. NCCT spine

CT scan was done under MultiDetector 16-slice CT scan machine with 5-mm cuts, which included axial view of cervical spine from occiput to T1 spine with coronal and sagittal three-dimensional reconstruction.

X-ray and CT scan findings were noted. Plain radiography findings were evaluated as follows:

1. Presence or absence of cervical spine fractures.
2. Level of spine fractures from occiput to T1 spine.

CT scan findings were evaluated as follows:

1. Presence or absence of cervical spine fractures.
2. Level of spine fractures from occiput to T1 spine.

In our study, the radiologists reporting were blinded while reviewing X-ray and CT scan of the same patient to avoid bias while reporting.

Results

In our study group of 50 patients, plain radiography was able to diagnose cervical spine fracture in 10 patients while NCCT spine was able to diagnose in 13 patients. Out of 50 patients included in this study, there were 38 males with the mean age of 38 years (range: 25–60 years). The two major causes of injury in our study were road traffic accidents (34 patients) and fall from height (16 patients) (►Table 1). The most common fracture found on plain radiography in our study was fracture dislocation (nine patients) followed by wedge fracture which was found in one patient. C6–C7 was the most common site of fracture dislocation (four patients) followed by C5–C6 (two patients), C4–C5 (two patients), and C3–C4 (one patient). The most common fracture/

Table 1 Demographic profile of patients

Patients with severe head injury	No.	Mode of injury		Mean age (y)	Sex		CT head		
		RSA	Fall		M	F	Intracerebral hematoma	Diffuse axonal injury	Normal
Spine injury	13	7	6	37.54	9	4	2	—	11
No spine injury	37	27	10	39.21	29	8	20	1	16
Total	50	34	16	—	38	12	22	1	27

Abbreviations: F, females; M, males.

dislocation site identified by NCCT in our study group was at C6–C7 level (four patients) followed by C4–C5 level (two patients) (►Table 2). In one patient plain radiography showed findings of cervical spine fracture which was later found to be a degenerative change on NCCT cervical spine (►Figs. 1–4).

Out of the 13 patients in with CSI, NCCT head revealed EDH in one patient, contusion in one patient, and was normal/diffuse axonal injury in remaining 11 patients.

The plain radiography showed a sensitivity and specificity of 69.23 and 97.30%, respectively, with a false-positive and negative rate of 2.70 and 30.77%, respectively, for diagnosing CSI in severe head injury. It had a positive predictive value of 90% and negative predictive value of 10% in our study.

McNemar–Bowker test was used in our study for statistical analysis of plain radiography and NCCT cervical spine for diagnosing CSI in severe head injury. It was highly significant with *p*-value of 0.046 indicating significant improvement in diagnosing CSI in severe head injury patients with NCCT cervical spine along with plain radiography.

Discussion

Severe head injury association with CSI is a known fact. Individuals who sustain traumatic brain injury are at an increased risk of sustaining CSI compared with victims of nonhead-related blunt trauma injury.^{13,14} One of the most challenging and controversial issues facing emergency physicians and traumatologists today is the accurate and timely evaluation of the cervical spine in severe head injury patients. Diagnosis and management of CSIs in head-injured patients is problematic due to an altered level of consciousness and the overall critical nature of their injuries. Despite advances in imaging technologies and screening protocols, CSI may go undetected even in optimum circumstances.

Failure to recognize unstable cervical injuries during initial evaluation can result in serious neurological

worsening. The imaging modality of choice to diagnose CSI in those with head injury is currently an area of debate.

An increasing injury severity, as measured by the GCS, has been associated with a higher rate of cervical injury.^{13,14} Hills and Deanne¹³ and Williams et al,¹⁴ have shown an association between GCS score-related head injury severity and the risk of concomitant cervical injury. In their report of almost 8,300 trauma victims, they had shown that head-injured patients had a significantly higher risk of cervical spine injury (4.5%) than those without a head injury. Patients in our study group with spine injury had different GCS ranging from 3 to 8 with mean GCS of 6. Risk of bony cervical injury more than doubles for those with a GCS score ≤ 8 and the risk of spinal cord damage increases fivefold.^{15,16} Due to an altered level of consciousness and the overall critical nature of the spine injury in severe head injury their diagnosis is problematic. Three patients out of 13 patients showed some focal neurological deficit and there were 2 patients who showed abnormal respiratory movements. Failure to diagnose a CSI at the time of presentation can have disastrous consequences, with a risk for neurological deterioration in up to 67% of the patients.¹⁶ Increased neurological deficits have been reported to occur in 3 to 10% in patients with SCI after arriving at the hospital in various studies.¹³

The optimal approach to cervical spine imaging for those with blunt trauma is currently an area of ongoing debate. Most of the practitioners agree that, of those patients who are determined to need radiological imaging, the minimum acceptable standard of care is a two-view cervical spine series, consisting of AP, and lateral views (with swimmer view if necessary to visualize the C7/T1 junction). This is based, at least in part, on the findings of Woodring and Lee,¹⁷ who, noted that close to 15% of injuries would be missed by utilization of a single lateral view alone. More recently, however, the adequacy of a two-view X-ray series has been challenged, with evidence of missed injuries in up to 57% in high-risk patients and 7 to 35% in the overall patients.^{10,17–21} There were 4 patients out of 50 patients (8.0%) in our study group in whom initial plain radiography

Table 2 Level of injury in X-ray and NCCT cervical spine

Fracture level	X-ray		NCCT	
	Frequency	Percent	Frequency	Percent
C2	0	00	1	7.7
C3–C4	1	10	1	7.7
C4–C5	2	20	2	15.4
C5	1	10	2	15.4
C5–C6	2	20	1	7.7
C6–C7	4	40	4	30.8
C7-T1	0	00	1	7.7
C2+C6–C7	0	00	1	7.7
Total	10	100	13	100.0

Abbreviation: NCCT, noncontrast computed tomography.

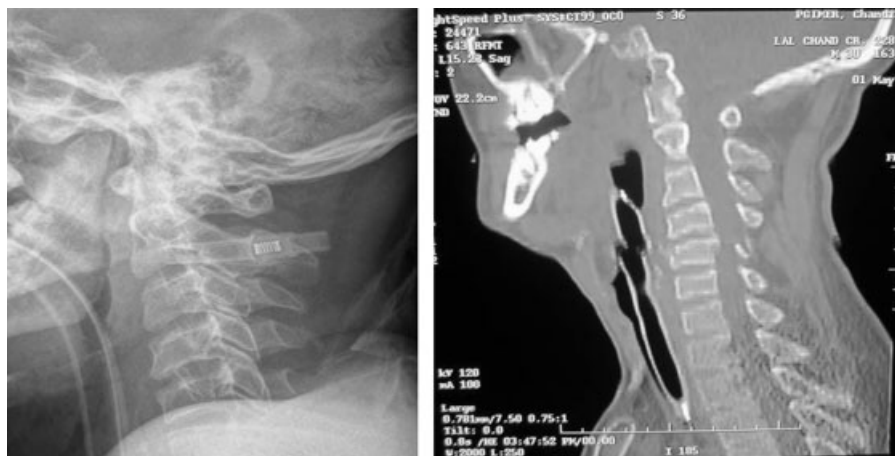


Fig. 1 Fracture body of C5 vertebra, which was missed on plain X-ray but detected on CT scan (JPG, 960–720 pixels). CT, computed tomography.

missed CSIs, which was later on diagnosed on NCCT spine. CT has been introduced by several authors as an adjunct to radiography in the setting of cervical spine trauma. Ross et al²² have proposed the use of limited CT to image the portions of the spine that are inadequately shown by radiography because examinations with negative findings were significantly more likely to be true-negative when CT was added to radiography. Blacksia and Lee²³ reported an 8% frequency of fractures of the craniocervical junction detected with CT that were not detected with radiography. Link et al²⁴ performed routine limited CT evaluation of the cervicocranium in patients with severe head trauma and found a significant number of occipital condyle and C1 and C2 fractures that were not seen on radiographs. Ball and Watson²⁵ have also shown that cervicothoracic junction is often obscured by shoulder girdle. In our study group also, there were two patients in whom initial plain radiography missed C2 fractures, which were later diagnosed on NCCT cervical spine. Also, in the present study C5–6 and C7–T1 fracture dislocation and C5 chip fracture were initially missed in plain radiography in one patient each, which was later on diagnosed on NCCT cervical spine.

In addition, the two-view series can be difficult to obtain, with reports of inadequate visualization in 50 to 80% of initial and 25% of repeat radiographs, necessitating more extensive study for cervical spine clearance.^{12,16}

Beyond this, other studies have shown plain films to have a high false-positive rate (between 18 and 63%), especially when used in elderly patients and those with degenerative osteoarthritis, leading to liberal use of cervical spine immobilization, which is not without consequence, however, and in addition to general comfort issues, it may lead to complications such as increased intracranial pressure for those with closed head injury, predisposition to pressure sore development, and ventilator-associated pneumonias.¹⁶ In our study group, one patient who was initially diagnosed as having cervical spine fracture were later confirmed as having degenerative changes on NCCT cervical spine with a false-positive rate of 2.7%. It is clear, therefore, that plain films are limited in their ability to reliably detect acute CSIs, particularly in those individuals with anatomical variants, often necessitating further imaging studies.

The failure of plain films to correctly identify injuries is a major problem which may not be limited to subtle

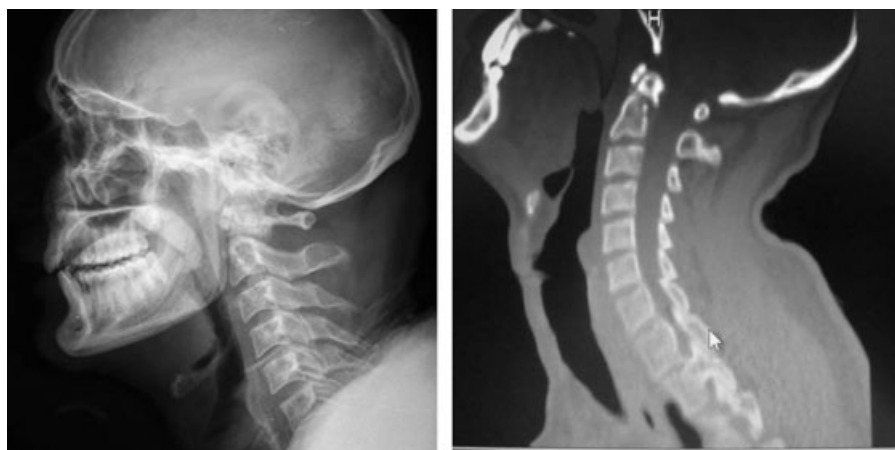


Fig. 2 Fractured odontoid process of C2 clearly visible only in CT scan (JPG, 960–720 pixels). CT, computed tomography.

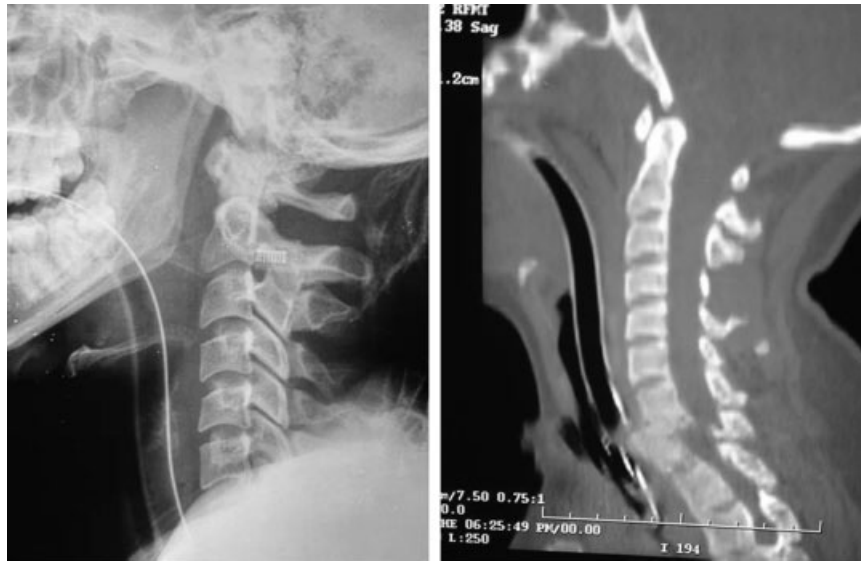

Fig. 3 Fracture dislocation C7/T1 which was obscured by the overlapping shoulder on plain radiograph was detected on CT scan (JPG, 960–720 pixels). CT, computed tomography.

abnormalities, with one study reporting that 31.7% of their missed cervical fractures were unstable, with need for surgical intervention.⁶ In our study, 50.0% of missed cervical spine fractures were unstable. There have also been several recent studies showing that helical CT can effectively delineate fractures not demonstrated by plain radiography, leading some authors to suggest that CT should be the imaging modality of choice, replacing plain films in the initial evaluation of suspected CSIs in the polytrauma patient.^{2,5,6,12,24}

Existing comparative trials are heterogeneous, but provide strong general evidence of the superiority of CT imaging over three-view plain films, with demonstrated sensitivities ranging from 97.4 to 100% versus 39 to 44%, respectively.^{5,6,12,24,26} These pooled results are similar to data from a recent meta-analysis that excluded many methodologically inferior studies and found an overall

sensitivity of 98% (95% confidence interval [CI]) for CT versus 52% (95% CI 47–56%) for plain films.²⁷ In the present study, plain radiography had a sensitivity and specificity of 69.23 and 97.30%, respectively. The purpose of this study was to determine the role of plain cervical spine films and CT films in severe head injury patients. It is proposed that in patients with severe head injury it would be better to subject patients to CT of cervical spine rather than plain X-ray. CT of spine can be performed in the same settings when patients are undergoing CT head for head injury. This would result in reducing the chance of missing a potentially catastrophic CSI as well as avoiding unnecessary time spent and additional patient maneuvering to get optimal cervical spine X-ray. It also illustrates the limitations of plain cervical radiographs in imaging the upper cervical spine due to difficulty owing to positioning problems and superimposed nasogastric and endotracheal tubes. Also,

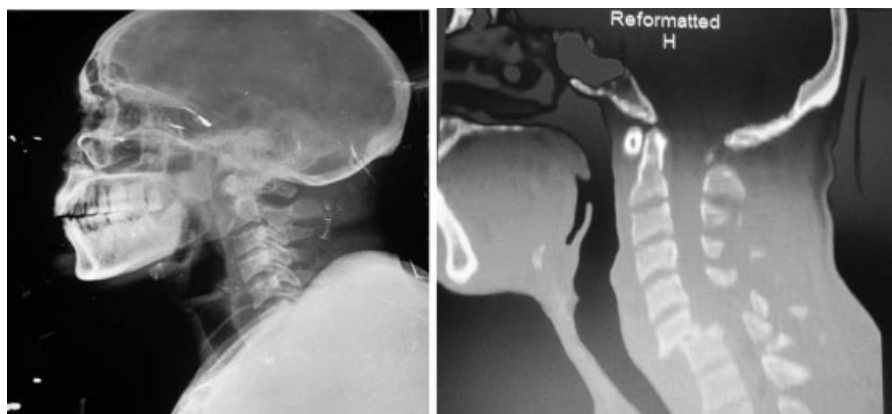


Fig. 4 Fracture dislocation C5/C6 and a break in the posterior cortical margin of C2 body demonstrable in CT spine (JPG, 960–720 pixels). CT, computed tomography.

the cervicothoracic junction is often obscured by the shoulder girdle.²⁵ In such cases, careful thought should be given to ordering plain films before CT, as some patients who clearly required CT of the cervical spine may undergo unnecessary lateral plain films in the emergency department, delaying their progression to definitive care.

Conclusion

The study highlights that there is a significant improvement in diagnosing CSI in severe head injury patients with NCCT cervical spine. Patients with occult C1–C2 fractures have the best outcome by doing NCCT cervical spine in head injury patients. Also, plain radiography does not provide any additional information. So, CT of cervical spine should be the modality of choice for detection of CSIs in severe head injury patients.

Conflict of Interest

The authors have nothing to declare.

References

- Grossman MD, Reilly PM, Gillett T, et al. National survey of the incidence of cervical spine injury and approaches to cervical spine clearance in U.S. trauma centres. *J Trauma* 1999; 47:684–690
- Mower WR, Hoffman JR, Pollack CV, et al. Use of plain radiography to screen for cervical spine injuries. *Ann Emerg Med* 2001;38:1–7
- Berne JD, Velmahos GC, Tawil QE, et al. Value of complete cervical helical computed tomographic scanning in identifying cervical spine injury in the unevaluable blunt trauma patient with multiple injuries: a prospective study. *J Trauma* 1999;47:896–902
- Daffner RH, Sciulli RL, Rodriguez A, et al. Evaluation of suspected cervical spine trauma: a 2-year analysis. *Injury* 2006;37:652–658
- Diaz JJ, Gillman C, Morris JA, et al. Are five-view plain films of the cervical spine unreliable? A prospective evaluation in blunt trauma patients with altered mental status. *J Trauma* 2003;55:658–664
- Griffen MM, Frykberg ER, Kerwin AJ, et al. Radiographic clearance of blunt cervical spine injury: plain radiograph or computed tomography scan? *J Trauma* 2003;55:222–226
- Mathen R, Inaba K, Munera F, et al. Prospective evaluation of multislice computed tomography versus plain radiographic cervical spine clearance in trauma patients. *J Trauma* 2007; 62:1427–1431
- McCulloch PT, France J, Jones DL, et al. Helical computed tomography alone compared with plain radiographs with adjunct computed tomography to evaluate the cervical spine after high-energy trauma. *J Bone Joint Surg Am* 2005;87:2388–2394
- Nguyen GK, Clark R. Adequacy of plain radiography in the diagnosis of cervical spine injuries. *Emerg Radiol* 2005; 11:158–161
- Núñez DB, Zuluaga A, Fuentes-Bernardo DA, et al. How much do we learn by routinely using helical CT? *Radiographics* 1996; 16:1307–1318
- Sharma OP, Oswanski MF, Yazdi JS, et al. Assessment for additional spinal trauma in patients with cervical spine injury. *Am Surg* 2007;73:70–74
- Widder S, Doig C, Burrowes P, et al. Prospective evaluation of computed tomographic scanning for the spinal clearance of obtunded trauma patients: preliminary results. *J Trauma* 2004; 56:1179–1184
- Hills MM, Deanne SA. Head injury and facial injury: is there an increased risk of cervical spine injury? *J Trauma* 1993; 34:549–554
- Williams J, Jehle D, Cottingham E, et al. Head, facial and clavicular trauma as a predictor of cervical spine injury. *Ann Emerg Med* 1992;21:719–722
- Holly LT, Kelly DF, Counelis GJ, et al. Cervical spine trauma associated with moderate and severe head injury: incidence, risk factors, and injury characteristics. *J Neurosurg* 2002; 96:285–291
- Morris CG, McCoy E. Clearing the cervical spine in unconscious polytrauma victims, balancing risks and effective screening. *Anaesthesia* 2004;59:464–482
- Woodring JH, Lee C. Limitations of cervical radiography in the evaluation of acute cervical trauma. *J Trauma* 1993;34:32–39
- Davis JW, Phreaner DL, Hoyt DB, et al. The etiology of missed cervical spine injuries. *J Trauma* 1993;34:342–346
- Gerrelts BD, Petersen EU, Mabry J, et al. Delayed diagnosis of cervical spine injuries. *J Trauma* 1991;31:1622–1626
- Reid DC, Henderson R, Saboe L, et al. Etiology and clinical course of missed spine fractures. *J Trauma* 1987;27:980–986
- West OC, Anbari MM, Pilgram TK, et al. Acute cervical spine trauma: diagnostic performance of single view versus three-view radiographic screening. *Radiology* 1997;204:819–823
- Ross SE, Schwab CW, David EI, et al. Clearing the cervical spine: initial radiologic evaluation. *J Trauma* 1987;27:1055–1060
- Blacksin MF, Lee HJ. Frequency and significance of fractures of the upper cervical spine detected by CT in patients with severe neck trauma. *Am J Roentgenol* 1995;165:1201–1204
- Link TM, Schuierer G, Horch C, et al. Substantial head trauma: value of routine CT examination of the cervicocranium. *Radiology* 1995;196:741–745
- Ball C, Watson DA. 12 month clinical audit of cervical spine imaging in multiply injured and intubated patients. *Br J Radiol* 2010;83:257–260
- Acheson MB, Livingston RR, Richardson ML, et al. High-resolution CT scanning in the evaluation of cervical spine fractures: comparison with plain film examinations. *Am J Roentgenol* 1987;148:1179–1185
- Holmes JF, Akkinpalli R. Computed tomography versus plain radiography to screen for cervical spine injury: a meta-analysis. *J Trauma* 2005;58:902–905