

Intradiurnal Fluctuations of Off-Resonance Saturation Effects in Healthy Human Achilles Tendons Assessed with a 3D Ultrashort Echo Time MRI Sequence at 3 Tesla

Tageszeitabhängige Schwankungen von Magnetisierungstransfer- (MT-) Effekten in Achillessehnen von gesunden Probanden: Quantitative Auswertung mittels einer 3D-Ultrashort-echo-time Sequenz bei 3T

Authors

U. Grosse¹, R. Syha¹, S. Partovi², D. E. Keßler¹, M. Bongers¹, F. Seith¹, K. Nikolaou¹, M. Robbin², F. Schick³, F. Springer¹

Affiliations

¹ Department of Diagnostic and Interventional Radiology, University Hospital Tuebingen, Germany

² Department of Radiology, University Hospitals Case Medical Center, Case Western Reserve University, Cleveland, Germany

³ Section on Experimental Radiology, Department of Diagnostic and Interventional Radiology, University Hospital Tuebingen, Germany

Key words

- tendons
- MR imaging
- tissue characterization

Zusammenfassung



Ziel: In dieser Studie an gesunden Probanden sollen die Auswirkungen des orthostatischen Ödems durch reduzierte körperliche Aktivität auf intratendinöse Magnetisierungstransfer- (MT-) Effekte (oder allgemeiner Off-Resonanz-Sättigungs-Ratios („OSR“)) und das Volumen der Achillessehne untersucht werden.

Material und Methoden: Sieben gesunde Probanden wurden an drei aufeinander folgenden Tagen jeweils morgens und abends mittels einer 3D-Ultrashort-echo-time (UTE) Sequenz mit 2000 Hz Off-Resonanz-Sättigungspulsen zur Kalkulation von OSR-Werten an einem 3 T Ganzkörper-MRT untersucht. Für eine möglichst exakte Volumenquantifizierung der Achillessehne in hochaufgelösten isotropen T2-SPACE Sequenzen kam ein neu entwickelter „Snake“-Konturerkennungsalgorithmus zum Einsatz. Zusätzlich wurden Einzelmessungs-Intraklassen-Korrelationskoeffizienten (engl. ICC) als quantitatives Reliabilitätsmaß zur Abschätzung der Test-Retest-Reliabilität berechnet.

Ergebnisse: Sowohl für die OSR-Werte als auch das Sehnenvolumen konnte eine exzellente Reproduzierbarkeit mit ICC-Werten größer 0,96 bzw. 0,97 über die drei untersuchten aufeinander folgenden Messtage gezeigt werden. Bei der Betrachtung aller Messzeitpunkte wurde eine statistisch signifikante Abnahme der intratendinösen OSR-Werte ($-4,1 \pm 1,5\%$; $p=0,001$) am Abend gefunden, während das ermittelte Sehnenvolumen hier keine signifikante Änderung zeigte ($p=0,589$).

Schlussfolgerung: Die Ergebnisse dieser in-vivo Studie zeigen einen messbaren Einfluss des orthostatischen Ödems durch reduzierte körperliche Aktivität auf intratendinöse OSR-Werte aber nicht das Sehnenvolumen. Zusammen mit der aufgezeigten exzellenten Reproduzierbarkeit sind diese Ergebnisse besonders für zukünftige Longitudinalstudien und die Untersuchung von zeitlichen Veränderungen der tendinösen Mikrostruktur von Bedeutung.

Abstract



Purpose: The purpose of this study was to evaluate whether gravitational interstitial fluid accumulation in healthy subjects has an impact on off-resonance saturation ratios (OSR) or the volume of the Achilles tendon after a prolonged time of reduced levels of physical activity.

Materials and Methods: 7 healthy volunteers were repeatedly investigated on 3 consecutive days on a 3 T whole body MR scanner using an ultrashort echo time (UTE) imaging sequence with a Gaussian off-resonance saturation pulse at a frequency offset of 2000 Hz to calculate OSR values. For accurate volumetric quantification of the Achilles tendon, a newly developed contour detection snake algorithm was applied on high-resolution isotropic T2-weighted SPACE sequence datasets. Single-measure intraclass correlation coefficients (ICC) were calculated to estimate test-retest reliability.

Results: For OSR and tendon volume measurements on three consecutive days, excellent reproducibility could be achieved with ICC values above 0.96 and 0.97, respectively. Comparing the results of all three days, a statistically significant mean individual percentage decrease ($-4.1 \pm 1.5\%$; $p=0.001$) of calculated tendon OSR values was found for the evening measurements. No statistically significant difference between tendon volumes in the morning and the evening could be detected ($p=0.589$).

Conclusion: The results of this in-vivo study demonstrate a significant influence of gravitational interstitial fluid accumulation after reduced physical activity on OSR values in the Achilles tendon, but not on tendon volume. Taken together with the demonstrated excellent reproducibility, these findings are important for future studies investigating temporal changes of the Achilles tendon microstructure.

received 13.2.2015
accepted 11.5.2015

Bibliography

DOI <http://dx.doi.org/10.1055/s-0035-1553187>
Published online: 19.6.2015
Fortschr Röntgenstr 2015; 187: 1003–1010 © Georg Thieme Verlag KG Stuttgart · New York · ISSN 1438-9029

Correspondence

Herr Dr. Roland Syha

Department of Diagnostic and Interventional Radiology, University Hospital Tuebingen
Hoppe-Seyley-Strasse 3
72076 Tuebingen
Germany
Tel.: ++ 49/70 71/298 73 76
Fax: ++ 49/70 71/29 44 78
roland.syha@med.uni-tuebingen.de

Kernaussagen:

- ▶ Messungen des Sehnenvolumens und der intratendinösen OSR-Werte zeigten im kurzfristigen täglichen Verlauf eine sehr gute Reproduzierbarkeit.
- ▶ Das orthostatische Ödem der unteren Extremität ist wahrscheinlich teilweise für die in früheren Studien festgestellten Messwertschwankungen von intratendinösen OSR-Werten in gesunden Sehnen verantwortlich.
- ▶ Physiologische Flüssigkeitsverschiebungen an der unteren Extremität können sogar in gesunden Probanden hochsensible quantitative MR-Messmethoden (wie zum Beispiel in dieser Studie benutzte OSR-Werte) beeinflussen.

Key Points:

- ▶ Tendon volume measurements and intratendinous OSR-values demonstrated a high day-to-day reproducibility.
- ▶ Gravitational fluid shifts might partly explain the known variation of OSR- measurements in healthy tendons.
- ▶ Physiological interstitial fluid shifts of the lower extremity can influence highly sensitive quantitative MR-parameters (as for example in this study used OSR-measurements) even in healthy individuals.

Citation Format:

- ▶ Grosse U., Syha R., Partovi S. et al. Intradivertual Fluctuations of Off-Resonance Saturation Effects in Healthy Human Achilles Tendons Assessed with a 3D Ultrashort Echo Time MRI Sequence at 3 Tesla. *Fortschr Röntgenstr* 2015; 187: 1003–1010

Introduction

Chronic degenerative alteration of the tendon structure (tendinopathy) is a main risk factor for tendon rupture and responsible for marked morbidity, both in physically active and sedentary populations [1–3].

Due to a better understanding of the pathogenesis of tendinopathy, recent research in magnetic resonance (MR) as well as ultrasound imaging has focused on quantitative and semi-quantitative assessment of healthy tendon structures in comparison to early-stage tendon disorders before subsequent partial or complete tendon tears in more advanced stages of tendon disorders occur [4–9]. In this context, various MR specific parameters (namely longitudinal relaxation time (T1), mono- or multi-exponential analysis of transverse relaxation times (T2*), magnetization transfer (MT) effects or the previously described more generic “off-resonance saturation ratios” (OSR)) have been used in vivo as well as ex vivo to quantitatively evaluate healthy Achilles tendons as well as early stages of tendinopathic tendons [5, 7–15]. T2* and particularly OSR values have proven to be highly sensitive to detect early pathological alterations of the tendon structure, being characterized by an increase of free water protons and breakdown of the highly organized macromolecular content [14]. It is well known that even in healthy subjects (with a fully functional phlebo-lymphatic apparatus), fluids and macromolecules accumulate in the phlebo-lymphatic sector as well as the interstitium after a prolonged time of standing or sitting [16, 17]. This gravitational interstitial fluid accumulation has the potential to influence highly sensitive and quantitative measures such as OSR or tendon volume.

Therefore, the aim of this study was to evaluate whether occupational leg swelling in healthy subjects has an impact on the calculated OSR values or the volume of the Achilles tendon after a prolonged time of reduced levels of physical activity.

Materials and Methods**Study Population and Inclusion/Exclusion Criteria**

The institutional review board approved the study and written informed consent was obtained from all healthy volunteers prior to enrollment. Seven healthy volunteers were enrolled in this study. Common exclusion criteria for MR examinations were applied to all participants, including ferromagnetic implants, pacemakers and claustrophobia. Further exclusion criteria were similar to previously conducted studies and included previous injuries or

operations at the ankle, any tendinopathic tendon alterations as well as partial or complete tears [5]. Prior to the start of the study, all participants were clinically examined and a dynamic ultrasound examination of both Achilles tendons was performed to solely exclude pathological tendon alterations (U. G., 4 years of experience in musculoskeletal ultrasound). Using a multi-D linear array transducer (Acuson Antares, VFX 13–5, Siemens Healthcare, Mountain View, CA), the Achilles tendon was evaluated with dynamic imaging and power Doppler ultrasound (standardized region of interest [ROI] settings: ROI 1.5 × 2.0 cm², focus 2 cm) in longitudinal and transverse orientation. The results of this ultrasound examination are not further evaluated in this article. Furthermore, common risk factors associated with Achilles tendon disorders (rheumatoid arthritis or gout, hypercholesterolemia treated with medication and use of fluoroquinolones in the past two years) were also regarded as exclusion criteria. In addition, subjects should neither suffer from clinically evident edema or varicose veins of the lower limb nor report a past medical history of deep venous thrombosis in the lower leg.

All participants refrained from ankle-loading physical activity for at least 72 hours prior to the examination and during the three days of the intradiurnal MR measurements. Participants were examined on three consecutive days in the morning at 7 a. m. before heading to work (specific care was taken that ankle-loading activity prior to the MR examination was kept to the lowest level possible) and at the end of a full working day at 6 p. m. All investigated subjects (resident physicians working in the department of radiology at conventional diagnostic workplaces) reported similarly reduced levels of physical activity during working time with a predominantly sedentary occupation.

Case Record Form (CRF) and Clinical Examination Protocol

Results of clinical examination, anthropometric data and past medical history of all participants were documented using a standardized case record form (CRF). In addition, the last performed physical activity as well as regular sports activities were documented and evaluated regarding their influence on the ankle joint using the ankle activity score (AAS).

MR Examination

The right Achilles tendon of all participants was examined using the posterior part of a 32-channel head coil (3T Siemens TIM Trio, Siemens Healthcare, Erlangen, Germany) for signal reception, while the body coil of the 3T whole-body scanner (Magne-

tom Trio, Siemens Healthcare, Erlangen, Germany) was used for RF transmission.

All subjects were positioned supine feet first on the examination table. Plantar flexion of the foot within the posterior part of the head coil was adjusted to 10°–15° and maintained throughout the examination by placing sand pads around the ankle. The total examination time was approximately 25 minutes.

Morphological MR imaging of the Achilles tendon included an axially oriented nearly PDw 3 D FSE sequence with an isotropic resolution of 0.8 mm (TR = 1200 ms, TE = 12 ms, FA = 120°, FOV = 192 × 192 mm², receiver bandwidth 545 Hz/pixel, number of averages: 1) and a sagittal T1w 2 D sequence with an in-plane resolution of 0.6 × 0.5 mm and a slice thickness of 3 mm (TR = 750 ms, TE = 12 ms, FA = 140°, number of averages = 1).

For quantification of tendon volume, an axially oriented T2w 3 D fast spin echo (FSE) sequence with an isotropic resolution of 0.8 mm (TR = 3200 ms, TE = 359 ms, FA = 120°, FOV = 192 × 192 mm², receiver bandwidth = 745 Hz/pixel, number of averages = 1) was used.

To quantify off-resonance saturation effects of the Achilles tendons, a 3 D ultrashort echo time (UTE) sequence with radial k-space sampling (FOV = 192 mm, isotropic spatial resolution = 1.0 mm, TR = 11 ms, TE = 0.07 ms, excitation flip angle = 12°; bandwidth = 2370 Hz/pixel) was applied. The minimal echo time (TE) was 0.07 ms (time interval between the center of the rectangular RF pulse and the time when central k-space data are recorded) and is given by the sum of half the RF pulse duration ($\frac{1}{2} T_{RF} = 0.05$ ms) and the switching time of the RF system from transmit to receive mode (0.02 ms). For analysis of the tendon signal reduction due to off-resonance saturation (leading to both magnetization transfer and direct saturation effects), a 5120 ms Gaussian-shaped saturation pulse, i. e. magnetization transfer (MT) pulse, was additionally applied prior to each excitation pulse at an off-resonance frequency of 2000 Hz up-field of the normal resonance frequency at 3 T (approximately 123 244 MHz). No parallel imaging techniques were used and further imaging parameters of the applied 3 D UTE sequence are given in **Table 1**.

Off-resonance saturation ratio (OSR) maps were calculated pixel-wise, similarly to the commonly used MT ratio with the “Image Calculator” plugin of the image processing software ImageJ (NIH, Bethesda, MD). This was done according to equation (1), where S_{SP} denotes the pixel intensity in an image acquired with an off-resonance saturation pulse at 2000 Hz, while S_0 represents the pixel intensity in an image acquired without a preparation pulse:

$$OSR = \frac{(S_0 - S_{SP})}{S_0}$$

Data Analysis

Before the pixelwise analysis, image data with and without off-resonance saturation pulse was motion-corrected with the realignment and re-slice tool of the MATLAB software package Statistical Parametric Mapping 8 (Matlab R2011b, The Mathworks inc., Natick, MA; SPM 8) using a least squares approach and a six parameter rigid-body spatial transformation with fourth degree B-spline interpolation.

Similar to previously performed studies, a quadratic noise correction (2) was applied on the measured signal intensities before data evaluation according to the following equation, where S_{corr} and S_{uncorr} represent the noise corrected and uncorrected signal intensity, respectively [18]:

$$S_{corr} = \sqrt{(S_{uncorr})^2 - (S_{noise})^2}$$

Table 1 Imaging parameters of the applied 3 D ultrashort echo time (UTE) sequence with MT preparation pulse at 2000 Hz off-resonance are listed.

Tab. 1 Parameter der 3D-ultrashort echo time (UTE) Sequenz mit MT-Präparationspuls von 2000 Hz Off-Resonanz.

parameters	values
echo time (TE)	0.07 ms
time of repetition (TR)	11 ms
field of view (FOV)	192 mm
resolution	1 mm isotropic
readout bandwidth	2370 Hz/pixel
projections	18 432
excitation flip angle	12°
excitation pulse duration	100 µs
MT pulse: Off-resonance frequency	2000 Hz
MT pulse: Duration	5120 µs
MT pulse: Flip angle	220°
acquisition time	3:23 min

S_{noise} represents the arithmetic mean of the noise background and was calculated from a region of interest (ROI) containing approximately 100 pixels in an object-free homogeneous area without any visible artifacts. It should be mentioned here that the noise level was uniform in all parts of MR images, since no parallel imaging techniques were applied.

In the resulting OSR maps, representative ROIs containing the whole tendon cross-sectional area were analyzed at the following locations: 0.5 cm (“caudal mid-portion area”, [CA]) and 3.0 cm above the most cranial part of the tuber calcanei (“cranial mid-portion area”, [CR], i. e. 5 to 6 cm cranial of the insertional area depending on tendon length). At each location, five consecutive slices were used to calculate the mean OSR values using ImageJ.

Multiplanar reconstructions (MPR) of the T2-weighted 3 D SPACE sequence with a slice thickness of 0.8 mm were used to assess the tendon volume of the Achilles tendon. An automated contour detection algorithm (AVAT), which was self-written using Matlab (Matlab 7.3.0, The Mathworks Inc., Natick, MA) and based on an established automatic procedure with an implemented snake algorithm (active contour model), was used to assess the volume of the Achilles tendon [mm³] [19, 20]. Measurements started from the cranial border of the calcaneal tuberosity and the fixed end point of the measurement in all volunteers was 3 cm proximal to the starting point (at the site of the cranial OSR measurement). Thus, the tendon volume measurement included the representative mid-portion of the tendon, which is mostly affected by tendon disorders. The starting point was set by an experienced radiologist (RS; 6 years of experience in musculoskeletal imaging). All further contour detection was subsequently performed automatically. Results of the automatic contour detection algorithm were visually approved and manually corrected as indicated.

Statistics

JMP 9.0.0 (SAS Institute Inc., Cary, NC) as well as SPSS (release 21 for Windows; SPSS, Chicago, IL) were used for statistical analysis. Arithmetic means (mean) as well as standard deviations (SD) were calculated for the OSR values of the two investigated tendon areas (CA, CR) as well as the tendon volume.

Single-measure intra-class correlation coefficients (ICC) and associated 95 % confidence intervals (CI) were calculated using a two-factor random effect model to estimate the test-retest reliability.

bility of OSR values and tendon volume in the morning and in the evening.

A repeated-measures univariate analysis of variance (ANOVA) was performed to test for a statistically significant influence of the time of measurement (morning or evening), tendon section (CR or CA) or measurement repetition on OSR values and tendon volume. Bonferroni correction was performed for multiple testing and a corrected p -value of $p < 0.05$ was considered significant.

Results

All seven participants (all male; age at examination: 30.4 ± 2.0 ; BMI $22.8 \pm 1.5 \text{ kg/m}^2$) did not report any episode of posterior heel pain in their past. Neither clinical examination nor dynamic ultrasound examination revealed any signs of an Achilles tendon disorder. Regular moderate physical activity of all participants resulted in an AAS score of 4.9 ± 0.9 . According to inclusion/exclusion criteria of this study, all participants reported no ankle loading physical activity in the last 72 hours prior to the examination and even physical activity of the last 7 days prior to the examination consisted of only low-ankle loading activities: cycling (4 cases), strength training (1 case) and hiking/walking (2 cases).

Measurement Reproducibility

Calculated ICC values of mean OSR values and tendon volume in the morning on three consecutive days showed following values:

- ▶ OSR values: 0.98 (CI: 0.94 – 0.99)
- ▶ Tendon volume: 0.99 (CI: 0.98 – 0.99)

ICC values of these parameters calculated for the evening measurements were minimally lower:

- ▶ OSR values: 0.96 (CI: 0.86 – 0.99)
- ▶ Tendon volume: 0.97 (CI: 0.91 – 0.99)

Intradiurnal Changes of OSR Values and Tendon Volume

Mean OSR values at 2000 Hz off-resonance were averaged over measurement time and tendon sections and showed the following values on three consecutive days: 0.29 ± 0.03 (day 1), 0.28 ± 0.03 (day 2) and 0.28 ± 0.02 (day 3).

A statistically significant influence on OSR measurements was found for measurement time ($p = 0.001$) and tendon section ($p = 0.040$), but not for measurement repetition ($p = 0.199$).

As shown in [Fig. 1](#) and [Table 2](#), all subjects presented lower OSR values in the evening compared to the ones derived from the morning measurement of the same day. Please note that in [Table 2](#) the mean OSR values with standard deviations at 2000 Hz off-resonance and tendon volumes measurements are averaged over all participants for each of the consecutive measurement days (morning and evening measurements).

The mean intra-individual percentage decrease [%] of the calculated tendon OSR was observed with the following values: $-3.6 \pm 1.4\%$ (day 1), $-3.6 \pm 2.2\%$ (day 2), and $-5.2 \pm 2.2\%$ (day 3). Averaged over all three days this represents a mean individual percentage decrease [%] of the calculated tendon OSR of $-4.1 \pm 1.5\%$. Representative transverse OSR maps acquired in the morning and in the evening of a 31-year-old male participant are shown in [Fig. 2](#).

The mean tendon volume averaged over the time of measurement (morning, evening) revealed the following values: $2376 \pm 373 \text{ mm}^3$ (day 1), $2360 \pm 339 \text{ mm}^3$ (day 2), and $2355 \pm 361 \text{ mm}^3$ (day 3). In contrast to the OSR measurements, there was no sta-

tistically significant difference ($p = 0.589$) between tendon volume in the morning and the evening ([Fig. 1](#) and [Table 2](#)).

Discussion

The results of this in-vivo study demonstrate a significant influence of gravitational interstitial fluid accumulation after 11 hours of reduced physical activity on OSR values, but not on tendon volume. This represents an important finding for future studies investigating temporal changes of the Achilles tendon microstructure using magnetization transfer effects.

Several previous studies used the possibility of obtaining signal from healthy tendinous tissue by using UTE sequences and thereby investigated the Achilles tendon microstructure with different MR-specific parameters such as T1, mono or multi-exponential T2* relaxation times and magnetization transfer effects (or the previously described more generic “off-resonance saturation ratios” [OSR]) [5, 7 – 15]. In this regard, OSR values at 2000 Hz demonstrated a better sensitivity and specificity for detecting mild and severe stages of tendinopathy compared to mono-exponential T2* and particularly when compared to T1 relaxation times [14]. Furthermore, OSR measurements at 2000 Hz off-resonance showed the highest repeatability compared to OSR values at other off-resonance frequencies [20]. As a consequence, in this study a 2000 Hz off-resonance saturation in addition to tendon volume measurements was used to analyze potential intradiurnal changes of the tendon water content. Note in this context that both measurement parameters have already been successfully used in several previous published studies investigating tendinopathic tendon alterations [5, 9, 14, 19 – 21].

In the presented study, excellent reproducibility of OSR and tendon volume measurements on three consecutive days (separately for morning and evening measurements) was found. The highest reproducibility, i.e. highest ICC, was found for the morning OSR measurements. The ICC values for the tendon volume measurements in the evening were slightly lower, but still showed excellent reproducibility. This most likely demonstrates the repeated overnight return to normal tendon structure after a day of prolonged sedentary occupation. The demonstrated reproducibility of this quantitative MRI method has marked implications for future studies determining the tendon volume and OSR values. These results are in accordance with previously published data by Syha et al., who reported excellent repeatability of OSR measurements after removing, repositioning and rescanning the same patient [20]. However, the slightly lower ICC values for the evening measurements may be attributed to a less standardized influence of a day long pre-dominantly sedentary occupation compared to a relatively standardized rest during sleep overnight. Nevertheless, the ICC for both OSR measurements and tendon volume also show good reproducibility with values above 0.96 (CI: 0.86 – 0.99).

The OSR measurements in this study are within the range of previously reported measurement values for the mid-portion Achilles tendon area (for example Grosse et al. who investigated 8 healthy female as well as 9 healthy male participants and reported mean OSR values of 0.32 ± 0.03 at 2000 Hz off-resonance) [5]. However, it is worth mentioning that OSR values cannot be considered as absolute biomarkers and are dependent on several external sequence-specific as well as tissue-dependent factors [7]. Hence, the observed decrease of OSR values in the evening measurements can be either attributed to an increased amount

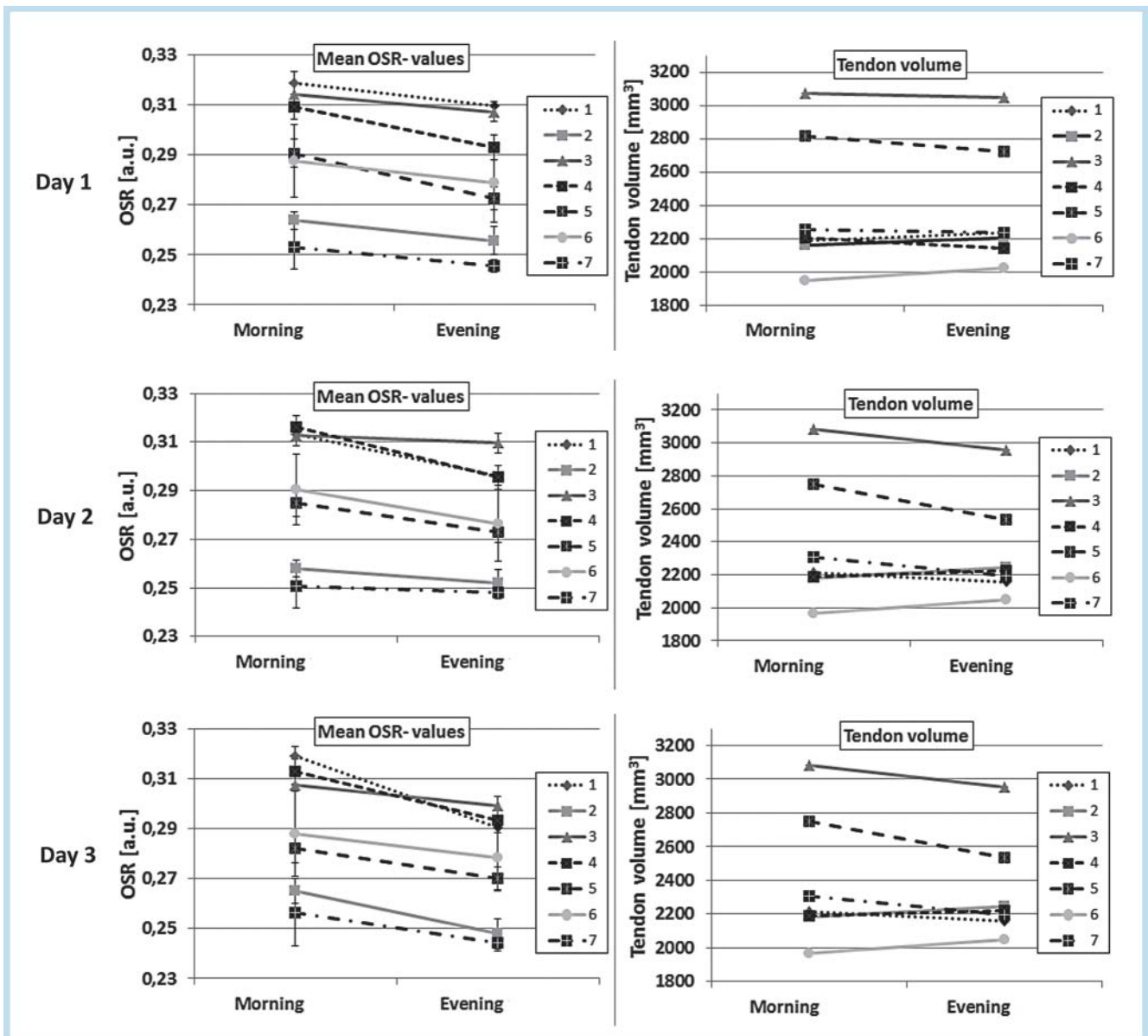


Fig. 1 Mean OSR values (error bars represent standard deviations) at 2000 Hz off-resonance of the caudal and cranial mid-portion tendon area as well as tendon volume of each participant (1–7) on three consecutive measurement days (day 1–3) in the morning and the evening.

Abb. 1 Demonstriert werden für alle Studienteilnehmer (1–7) neben dem Sehnenvolumen gemittelte OSR-Werte bei 2000 Hz Off-Resonanz (die Fehlerbalken stellen die zugehörige Standardabweichung dar) für den kranialen und kaudalen Anteil des mittleren Achillessehnenbereichs an drei aufeinanderfolgenden Messtagen (Tag 1–3) am Morgen und Abend.

of free water protons or a decrease in the number of bound protons (consequently decreasing the OSR numerator) or a combination of both factors. In our opinion, the decrease of OSR values in the evening can be most likely explained by the infiltration of the Achilles tendon by free water protons caused by gravitational interstitial fluid accumulation. This hypothesis is in our view not contradicted by the fact that no statistically significant increase of tendon volume in the evening was observed, since the differences in tendon volume (e.g. swelling of the tendon accompanying the intra-tendinous fluid accumulation) might be too subtle to be depicted by measurements based on a 0.8 mm isotropic MR sequence. A change in the macromolecular content or in the amount of bound water protons is also less likely to be the cause, due to the repeated return to normal overnight. This finding is

supported in **Fig. 2**, which shows, additionally to the decrease of the OSR in the Achilles tendon, a decrease of the OSR values in the surrounding dermis, known to feature marked magnetization transfer effects. This is in particular true for the epidermis and less marked for the subcutis [22].

It is important to notice that not only in pathological conditions, but also in healthy young subjects with a fully functional phlebo-lymphatic apparatus fluids and macromolecules are known to accumulate in the interstitium of the lower extremity after a prolonged time of standing or sitting [16, 17]. This has been extensively studied assessing the lower leg volume using either water plethysmography or other 3D measurement methods. For example, Noddeland et al. reported a 5.7% volume increase after 8 hours of sitting, while Tessari et al. stated absolute values and

Table 2 Mean OSR values with standard deviations at 2000 Hz off-resonance averaged over all participants are given at the cranial and caudal mid-portion area as well as tendon volume (mean and standard deviation) for each of the consecutive measurement days (morning and evening measurements).

Tab. 2 Neben dem Sehnenvolumen (Mittelwert mit Standardabweichung) sind gemittelte OSR-Werte bei 2000 Hz Off-Resonanz mit Standardabweichung über alle Studienteilnehmer für den kranialen und kaudalen Anteil des mittleren Achillessehnenbereichs sowie die drei konsekutiven Messtage (mit morgendlicher und abendlicher Messung) angegeben.

	day 1		day 2		day 3	
	morning	evening	morning	evening	morning	evening
OSR caudal (CA)	0.28 ± 0.03 (104 ± 18)	0.27 ± 0.03 (109 ± 14)	0.28 ± 0.03 (101 ± 15)	0.27 ± 0.03 (107 ± 18)	0.28 ± 0.03 (102 ± 34)	0.27 ± 0.02 (106 ± 16.6)
OSR cranial (CR)	0.30 ± 0.02 (55 ± 10)	0.29 ± 0.02 (53 ± 16)	0.30 ± 0.02 (53 ± 14)	0.28 ± 0.02 (61 ± 7)	0.30 ± 0.02 (53 ± 12)	0.28 ± 0.03 (55 ± 14)
tendon volume [mm ³]	2378 ± 406	2374 ± 369	2391 ± 386	2330 ± 313	2358 ± 387	2352 ± 366

For all OSR values the number of pixels in the used ROI for OSR calculation is given in brackets. Please note, that only the intra-individual course of OSR values of all participants was evaluated in the statistical analysis and showed a statistically significant difference between morning and evening measurements.

Zusätzlich steht in Klammern für alle OSR-Werte die gemittelte Anzahl an Pixeln mit Standardabweichung der benutzten ROI. Hierbei ist zu beachten, dass nur die intra-individuellen OSR-Veränderungen im Tagesverlauf einen statistisch signifikanten Unterschied zwischen morgendlichen und abendlichen Messergebnissen aufwiesen.

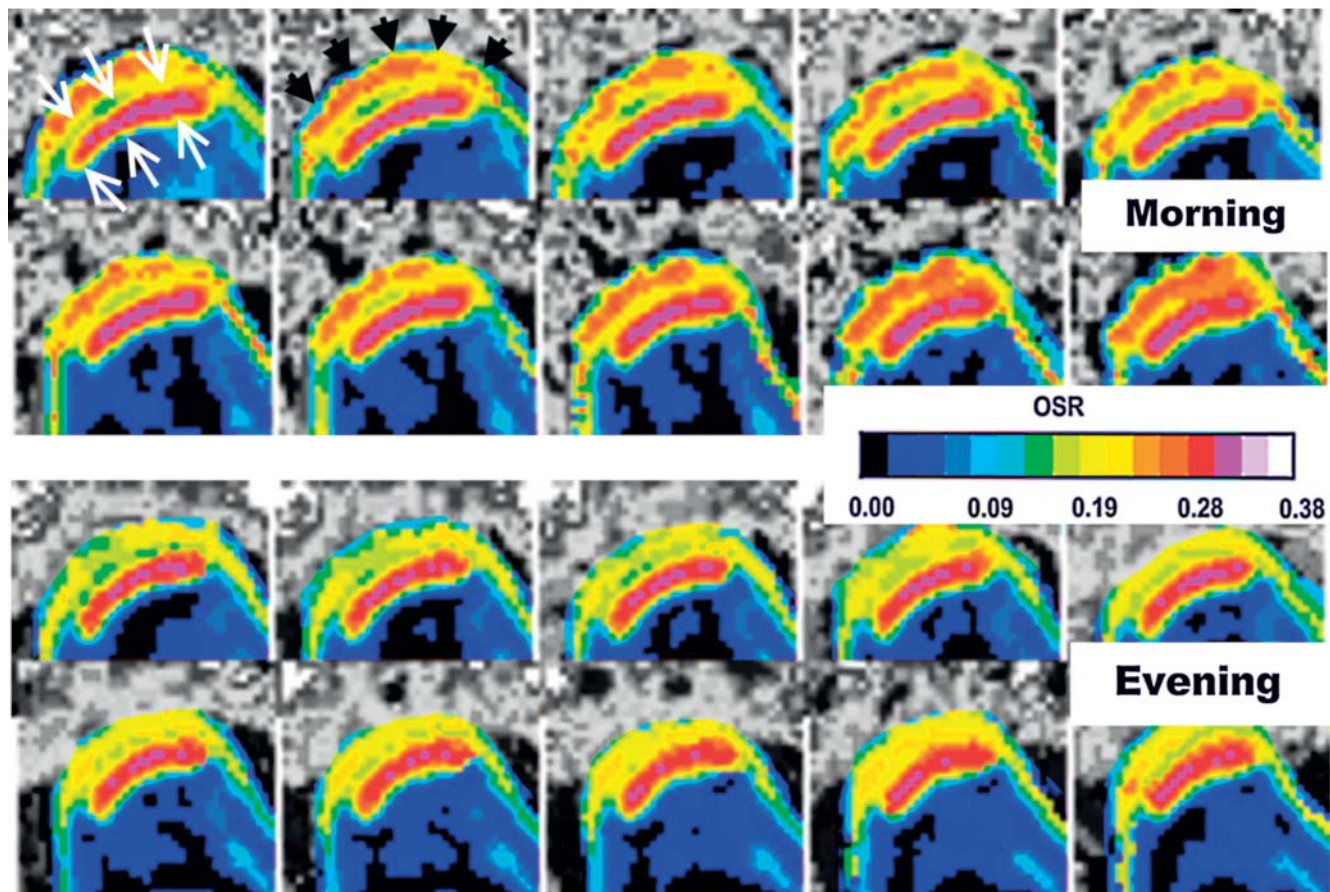


Fig. 2 Transverse OSR maps (2 kHz off-resonance; caudal to cranial from left to right and above to below) acquired in the morning and in the evening of a 31-year-old male participant (BMI 25 kg/m²) are shown. Note the slight decrease of OSR values of the Achilles tendon (Achilles tendon marked with white arrows) in the evening while at the same time a marked decrease of OSR values could be observed in the peritendinous tissue and the adjacent skin (skin marked with black arrowheads) resulting in a better delineation of the tendon.

Abb. 2 Demonstriert werden transversale OSR-Karten (bei 2000 Hz Off-Resonanz; von kaudal nach kranial wird von links nach rechts sowie oben nach unten dargestellt) am Morgen und Abend eines 31 Jahre alten Studienteilnehmers (BMI 25 kg/m²). Man beachte die geringe Abnahme der intratendinösen OSR-Werte (die Achillessehne wird hierbei mit weißen Pfeilen markiert) am Abend während es gleichzeitig zu einer deutlichen Abnahme der OSR-Werte im peritendinösen Gewebe sowie der miterfassten Haut (markiert mit schwarzen Pfeilspitzen) kommt, welche zudem in einer besseren Abgrenzbarkeit der Achillessehne im Vergleich zu den Messungen am Morgen führt.

found an increase of the lower leg volume in participants after 8 hours of standing of about 87.5 to 90 ml [16, 17]. A less marked

increase of foot volume of 2.7% was reported by Noddeland et al. in participants who keep their feet spontaneously active [17].

Other authors additionally evaluated the influence of various degrees of exercise on foot volume and found an increase of foot volume of about 1% to 3% depending on the duration and type of activity [23]. Further studies investigated the positive effect of various compression stockings on occupational leg swelling [24, 25]. In addition to these volumetry-based studies, numerous MR studies also examined the morphological MR appearance of lymphedema or phlebedema in the lower extremity [26–28]. Meler et al. reported a marked subcutaneous, perifascicular and even intramuscular fluid accumulation, but only used morphological MR sequences in patients with fluid overload [29]. However, to our knowledge no previous study quantitatively investigated the influence of gravitational interstitial fluid accumulation in tendinous tissue in the lower extremity. One might argue that the mean intra-individual decrease of OSR of $4.1\% \pm 1.5\%$ in the evening without a significant increase in tendon volume is negligible, but this was demonstrated continuously in all seven volunteers and the results are within the range of previously reported exercise-induced differences in OSR values. For example, a study with comparable parameters by Syha et al. evaluating the effect of 6 km cross-country running reported a mean increase of the absolute OSR value in the mid-portion area of the tendon of 0.029, which approximates about 9% [20]. The knowledge of these subtle natural fluctuations of water content in healthy tendons, either exercise-induced or due to prolonged sitting/standing during the day of examination, is a prerequisite for studies quantitatively evaluating the tendon microstructure. This study demonstrates the high sensitivity of 3D UTE sequences for detecting these effects and one has to keep in mind that this interstitial fluid accumulation might be even more pronounced in patients without a functional phlebo-lymphatic apparatus.

In addition to the already known variation of tendon relaxation times between different tendon sections, future cross-sectional and longitudinal studies investigating temporal alterations of the tendon microstructure as well as early stages of tendon disorders should be aware of these subtle influencing factors, which might become evident already after a prolonged time of standing (more than 30 minutes) during the day of examination [23]. The main limitation of this pilot study is the relatively small sample size and the missing correlation of our data with lower leg volume measurement methods. Another limitation of the study is that only male participants were examined and OSR measurements were only performed at 2000 Hz off-resonance. Due to the demonstrated high repeatability/reproducibility of OSR measurements at this off-resonance frequency and the only minor observed intradiurnal OSR fluctuations in this study, it is unlikely that less sensitive parameters, such as mono-exponential $T2^*$ calculations, might be able to detect these subtle changes of the tendon microstructure. Nevertheless, future studies should investigate the time dependency of gravitational fluid shifts in the different tissues of the lower leg using OSR values, multi-exponential $T2^*$ calculations and lower leg volumetry. Additionally, we recommend the quantitative analysis of the tendon with a higher spatial resolution to investigate for possible regional differences.

In conclusion, intradiurnal gravitational fluid shifts in the lower leg after a prolonged time of a sedentary occupation do not seem to markedly affect tendon volume, but cause a decrease of the OSR values in tendinous tissues, which can be most likely explained by an accumulation of free water protons. Though subtle, these findings can be appreciated with 3D UTE sequences demonstrating its high sensitivity and might partly explain the variation of OSR

measurements in healthy tendons in previous studies. Therefore, great care regarding both the time of measurement and the previous physical activity should be taken into account in future quantitative studies investigating the Achilles tendon by magnetization transfer effects and other quantitative parameters.

Clinical relevance

- ▶ The demonstrated high day-to-day reproducibility of tendon volume and intratendinous OSR values makes them a promising measurement tool for the analysis of temporal alterations of tendon microstructure.
- ▶ Gravitational fluid shifts in the lower leg might partly explain the variation of OSR measurements in healthy tendons in previous studies.
- ▶ Physiological interstitial fluid shifts even in healthy individuals can influence highly sensitive quantitative MR parameters such as the OSR measurements used in this study.

References

- 1 de Jonge S, van den Berg C, de Vos RJ et al. Incidence of midportion Achilles tendinopathy in the general population. *Br J Sports Med* 2011; 45: 1026–1028
- 2 Syha R, Springer F, Ketelsen D et al. Achillodynia – radiological imaging of acute and chronic overuse injuries of the achilles tendon. *Fortschr Röntgenstr* 2013; 185: 1041–1055
- 3 Weber C, Wedegartner U, Maas LC et al. MR imaging of the Achilles tendon: evaluation of criteria for the differentiation of asymptomatic and symptomatic tendons. *Fortschr Röntgenstr* 2011; 183: 631–640
- 4 Cook J, Purdam CR. Is tendon pathology a continuum? A pathology model to explain the clinical presentation of load-induced tendinopathy. *Br J Sports Med* 2009; 43: 409–416
- 5 Grosse U, Syha R, Martirosian P et al. Ultrashort echo time MR imaging with off-resonance saturation for characterization of pathologically altered Achilles tendons at 3 T. *Magnetic Resonance in Medicine* 2013; 70: 184–192
- 6 Filho GH, Du J, Pak BC et al. Quantitative characterization of the Achilles tendon in cadaveric specimens: T1 and $T2^*$ measurements using ultrashort-TE MRI at 3 T. *American Journal of Roentgenology* 2009; 192: W117–W124
- 7 Hodgson RJ, Evans R, Wright P et al. Quantitative magnetization transfer ultrashort echo time imaging of the Achilles tendon. *Magnetic Resonance in Medicine* 2011; 65: 1372–1376
- 8 Hodgson RJ, Grainger AJ, O'Connor PJ et al. Imaging of the Achilles tendon in spondyloarthritis: a comparison of ultrasound and conventional, short and ultrashort echo time MRI with and without intravenous contrast. *Eur Radiol* 2011; 21: 1144–1152
- 9 Syha R, Martirosian P, Ketelsen D et al. Magnetization transfer in human Achilles tendon assessed by a 3D ultrashort echo time sequence: quantitative examinations in healthy volunteers at 3T. *Fortschr Röntgenstr* 2011; 183: 1043–1050
- 10 Juras V, Apprich S, Szomolanyi P et al. Bi-exponential $T2^*$ analysis of healthy and diseased Achilles tendons: an in vivo preliminary magnetic resonance study and correlation with clinical score. *European Radiology* 2013; 23: 2814–2822
- 11 Wright P, Jellus V, McGonagle D et al. Comparison of two ultrashort echo time sequences for the quantification of T1 within phantom and human Achilles tendon at 3 T. *Magnetic Resonance in Medicine* 2012; 68: 1279–1284
- 12 Juras V, Zbyn S, Pressl C et al. Regional variations of $T2^*$ in healthy and pathologic achilles tendon in vivo at 7 Tesla: preliminary results. *Magnetic Resonance in Medicine* 2012; 68: 1607–1613
- 13 Grosse U, Springer F, Hein T et al. Influence of physical activity on T1 and $T2^*$ relaxation times of healthy achilles tendons at 3T. *Journal of Magnetic Resonance Imaging* 2013, in press. 10.1002/jmri.24525
- 14 Grosse U, Syha R, Hein T et al. Diagnostic value of T1 and $T2^*$ relaxation times and off-resonance saturation effects in the evaluation of achilles

- tendinopathy by MRI at 3T. *Journal of Magnetic Resonance Imaging* 2014
- 15 Wang N, Xia Y. Anisotropic analysis of multi-component T2 and T1 ρ relaxations in achilles tendon by NMR spectroscopy and microscopic MRI. *Journal of Magnetic Resonance Imaging* 2013
 - 16 Tessari M, Menegatti E, Giancesini S et al. Assessment of lower limbs edema in healthy workers who are exposed to long-term gravity. *Veins and Lymphatics* 2013; 2: e19
 - 17 Noddeland H, Winkel J. Effects of leg activity and ambient barometric pressure on foot swelling and lower-limb skin temperature during 8h of sitting. *European journal of applied physiology and occupational physiology* 1988; 57: 409–414
 - 18 Springer F, Martirosian P, Schwenzer NF et al. Three-dimensional ultrashort echo time imaging of solid polymers on a 3-Tesla whole-body MRI scanner. *Invest Radiol* 2008; 43: 802–808
 - 19 Syha R, Würslin C, Ketelsen D et al. Automated volumetric assessment of the Achilles tendon (AVAT) using a 3D T2 weighted SPACE sequence at 3T in healthy and pathologic cases. *European journal of radiology* 2012; 81: 1612–1617
 - 20 Syha R, Springer F, Grözinger G et al. Short-term exercise-induced changes in hydration state of healthy achilles tendons can be visualized by effects of off-resonant radiofrequency saturation in a three-dimensional ultrashort echo time MRI sequence applied at 3 tesla. *Journal of Magnetic Resonance Imaging* 2013
 - 21 Syha R, Springer F, Würslin C et al. Tendinopathy of the Achilles Tendon: Volume Assessed by Automated Contour Detection in Submillimeter Isotropic 3-Dimensional Magnetic Resonance Imaging Data Sets Recorded at a Field Strength of 3 T. *Journal of computer assisted tomography* 2015
 - 22 Tsukahara K, Takema Y, Moriwaki S et al. Dermal fluid translocation is an important determinant of the diurnal variation in human skin thickness. *British Journal of Dermatology* 2001; 145: 590–596
 - 23 Kunde S, Sterzing T, Milani T. Influence of Body Position and Sports Activity onto Foot Dimension. *Deutsche Zeitschrift für Sportmedizin* 2009; 60: 90–93
 - 24 Partsch H, Winiger J, Lun B. Compression stockings reduce occupational leg swelling. *Dermatologic surgery* 2004; 30: 737–743
 - 25 Mosti G, Partsch H. Occupational leg oedema is more reduced by anti-graduated than by graduated stockings. *European Journal of Vascular and Endovascular Surgery* 2013; 45: 523–527
 - 26 Åström K, Abdsaleh S, Brenning G et al. MR imaging of primary, secondary, and mixed forms of lymphedema. *Acta Radiologica* 2001; 42: 409–416
 - 27 Duewell S, Hagspiel KD, Zuber J et al. Swollen lower extremity: role of MR imaging. *Radiology* 1992; 184: 227–231
 - 28 Li Y, Lu Q, Chen TW et al. Thickness of soft tissue of lower extremities measured with magnetic resonance imaging as a new indicator for staging unilateral secondary lower extremity lymphedema. *Acta Radiologica* 2014, 0284185114542995
 - 29 Meler JD, Solomon MA, Steele JR et al. The MR appearance of volume overload in the lower extremities. *Journal of computer assisted tomography* 1997; 21: 969–973