

A 17-Year Follow-Up after Total Tibial Replacement in the Course of an Osteosarcoma followed by Total Leg Replacement

Rolf D. Burghardt, MD¹ Daniel Kendoff, MD² Wolfgang Klauser, MD² Hans Mau, MD²
Thorsten Gehrke, MD²

¹ Department of Orthopaedic, University Hamburg Eppendorf, Hamburg, Germany

² Department of Orthopädie, Endoklinik, Hamburg, Germany

Address for correspondence Rolf D. Burghardt, MD, University Medical Center Hamburg Eppendorf Martinistr. 52, 20246 Hamburg, Germany (e-mail: rolf-burghardt@web.de).

J Knee Surg Rep 2015;1:44–50.

Abstract

We report a case of an initially 16-year-old female patient, diagnosed with an osteosarcoma of her left proximal tibia. Treatment consisted of tumor resection in combination with the implantation of a customized tumor prosthesis and chemotherapy. The patient developed a deep infection and several additional surgeries were inevitable. Because of increasing bone loss the distal tibia anchoring was insufficient and a custom-made total tibial prosthesis was designed and implanted to brace against the talus. After 17 years the femoral component became loose and the upper part of the prosthesis had to be exchanged with a total femur prosthesis. To our knowledge, there is no other case reported in the literature where a patient had to be treated with a prosthesis replacing the entire femur and tibia.

Keywords

- ▶ osteosarcoma
- ▶ tumor prosthesis
- ▶ tibia replacement
- ▶ femur replacement
- ▶ limb reconstruction

Osteosarcoma is an aggressive bone tumor arising from mesenchymal stem cells characterized by direct formation of bone matrix (osteoid). It is the most common primary malignant bone tumor comprising approximately 20% of all primary bone cancers and occurs mostly at the age between 15 and 25 years. It can affect all bones, but most often involves the metaphysis of the long bones with 42% occurring in the femur, 19% in the tibia, and 10% in the humerus.¹ The articular cartilage acts as a natural barrier, which normally prevents the tumor from spreading into the joint. Treatment of musculoskeletal sarcoma of the extremities poses one of the biggest challenges for orthopedic surgeons. For this reason, complete radical surgical en bloc resection is the treatment of choice. Advancement in adjuvant and neoadjuvant chemotherapy has led to a substantial improvement in the survival rate. No longer a certain fatal diagnosis, osteosarcoma can be treated with limb salvage, which has become the cornerstone in the surgical treatment of the tumor. This has essentially changed the requirements for tumor prostheses.² Tumor endoprosthesis are either custom-made or of a modular

composition. As the osteosarcoma mostly occurs around the knee, rotating or fixed hinge knee joint tumor endoprosthesis are usually used.^{3–6} However, hip prostheses and sometimes even total femoral prostheses are also necessary.^{7,8} In cases of distal tibial musculoskeletal tumors, endoprosthetic replacement of the distal tibia and ankle joint are performed as well.⁹ Limb reconstruction with extensive customized endoprosthesis, however, is associated with a higher incidence of serious complications especially periprosthetic joint infections. Infection rates up to 44.6% are reported.¹⁰ Especially periprosthetic joint infections are a main reason for a secondary amputation. Aseptic loosening is a further common reason for revisions.⁴

We now report a case of an initially 16-year-old female patient with an osteosarcoma of her left proximal tibia, which was primary, treated with a custom-made tumor knee endoprosthesis. In the course of a deep infection with several surgical revisions, it became necessary to exchange the prosthesis and the patient was consecutively treated with a total tibial replacement.

received
April 15, 2014
accepted after revision
February 8, 2015
published online
July 10, 2015

DOI <http://dx.doi.org/10.1055/s-0035-1551547>.
ISSN 2326-2729.

Copyright © 2015 by Thieme Medical Publishers, Inc., 333 Seventh Avenue, New York, NY 10001, USA.
Tel: +1(212) 584-4662.

License terms



Case Presentation

After a history of 6 months with pain, hyperthermia, and swelling, a previously fit and healthy 16-year-old female patient was diagnosed with an osteosarcoma of her left proximal tibia in August 1993 (► **Fig. 1**). Histological assessment showed a sclerotic osteoplastic osteosarcoma. The initial treatment consisted of a chemotherapy following the Coss-86c protocol,¹¹ and resection of the upper half of the tibia, and consecutive reconstruction of the joint with a customized endoprosthesis (► **Table 1**). Basis was a spherocentric knee endoprosthesis with a cement less femoral fixation and a cemented tibial fixation. This hinge prosthesis has a ball axle; the femoral sliding surface is supported by the tibial polyethylene inlay. The patella tendon was attached to the proximal tibial component. The histology of the resection showed a regression grade II, as defined by Salzer-Kuntschik.¹² Two months after the implantation of the prosthesis, the patient complained of hyperthermia and swelling of the leg. Radiological findings indicated the possibility of an osteomyelitis. Without further biological investigation an antibiotic treatment was performed. After fading of these symptoms the postoperative chemotherapy was restarted in May 1994. In November 1994, radiolucent lines of the implant were present on the radiographs. The tibial part was exchanged by cementing the 9 cm remaining distal tibia. In August 1995, the patient presented to our department for the first time with a severe periprosthetic joint infection (PJI) with *Staphylococcus epidermidis* and a fistula with a soft tissue lesion above the medial malleolus. Due to the wide resistance of the bacterium it was decided that a single stage exchange of the customized prosthesis in combination with a systematic antibiotic regime with ofloxacin and vancomycin was necessary. The customized new prosthesis was to consist of a cemented femoral stem with a length of 290 mm, and the length of the tibial stem—also cemented—was 339 mm. As the distal mounting/anchoring was insufficient, the distal tibia stem was designed to be combined in a second stage with an extension ending in a semishell with a length of 72 mm (► **Figs. 2 and 3**). After the successful treatment of the PJI, this extension was added to provide sufficient bracing to the talus for full weight-bearing. After receiving the customized prosthesis the exchange was performed and the soft tissue

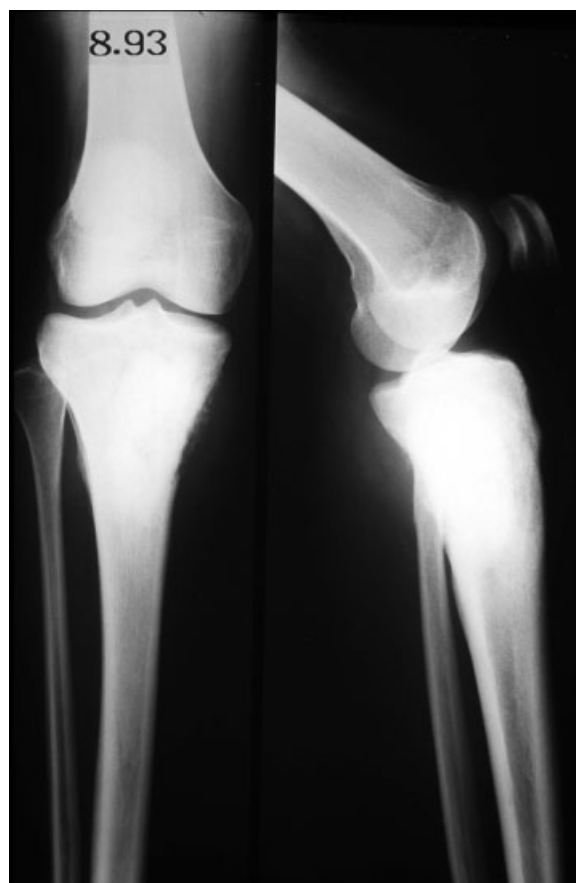

Fig. 1 Radiographs showing an sclerotic osteoplastic osteosarcoma diagnosed after a previously fit and healthy 16-year-old girl suffered for 6 months of pain, hyperthermia, and swelling in the left leg.

lesion was successfully covered with a vascularized flap (► **Fig. 4**). Four months after the single stage exchange, as a second procedure following the healing of the periprosthetic joint infection (PJI), the semishell extension was added and stable contact to the talus was reached (► **Fig. 5**). The patient recovered quickly after this two-stage limb reconstruction. Ten weeks after the second surgery the patient was fully mobile with full extension of the knee and 110-degree flexion. This good function could be preserved for more

Table 1 Chronologic listing of surgical procedures

Date	Type of procedure
August 1993	Diagnosis of an osteosarcoma after 6 mo of pain
September 1993	Tumor resection/implantation hinge knee
November 1993	Fracture/exchange tibial component
March 1994	Infection/exchange tibial component
August 1995	Infection/single-stage exchange to a total tibia
August 1996	Exchange distal tip of total tibia prosthesis
June 2013	Aseptic loosening/exchange femoral component to total femur

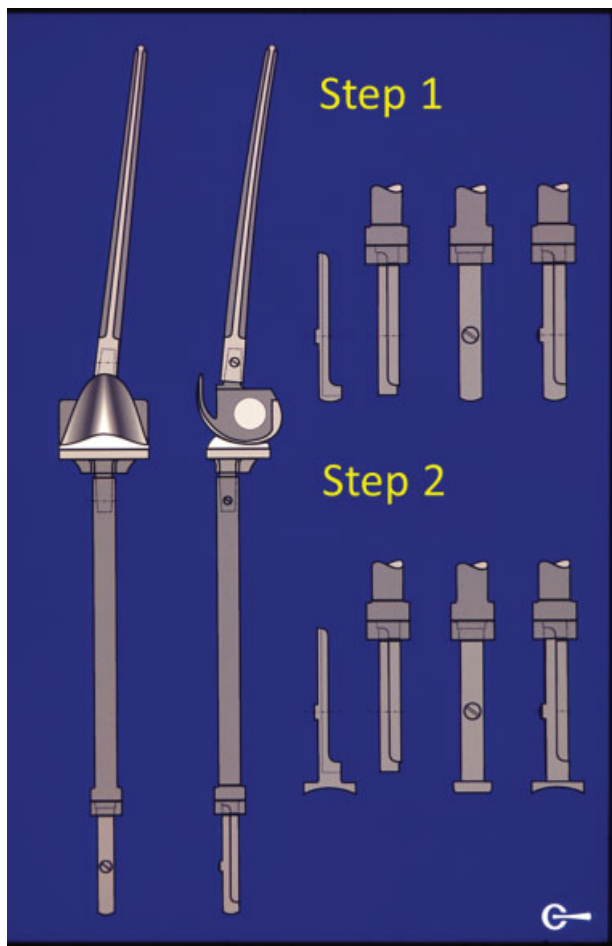


Fig. 2 Schematic showing the details of the customized total tibial prosthesis. It was planned after implanting this prosthesis and healing of the periprosthetic infection to exchange the distal ending with an extension ending with a semishell with a length of 72 mm to enforce the insufficient distal mounting/anchoring.

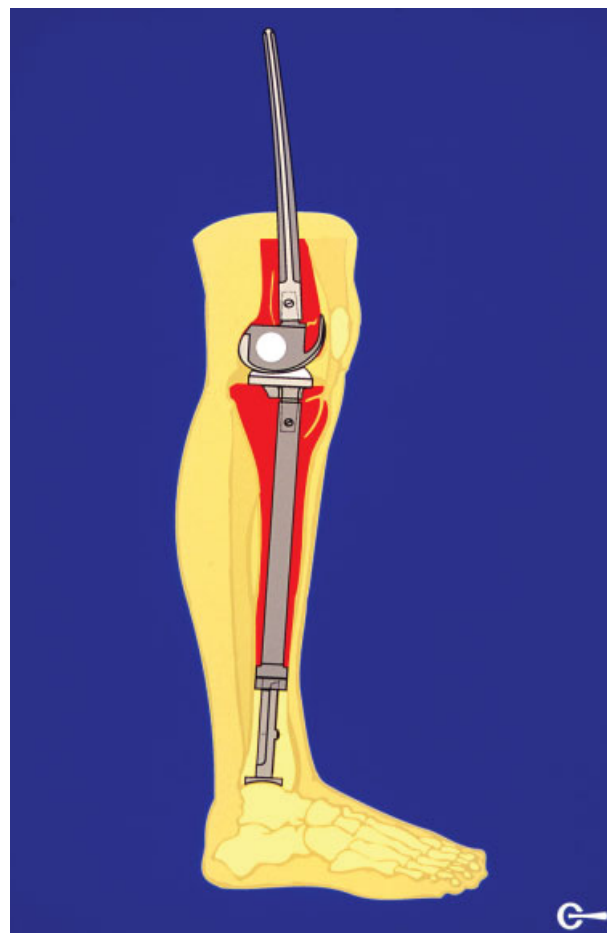


Fig. 3 Schematic showing the implanted customized total tibial prosthesis after exchanging the distal ending with the extension ending with the semishell to stabilize against the talus.

than 17 years. During this time the patient was examined on a regular basis (→Fig. 6A, B) and was always fully confident with the surgical result, completely back in work and normal life. She reported that even backpacking all over the world (e. g., Australia, Asia) was possible. In regards to additives, she was just using a surgical hose and orthopedic boots for a decent period of time. In 2009 for the first time some signs of loosening of the proximal tip of the femoral component were observed. Two years later during the next routine radiological follow-up evaluation, it was observed that the slight loosening at the tip of the femoral component had increased. At this time the patient was free of any symptoms, so no intervention was needed. However, the patient was informed at this time that a further loosening was to be expected. Since a further endoprosthetic treatment would be very difficult and short in durability, the alternative that was discussed with the patient was to perform an above-knee amputation. Two years later in April 2013 the patient presented with increasing pain to our clinic. Radiographical extensive loosening of the femoral component with partial destruction of the femur was present (→Fig. 7). The tibial part, however, still showed a good

connection to the talus and was clinically inconspicuous. The patient rejected the option of an above-knee amputation, and after discussing the problem in a team and with the company it was decided that we would perform a complete

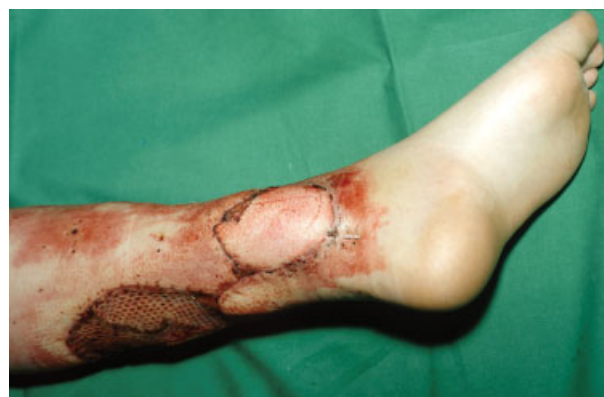

Fig. 4 Clinical picture showing the distal aspect of the patients left leg after covering the soft tissue lesion with a vascularized flap.

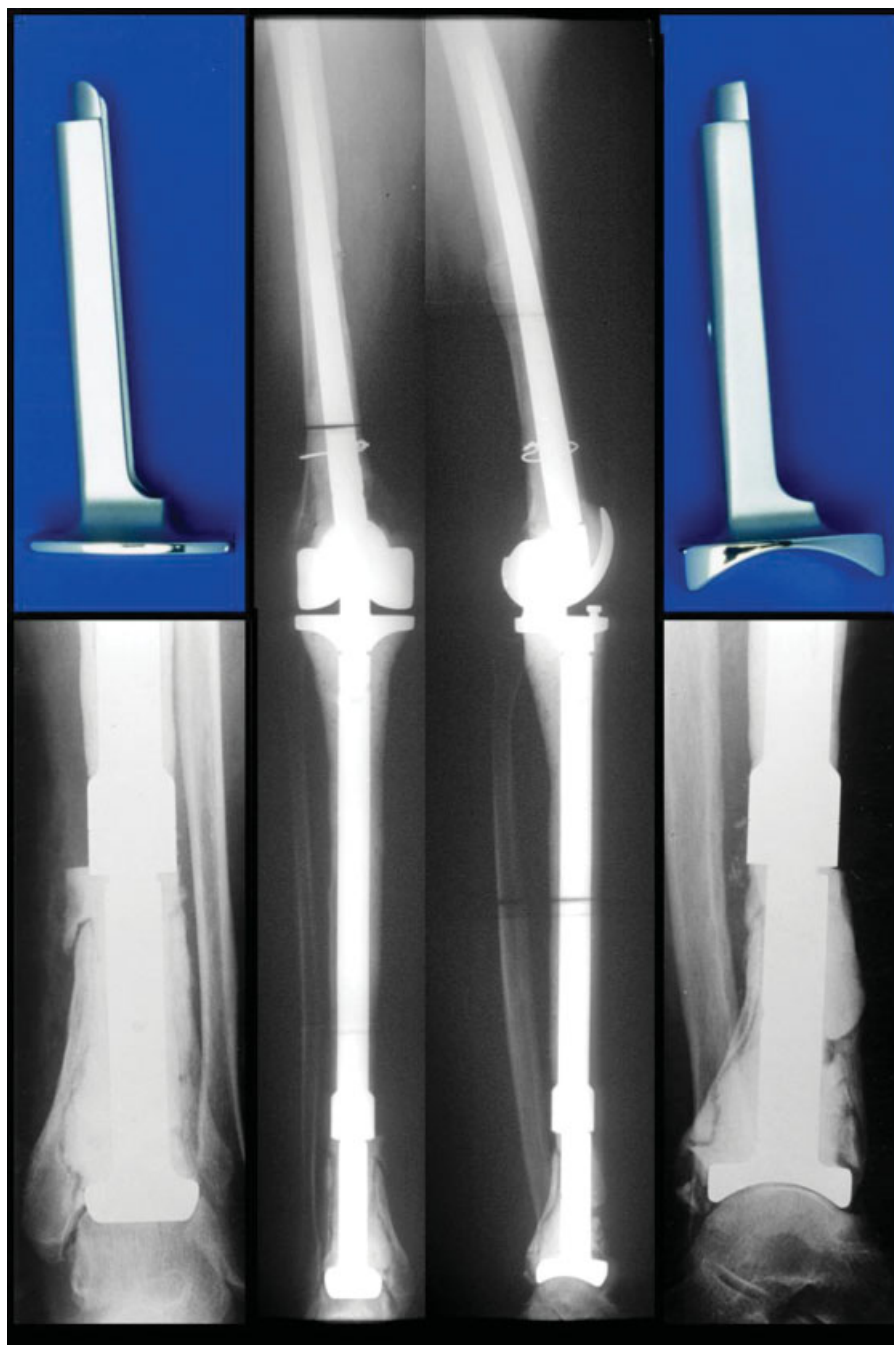


Fig. 5 Radiograph showing the entire left leg with the customized total tibial prosthesis in anterior-posterior and lateral view. On the sides the exploded section of the distal extension semishell ending in anterior-posterior and lateral view as well.

reconstruction of the tibia and femur with a customized total femoral prosthesis, which meant to sacrifice the hip joint as the remaining femur was too short for just inserting a longer femoral stem. After the customized implant was produced the patient underwent more than 17 years after the last reconstruction this surgical intervention. The femoral component was disconnected from the tibia and after resecting the proximal remaining femur, the total femoral prosthesis was implanted, resulting in a “total leg prosthesis” (►**Fig. 8**). Again, the patient recovered quickly and was dismissed fully mobile with partial weight-bearing with crutches and left the

hospital after 18 days in house stay, without current signs of infection. The most recent follow-up was 18 months after the last surgery. The patient at this time just came back from a 4-week vacation in New Zealand, where she accomplished hiking of over 15 km without relevant limitations or limping. She reported being nearly entirely pain-free during normal daily activities and at work. Her actual Tegner Lysholm knee score was 82. Her hip range of motion was an extension/flexion 0/0/110 degrees, abduction/adduction 30/0/15 degrees, and external/internal rotation 30/0/20 degrees. The knee range of motion was active 0/0/95 degrees, passive 0/0/

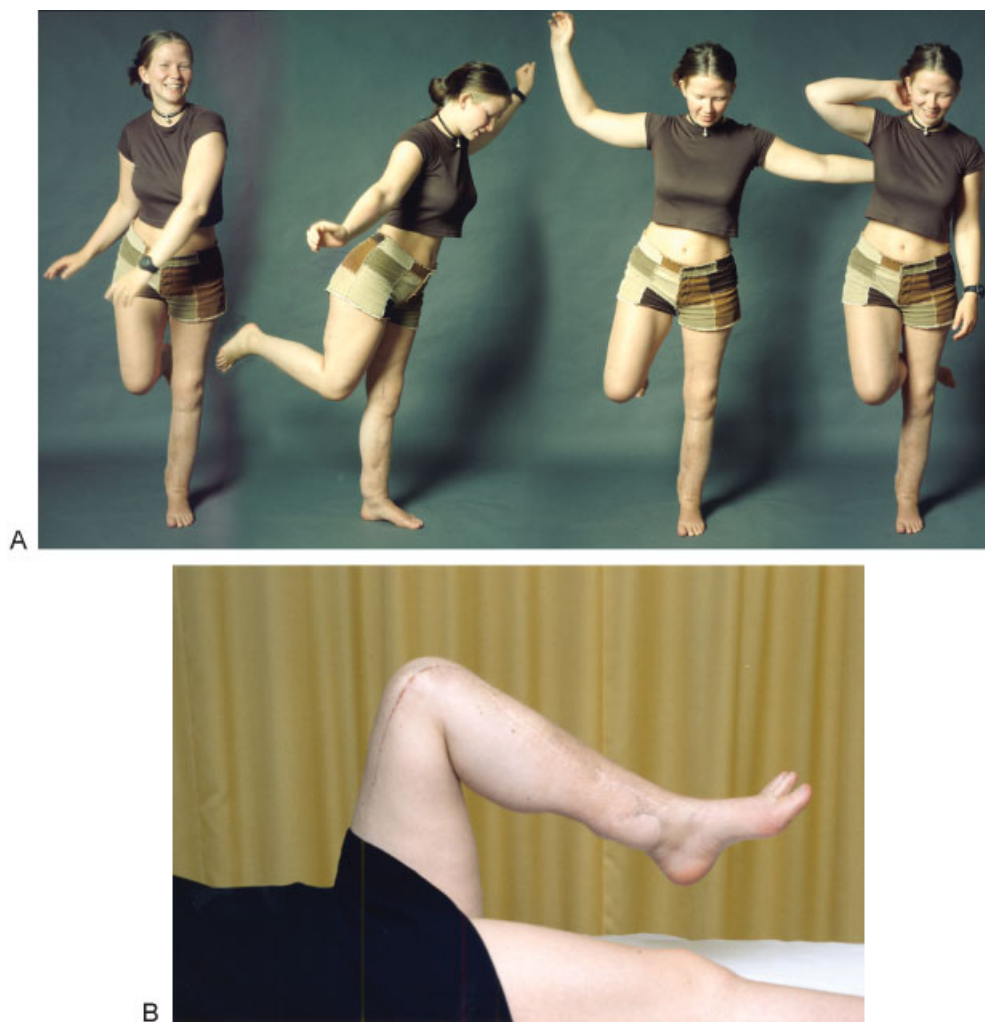

Fig. 6 (A and B) Showing clinical pictures of the patient during a follow-up 3 years after implanting the customized total tibial prosthesis. She was fully mobile had full extension of her knee and 110-degree flexion.

110 degrees. The reason for this limitation in active knee flexion is persisting muscle weakness after the initial surgeries. The ankle joint is wiggle-stiff in 10 degrees equinus compensated by a good range of motion in the midfoot. The equinus is compensated by heel support inlays in footwear.

Conclusion

Malignant bone tumors such as the osteosarcoma are a life-changing diagnosis. Over the past 20 years, however, the treatment options with surgical intervention and adjuvant or neoadjuvant chemotherapy have tremendously improved the life expectancy of tumor patients. Amputation or exarticulation were often the radical surgical intervention needed. With increasing patient survival rate, however, limb salvage instead of limb amputation has become the cornerstone for the surgical treatment, thereby pushing the surgical margins and requirements for tumor prostheses.² For most patients affected with a malignant bone tumor, limb salvage is essential. In our case the patient was confronted with the option of an above-knee amputation when she presented to our department the first time in August 1995. At this time her

implanted tumor prosthesis was deeply infected with a severe fistula and a soft tissue lesion above the medial malleolus. The remaining bone of the distal tibia was not strong enough to support enough purchase, for a normal revision tumor prosthesis. Therefore, the above-knee amputation had to be taken into account. This treatment option would give this young patient a reliable solution after repeated revision surgeries, especially considering the literature proving that the quality of life of patients having above-knee amputation is similar to patients having undergone limb-salvage procedures.¹³ The patient rejected the amputation option, therefore, one of the orthopedic surgeons in our department designed in 1995 a custom-made prosthesis replacing the entire tibia and brace to the talus for full weight-bearing. Because of the PJI, this total tibial prosthesis was designed to be altered in its distal ending. The primary ending in the remaining distal tibia was to be changed in a second procedure to an extension ending in a semishell to provide sufficient bracing to the talus for full weight-bearing after successful healing of the PJI. This implant was the first of its type and to our knowledge, no other case is reported yet, where a patient was treated in a similar way. Therefore, in

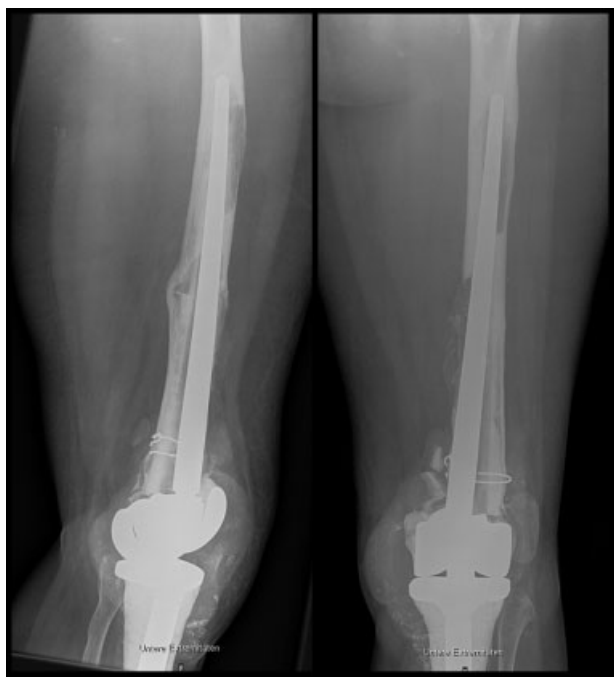

Fig. 7 Radiograph showing the extensive loosening of the femoral component with partial destruction of the femur.

1995 nobody could estimate the functional outcome and the durability of this unique custom-made mega prosthesis, especially in regard to the ankle joint function and stability.

Reports about implant survival using different types of tumor megaprosthesis present survival rates of 22 to 61% after 10 years.^{3,4,14,15} However, these reports address implant survival of mostly fixed- or rotating-hinge knee prostheses and some total femoral prostheses, but none of them addresses a total tibial replacement.

Regarding implant survival rates and complications with tumor prostheses, deep infection, despite loosening and mechanical failures, is the most common problem. Infection rates between 3.6 and 44.6% are reported in the literature.^{5,8,10} As all published studies emphasize, this complication seen in the circumstances of our patient cannot be unique. As we have not found any other reported case of a total tibial prosthesis we conclude that patients with a similar history to that of our patient are treated with an amputation.^{5,6,9,10} The use of a total femoral prosthesis is commonly reported in the literature either as a tumor prosthesis or in the course of failed total hip and knee arthroplasty and consequent extensive bone stock loss.^{7,8} For distal tibial bone tumors endoprosthesis replacement of the distal tibia and the ankle joint are also reported.⁹ Shekkeris reported a case series of six patients treated with a custom-made distal tibia/ankle joint prosthesis. He had two patients with an osteosarcoma, two with a Ewing sarcoma, one adamantinoma, and one malignant fibrous histiocytoma. The mean patient age was 43.9 (range, 15–75) years and a mean follow-up of 9.6 (range, 1–27) years. Two of these patients had to be treated with a below-knee amputation because of deep infection and one with an ankle arthrodesis.

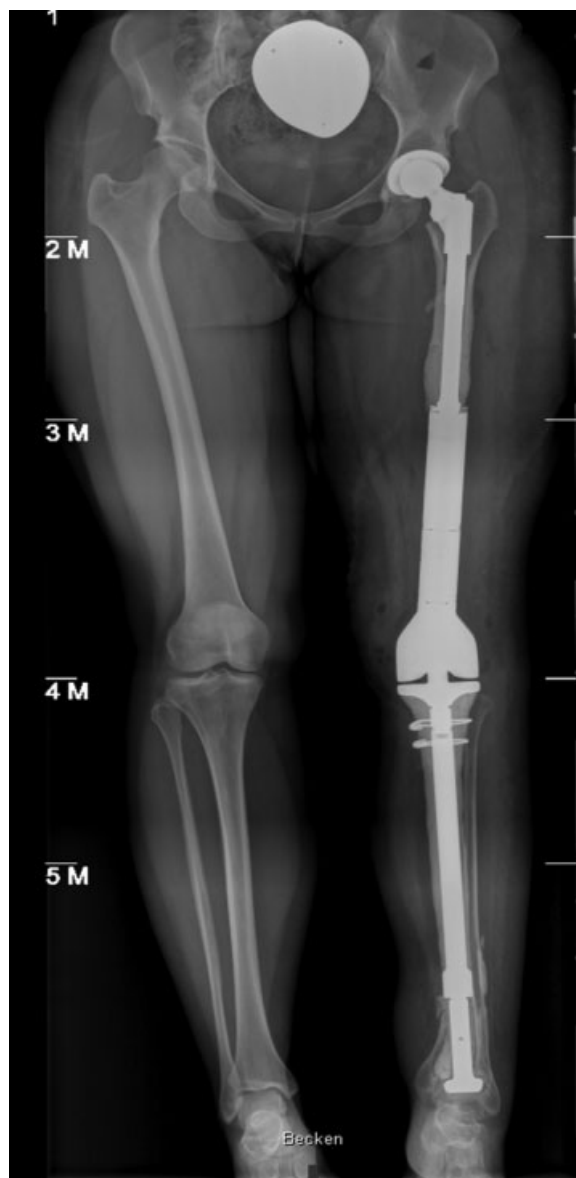

Fig. 8 Long radiograph showing both lower extremities of the patient. On the left side, the entire femur and tibia are replaced with a custom-made mega prosthesis.

All these reports present a high rate of complications such as infections, mechanical failures, loosening, among others. The complication rates increase in relation to the size of the prosthesis and the amount of bone loss. We received in 1995 a young female patient with a heavily infected proximal tibia prosthesis. At this time her chances of a good function after this unique first time total tibial replacement was judged not too good. However, this patient succeeded to walk with this custom-made prosthesis for over 17 years without needing to reduce any daily activities with respect to her young age. She even reported of her many backpacking trips to countries all over the world (e.g., Australia). Regarding her medical history, it is not surprising that she rejected again an amputation as a treatment option when finally in 2013 the femoral component was loose and had to be replaced.

We are aware of the fact that this procedure might be the very last option before a salvage procedure should be considered. Although the current clinical and radiographic outcome of this patient is more than satisfying, the potential risk of reinfection or loosening at the midterm should be considered relatively high. Consequently, a general high consent by the patient has to exist before the operation, including a strict explanation of the above mentioned risk potentials. Another important factor is the patient compliance in such rare cases, which need to be very high, for multiple obvious reasons. Furthermore, the patient needs to be informed about the potential risk for secondary arthritis of the talus in due time.

Consent

Written informed consent was obtained from the patient for publication of this case report and any accompanying images.

Conflict of Interest

None.

References

- 1 Ottaviani G, Jaffe N. The epidemiology of osteosarcoma. *Cancer Treat Res* 2009;152:3–13
- 2 Bacci G, Ferrari S, Lari S, et al. Osteosarcoma of the limb. Amputation or limb salvage in patients treated by neoadjuvant chemotherapy. *J Bone Joint Surg Br* 2002;84(1):88–92
- 3 Flint MN, Griffin AM, Bell RS, Ferguson PC, Wunder JS. Aseptic loosening is uncommon with uncemented proximal tibia tumor prostheses. *Clin Orthop Relat Res* 2006;450(450):52–59
- 4 Myers GJ, Abudu AT, Carter SR, Tillman RM, Grimer RJ. The long-term results of endoprosthetic replacement of the proximal tibia for bone tumours. *J Bone Joint Surg Br* 2007;89(12):1632–1637
- 5 Ruggieri P, Mavrogenis AF, Pala E, Abdel-Mota'al M, Mercuri M. Long term results of fixed-hinge megaprotheses in limb salvage for malignancy. *Knee* 2012;19(5):543–549
- 6 Wu CC, Henshaw RM, Pritsch T, Squires MH, Malawer MM. Implant design and resection length affect cemented endoprosthesis survival in proximal tibial reconstruction. *J Arthroplasty* 2008;23(6):886–893
- 7 Fountain JR, Dalby-Ball J, Carroll FA, Stockley I. The use of total femoral arthroplasty as a limb salvage procedure: the Sheffield experience. *J Arthroplasty* 2007;22(5):663–669
- 8 Heisel C, Kinkel S, Bernd L, Ewerbeck V. Megaprotheses for the treatment of malignant bone tumours of the lower limbs. *Int Orthop* 2006;30(6):452–457
- 9 Shekkeris AS, Hanna SA, Sewell MD, et al. Endoprosthetic reconstruction of the distal tibia and ankle joint after resection of primary bone tumours. *J Bone Joint Surg Br* 2009;91(10):1378–1382
- 10 Morii T, Morioka H, Ueda T, et al. Deep infection in tumor endoprosthesis around the knee: a multi-institutional study by the Japanese musculoskeletal oncology group. *BMC Musculoskelet Disord* 2013;14:51
- 11 Carrle D, Bielack SS. Current strategies of chemotherapy in osteosarcoma. *Int Orthop* 2006;30(6):445–451
- 12 Salzer-Kuntschik M, Brand G, Delling G. Determination of the degree of morphological regression following chemotherapy in malignant bone tumors [in German]. *Pathologe* 1983;4(3):135–141
- 13 Malek F, Somerson JS, Mitchel S, Williams RP. Does limb-salvage surgery offer patients better quality of life and functional capacity than amputation? *Clin Orthop Relat Res* 2012;470(7):2000–2006
- 14 Mittermayer F, Krepler P, Dominkus M, et al. Long-term followup of uncemented tumor endoprotheses for the lower extremity. *Clin Orthop Relat Res* 2001;(388):167–177
- 15 Parvizi J, Sim FH. Proximal femoral replacements with megaprotheses. *Clin Orthop Relat Res* 2004;(420):169–175