

Brown Tumor Related to Secondary Hyperparathyroidism Leading to Spinal Cord Compression Syndrome

Tumor marrom relacionado ao hiperparatireoidismo secundário levando à síndrome de compressão medular

Cesar Fantezia Andraus¹ Camilo Abud Sarquis Aiex¹ Diego Campolina Vidal¹

Francisco Bohrer Kabouk¹ João Thiago Frossard da Cruz Ferreira¹

Priscilla de Deus e Silva Moraes dos Santos¹ Maria Emilia Cosenza Andraus²

¹Neurosurgeon, Department of Neurosurgery, Hospital Universitário Clementino Fraga Filho, Universidade Federal do Rio de Janeiro (HUCFF-UFRJ), Rio de Janeiro, RJ, Brazil

²Neurologist, Santa Casa da Misericórdia; Professor, Department of Neurosurgery, Universidade Federal do Estado do Rio de Janeiro (UNIRIO), Rio de Janeiro, RJ, Brazil

Address for correspondence Cesar Fantezia Andraus, PhD, Serviço de Neurocirurgia, HUCFF/UFRJ, Rua Rodolpho Rocco, 255, 10º Andar/Cidade Universitária; 21941-913, Rio de Janeiro, RJ, Brazil (e-mail: andrausmc@uol.com.br).

Arq Bras Neurocir 2015;34:61–63.

Abstract

Keywords

- secondary hyperparathyroidism
- spinal cord compression
- giant cell tumor of bone

Brown tumor is a benign bone injury, which occurs only in the presence hyperparathyroidism. The involvement of the spine is relatively rare and therapeutic procedures are not yet fully established in these cases. We report a case of a chronic renal patient with a spinal cord compression syndrome at the level of T6, due to a brown tumor related to secondary hyperparathyroidism. The treatment of brown tumor should be directed to the control of hyperparathyroidism; however, there are insufficient data until this moment, and when spinal cord compression occurs, the surgical decompression should be considered.

Resumo

Palavras-chave

- hiperparatireoidismo secundário
- compressão da medula espinhal
- tumor de células gigantes do osso

Tumor marrom consiste numa lesão óssea benigna, que ocorre somente na presença de hiperparatireoidismo. O envolvimento da coluna vertebral é relativamente raro e a conduta terapêutica ainda não foi completamente estabelecida nesses casos. Relatamos o caso de um paciente com insuficiência renal crônica e síndrome de compressão medular ao nível de T6 devido a tumor marrom relacionado ao hiperparatireoidismo secundário. O tratamento do tumor marrom deve ser direcionado ao controle do hiperparatireoidismo, entretanto, não existem dados suficientes até o momento e, quando ocorre compressão medular, a descompressão cirúrgica deve ser considerada.

Introduction

Brown tumor, or osteoclastoma, is a benign bone injury, which occurs only in the presence of primary or secondary

hyperparathyroidism, with increased incidence in the presence of primary hyperparathyroidism.^{1–6}

Even though infrequent, the relationship of brown tumor with secondary hyperparathyroidism is well established.^{1–6}

received
January 27, 2014
accepted
November 1, 2014

DOI <http://dx.doi.org/10.1055/s-0035-1547386>.
ISSN 0103-5355.

Copyright © 2015 by Thieme Publicações Ltda, Rio de Janeiro, Brazil

License terms



Although secondary hyperparathyroidism is a frequent complication of chronic renal failure (CRF) in dialysis-dependent patients, brown tumor, as one of its manifestations, is relatively uncommon, with an incidence of 1.5 to 13%.¹⁻⁶ The tumor affects mainly the jaw, hands, feet, and facial bones, as well as, rarely, other skeletal sites.^{1-3,7} Clinically, it presents as a solitary, lytic and expansive lesion, and it may infrequently extend to the extra bone adjacent tissues.^{2,3,7} The involvement of the spine, causing spinal cord compression, is rare, with some cases reported in the literature.^{2,3,5,8} The diagnosis is based on clinical and radiologic findings, and the treatment consists of the secondary hyperparathyroidism control.^{1-3,5,7} However, the tumor regression is slow and uncertain. The literature has shown that in cases in which spinal cord compression occurs, surgical decompression should be considered, to prevent irreversible neurologic damage.^{1-5,7-14}

We report a case of a chronic renal patient with a spinal cord compression syndrome at the level of T6, due to a brown tumor, secondary to hyperparathyroidism. As the involvement of the spine is relatively rare and therapeutic procedures are not yet fully established, we considered it a relevant case to report.

Case Report

A 45-year-old man, with chronic renal disease due to hypertensive nephrosclerosis, in hemodialysis schedule three times a week, for 12 years, presented at the hospital with progressive crural paraparesis, with about a year and a half of evolution. He previously underwent parathyroidectomy due to secondary hyperparathyroidism refractory to medical therapy, with past medical history of pathologic bilateral femur fractures. At the time of the neurosurgical evaluation, in the internal medicine ward, he had loss of ambulation, without involvement of the upper limbs.

On examination, the patient presented with crural paraparesis, proximal and distal lower limb strength grade III, mild sensory changes, and preserved deep tendon reflexes. The neuraxial magnetic resonance imaging (MRI) showed an epidural mass lesion, with an hypointense signal on T1- and T2-weighted sequences, with infiltration of the bone and soft parts and associated spinal cord compression at the level of T6, suggestive of brown tumor (→Fig. 1A,B and →Fig. 2).

Based on the clinical picture of spinal cord compression and radiologic data, we opted for surgical treatment, with posterior laminectomy and tumor resection. It was performed a T6 posterior arch laminectomy. A soft consistency brown color insufflating tissue was identified, with bone and soft tissue infiltration. It was compressing the dural sac posteriorly. The surgical procedure was performed uneventfully, with complete removal of the lesion and satisfactory

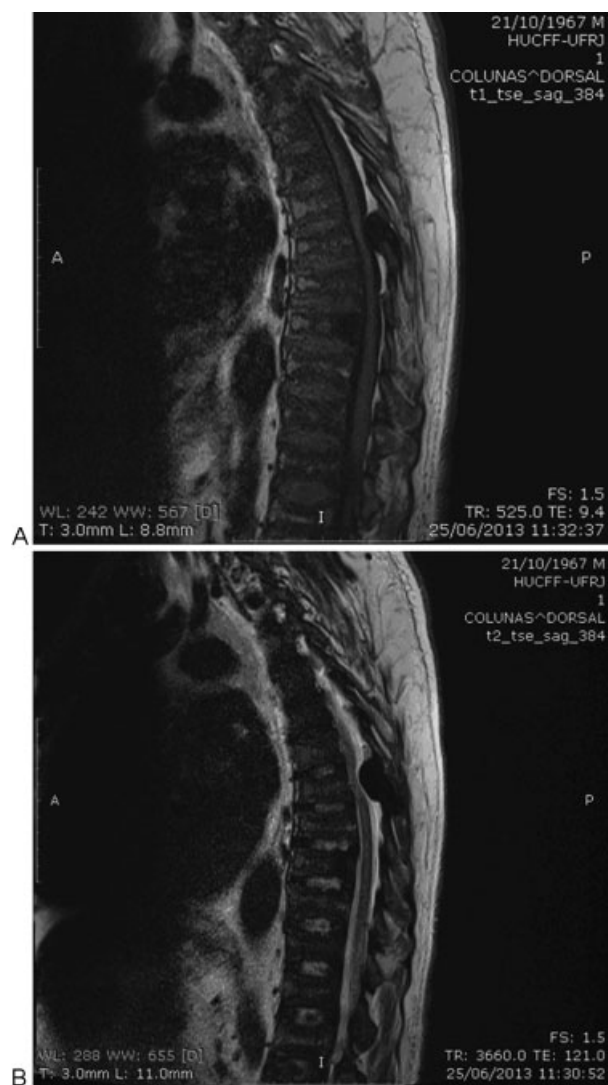


Fig. 1 (A and B) MRI images showing an epidural mass lesion, with an hypointense signal on T1- and T2-weighted sequences, with infiltration of the bone and soft parts and associated spinal cord compression at the level of T6, suggestive of brown tumor.

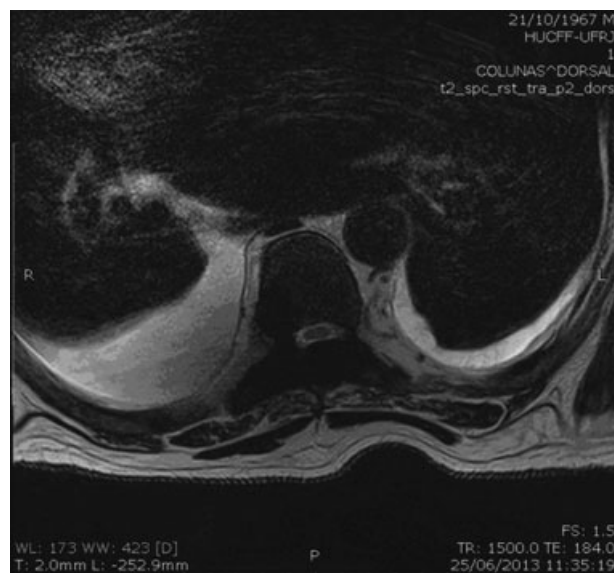


Fig. 2 An axial image showing a lesion affecting the posterior arches, pedicle, and part of the T6 body, on the right.

decompression of the dural sac. Spinal stabilization was not needed. No neurologic worsening occurred after surgery and a little improvement of paraparesis in the immediate post-operative period was observed. The patient is currently in outpatient clinic, with a follow-up period of 3 months after surgery with progressive improvement of the paraparesis.

The macroscopic analysis of the piece revealed irregular fragments of stony, grayish and elastic tissue, measuring together $5.0 \times 5.0 \times 3.0$ cm. The histopathologic analysis of the surgical piece confirmed the initial hypothesis of brown tumor, showing an expansive mass with large numbers of multinucleated giant cells, in a fibroblastic stroma with abundant hemosiderin.

Discussion

The brown tumor is recognized as a non-neoplastic bone reactive process due to increased osteoclastic activity and localized fibroblast proliferation.^{1-7,9-14} Its name derives from its reddish brown appearance, due to microhemorrhages and hemosiderin deposition.¹⁻⁵ The IRC secondary hyperparathyroidism results from injury of calcitriol (1,25-dihydroxyvitamin D3) synthesis, leading to hypocalcemia and phosphate retention and increased production of parathyroid hormone, which can lead to the development of brown tumor.³ Histologically, it presents a fairly vascularized fibroblastic stroma, with numerous multinucleated giant cells similar to osteoclasts and areas of hemorrhage uniformly distributed.¹⁻³ Radiologically, it is characterized by well-defined lytic lesions, that expand or erode the affected bone and may mimic a primary bone tumor or a metastatic lesion.^{15,16} The MRI images show a hypo- to hyperintense on T2-weighted sequences variable signal intensity lesion, resulting from the relative proportion of hemosiderin, hemorrhagic foci, cystic areas, and fibrous stroma.^{15,16} Moreover, its early and intense enhancement on contrast-enhanced T1-weighted dynamic imaging appears to be due to its striking vascularity.^{15,16} In most cases, the correction of hyperparathyroidism leads to a significant regression or even a complete disappearance of the tumor.¹⁻⁵ However, when tumors are large, symptomatic or at risk for pathologic fractures, surgical resection should be considered.^{1-3,5,7,9-11,14}

When the brown tumor involves the spine, it can cause both slowly progressive symptoms due to mass effect, as acute spinal cord compression due to vertebral pathologic fractures.^{3,7} In such cases, the treatment requires surgical resection of the tumor causing spinal cord compression and/or spinal stabilization of the spine, when required.^{3,7}

In this case, the patient presented a significant crural paraparesis and mild sensory changes at the lower limbs, which cannot be attributed only to sequelae of previous femoral fractures. Associated with the clinical picture, the MRI of the spine revealed a significant spinal cord compression at the level of T6, which led us to perform the surgery.

The treatment of brown tumor should be directed to the control of hyperparathyroidism. Although there are insuffi-

cient data until this moment, the surgical decompression should be considered when there is spinal cord compression, especially when the lesion has an easy surgical access. Thus, it is essential to understand this clinical condition that, if not diagnosed and treated early, can lead to irreversible neurologic damage.

Conflicts of Interest

There are no conflicts of interest to declare.

References

- 1 Fargen KM, Lin CS, Jeung JA, Yachnis AT, Jacob RP, Velat GJ. Vertebral brown tumors causing neurologic compromise. *World Neurosurg* 2013;79(1):208.e1-208.e6
- 2 Jackson W, Sethi A, Carp J, Talpos G, Vaidya R. Unusual spinal manifestation in secondary hyperparathyroidism: a case report. *Spine* 2007;32(19):E557-E560
- 3 Tarrass F, Ayad A, Benjelloun M, et al. Cauda equina compression revealing brown tumor of the spine in a long-term hemodialysis patient. *Joint Bone Spine* 2006;73(6):748-750
- 4 Vandenbussche E, Schmider L, Mutschler C, Man M, Jacquot C, Augereau B. Brown tumor of the spine and progressive paraplegia in a hemodialysis patient. *Spine* 2004;29(12):E251-E255
- 5 Noman Zaheer S, Byrne ST, Poonnoose SI, Vrodo NJ. Brown tumour of the spine in a renal transplant patient. *J Clin Neurosci* 2009;16(9):1230-1232
- 6 Araújo SM, Bruin VM, Nunes AS, et al. Multiple brown tumors causing spinal cord compression in association with secondary hyperparathyroidism. *Int Urol Nephrol* 2013;45(3):913-916
- 7 Kaya RA, Cavuşoğlu H, Tanik C, et al. Spinal cord compression caused by a brown tumor at the cervicothoracic junction. *Spine J* 2007;7(6):728-732
- 8 Masutani K, Katafuchi R, Uenoyama K, Saito S, Fujimi S, Hirakata H. Brown tumor of the thoracic spine in a patient on long-term hemodialysis. *Clin Nephrol* 2001;55(5):419-423
- 9 Fineman I, Johnson JP, Di-Patre PL, Sandhu H. Chronic renal failure causing brown tumors and myelopathy. Case report and review of pathophysiology and treatment. *J Neurosurg* 1999;90(2, Suppl):242-246
- 10 Altan L, Kurtoglu Z, Yalçinkaya U, Aydinli U, Ertürk E. Brown tumor of the sacral spine in a patient with low-back pain. *Rheumatol Int* 2007;28(1):77-81
- 11 Pecovnik Balon B, Kavalari R. Brown tumor in association with secondary hyperparathyroidism. A case report and review of the literature. *Am J Nephrol* 1998;18(5):460-463
- 12 Bohlman ME, Kim YC, Egan J, Spees EK. Brown tumor in secondary hyperparathyroidism causing acute paraplegia. *Am J Med* 1986;81(3):545-547
- 13 Yokota N, Kuribayashi T, Nagamine M, Tanaka M, Matsukura S, Wakisaka S. Paraplegia caused by brown tumor in primary hyperparathyroidism. Case report. *J Neurosurg* 1989;71(3):446-448
- 14 Mateo L, Massuet A, Solà M, Pérez Andrés R, Musulen E, Sánchez Torres MC. Brown tumor of the cervical spine: a case report and review of the literature. *Clin Rheumatol* 2011;30(3):419-424
- 15 Adams JE. Renal bone disease: radiological investigation. *Kidney Int Suppl* 1999;73:S38-S41
- 16 Hong WS, Sung MS, Chun KA, et al. Emphasis on the MR imaging findings of brown tumor: a report of five cases. *Skeletal Radiol* 2011;40(2):205-213