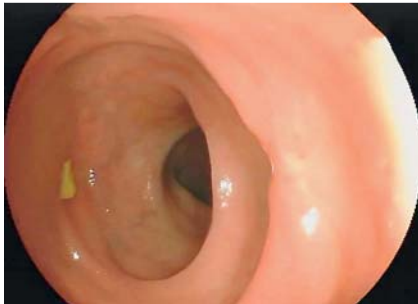

## Endoscopic full-thickness resection for suspected residual rectal neuroendocrine tumor and closure of the defect with a new suturing system



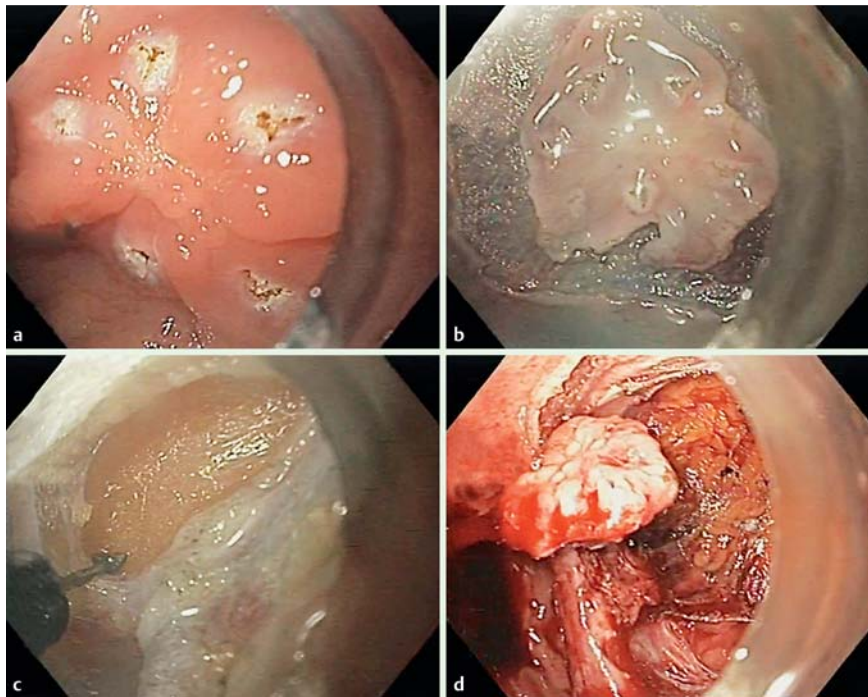
**Fig. 1** Endoscopic view showing a 6-mm scar in the rectum at the site of the previous mucosectomy.



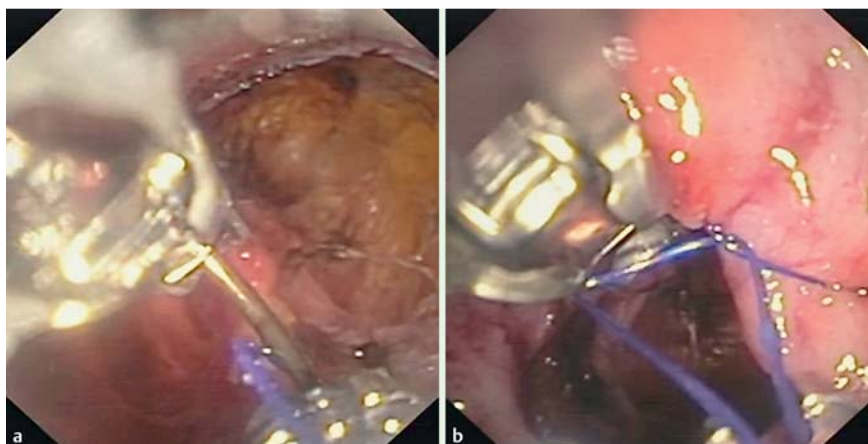
**Fig. 3** The OverStitch endoscopic suturing system.

A 51-year-old white man underwent screening colonoscopy and rectal polypectomy. Histological examination showed a 5-mm neuroendocrine tumor (NET) with a positive vertical margin and a proliferation rate of <2%. Positron emission tomography with gallium (DOTATOC) was negative, and rectal endoscopic ultrasound showed no evidence of pararectal lymph node metastases or residual lesions, even after the use of contrast (SonoVue; Bracco Imaging, Milan, Italy). The final diagnosis was considered to be rectal NET, G1 NO R1.

The patient was admitted to our institution to complete the resection. Further endoscopic examination showed a 6-mm rectal scar, approximately 6 cm above the dentate line with no evidence of macroscopic residual tumor (Fig. 1). A complete en bloc resection of a 2-cm piece of



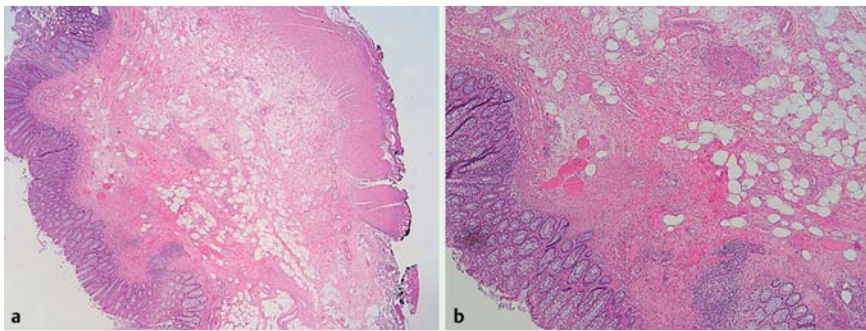
**Fig. 2** Endoscopic views showing: **a** markings that have been made around the margins of the scar; **b** a circumferential incision made with the triangle-tip knife; **c** full-thickness muscle layer being resected down to the mesorectal fat; **d** the lesion almost completely dissected.



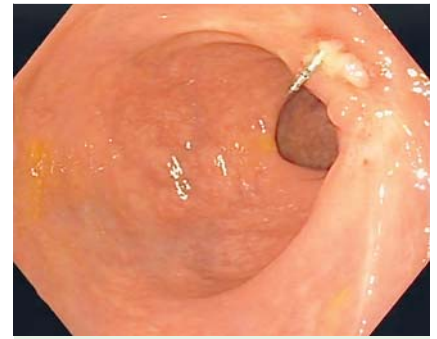
**Fig. 4** Endoscopic views showing: **a** the OverStitch system deploying the first interrupted stitch; **b** the first stitch after its deployment.

rectal wall including the mucosal scar was achieved. Initially a circumferential incision was performed with a triangle-tip knife (Olympus, Tokyo, Japan), then the muscle layers, down to the perirectal fat, were resected with the same device and an IT-knife 2 (Olympus) (Fig. 2; Video 1)

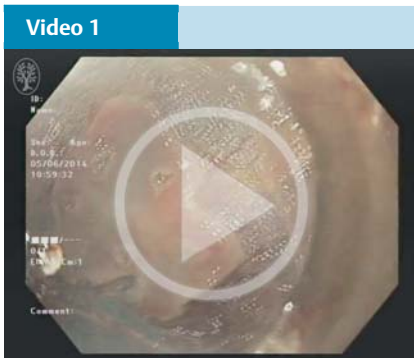Primary closure was achieved using the OverStitch endoscopic suturing system (Apollo Endosurgery, Austin, Texas, USA) (Fig. 3 and Fig. 4; Video 2 and Video 3), which has been available in Europe since 2013 and has demonstrated safety and efficacy in several clinical situations, such as anastomotic dehisc-



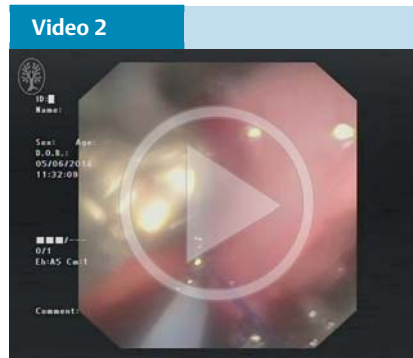
**Fig. 5** Histological views of the hematoxylin and eosin (H&E)-stained resection specimen showing: **a** full-thickness resection from mucosa to muscularis propria, with no residual neuroendocrine tumor (magnification  $\times 20$ ); **b** complete mucosal re-epithelialization with fibrous healing tissue in the submucosa (magnification  $\times 50$ ).



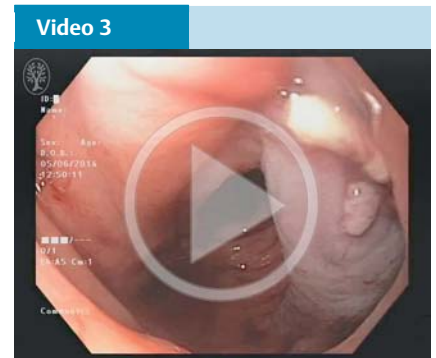
**Fig. 6** Image from the endoscopic re-evaluation 3 months later showing a linear scar with an anchor attached and some granulation tissue.



**Video 1**  
Endoscopic full-thickness resection of a rectal scar with suspected residual neuroendocrine tumor being carried out.



**Video 2**  
The OverStitch endoscopic suturing system being used to deploy the first stitch.



**Video 3**  
The final appearance following complete closure of the defect with the OverStitch endoscopic suturing system.

cence, fistula, stent migration, and iatrogenic perforations [1], as well as after endoscopic submucosal dissection in humans [2] and full-thickness gastric resection in a porcine model [3]. The procedure was completed without adverse events and the patient was discharged after 3 days.

The resected specimen showed no residual tumor, probably because of the destruction of residual neoplastic cells by the cauterization that was used during the first endoscopic resection (Fig. 5). A follow-up endoscopy 5 months after the procedure showed the presence of a linear scar with a residual metal anchor and its suture thread attached. Nearby a minimal amount of granulation tissue was found to have developed (Fig. 6).

Small rectal NETs (G1) can be resected endoscopically and complete resection is the only curative management [4]. This case demonstrated that endoscopic full-thickness resection is safe and effective for achieving a complete resection in the rectum and that the use of the OverStitch system is a good alternative when closing rectal wall defects.

Endoscopy\_UCTN\_Code\_TTT\_1AQ\_2AG

**Competing interests:** None

**Francesco Azzolini<sup>1</sup>, Paolo Cecinato<sup>1</sup>, Veronica Iori<sup>1</sup>, Loredana De Marco<sup>2</sup>, Romano Sassatelli<sup>1</sup>**

<sup>1</sup> Unit of Gastroenterology and Digestive Endoscopy, Arcispedale Santa Maria Nuova-IRCCS, Reggio Emilia, Italy

<sup>2</sup> Unit of Pathology, Arcispedale Santa Maria Nuova-IRCCS, Reggio Emilia, Italy

## References

- 1 Sharaiha RZ, Kumta NA, Kedia P et al. A large multicenter experience with the OverStitch device for endoscopic management of gastrointestinal strictures, defects and stent anchorage in 95 patients. *Gastrointest Endosc* 2014; 79 Suppl.: AB257
- 2 Kantsevov SV, Bitner M, Mitrov AA et al. Endoscopic suturing closure of large mucosal defects after endoscopic submucosal dissection is technically feasible, fast, and eliminates the need for hospitalization (with videos). *Gastrointest Endosc* 2014; 79: 503–507

- 3 Kobayashi M, Sumiyama K, Ban Y et al. Closure of iatrogenic large mucosal and full-thickness defects of the stomach with endoscopic interrupted sutures in in vivo porcine models: are they durable enough? *BMC Gastroenterol* 2015; 15: 5

- 4 Caplin M, Sundin A, Nilsson O et al. Barcelona Consensus Conference participants. ENETS Consensus Guidelines for the management of patients with digestive neuroendocrine neoplasms: colorectal neuroendocrine neoplasms. *Neuroendocrinology* 2012; 95: 88–97

## Bibliography

DOI <http://dx.doi.org/10.1055/s-0034-1393384>  
*Endoscopy* 2015; 47: E556–E557  
 © Georg Thieme Verlag KG  
 Stuttgart · New York  
 ISSN 0013-726X

## Corresponding author

**Francesco Azzolini, MD**  
 Unit of Gastroenterology and Digestive Endoscopy  
 Arcispedale Santa Maria Nuova-IRCCS  
 Reggio Emilia, 42123  
 Italy  
 Fax: +39-0522-295941  
 francesco.azzolini@asmn.re.it