

Closure of a large mucosal defect after endoscopic submucosal dissection using “pre-detached loop and clips” method with a single-channel gastro-scope

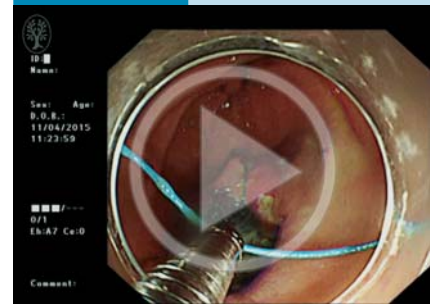
Endoscopic submucosal dissection (ESD) is commonly used for the treatment of early gastric neoplasms. However, there are reports indicating an increase in serious complications, such as perforation and delayed bleeding [1]. Various methods have been introduced to close the large mucosal defect after ESD, such as a simple closure method with metal clips or the “loop and clips” method [2]. Many authors prefer the loop and clips technique for closure of larger post-ESD mucosal defects, but this requires a two-channel endoscope and is technically more difficult. In this report, we describe a newly developed pre-detached loop technique as an easy and safe alternative method.

A 50-year-old woman underwent ESD of a gastric submucosal tumor. A gastroscope (GIF-Q260J; Olympus Medical Systems,

Tokyo, Japan) with a transparent cap (D-201-10704; Olympus) attached to the tip was used. Other accessories included an electro-surgical knife (DualKnife; Olympus), metal clips (HX-600-90; Olympus), and an endoloop (MAJ-339; Olympus). The 1.2-cm tumor was excised completely using the ESD method, as described previously [3]. For closure of the mucosal defect, an improvised version of the loop and clips technique was used. First, the loop was secured with a metal clip and inserted into the endoscope's single working channel. The loop was positioned around the defect under direct endoscopic vision. Five metal clips were then used to anchor the endoloop around the edge of the mucosal defect. The endoloop tail was then grasped by an endoloop hook device and tightened to close the

defect in a purse-string fashion (▶ Fig. 1). The closing process took about 5 minutes and was accomplished without technical difficulty. The subsequent clinical course of the patient was uneventful. In summary, the loop could be deployed in a freehand manner (pre-detached) to provide more flexibility while maneuvering the position of the clip and without shifting the loop (▶ Video 1).

Video 1



Endoscopic submucosal dissection of a gastric submucosal tumor was performed. The large gastric mucosal defect was closed using a pre-detached endoloop and clip technique. The efficacy of this method was similar to the original endoloop and clip method, but the procedure was easier and allowed more maneuverability.

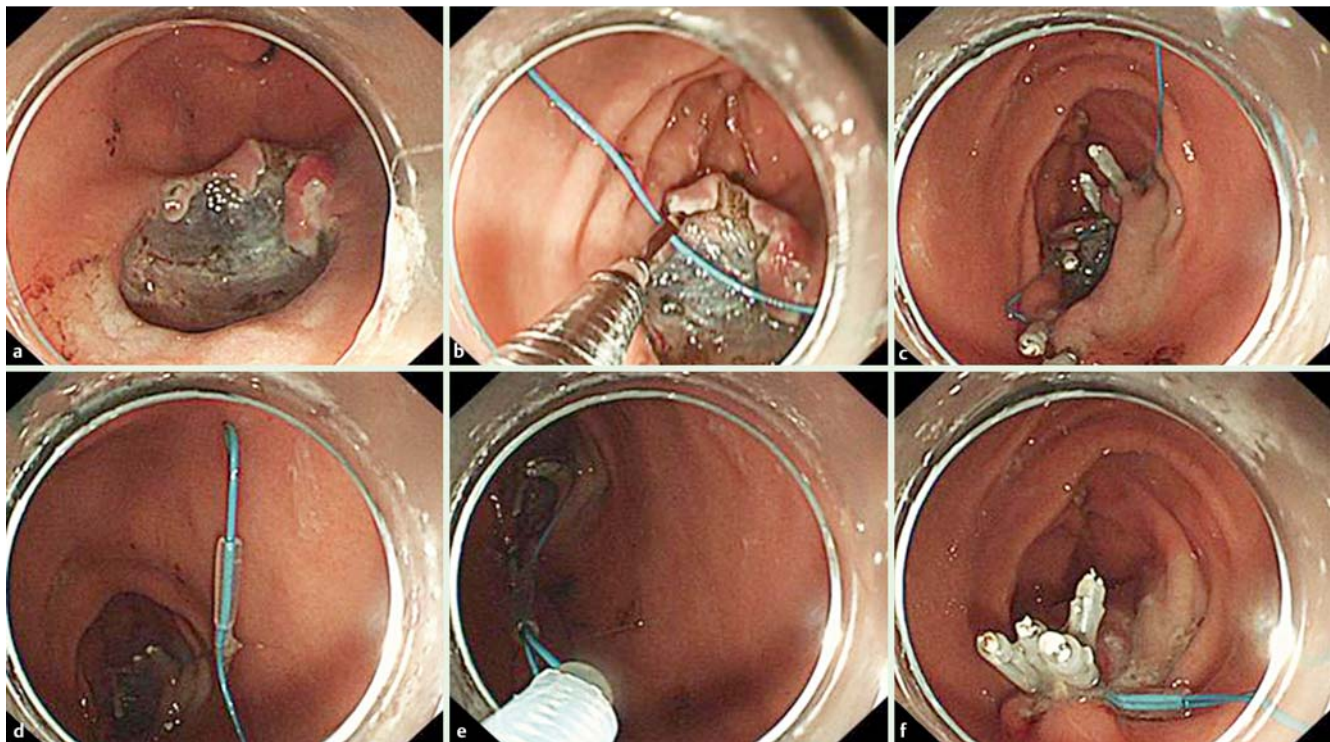


Fig. 1 The procedure of pre-detached endoloop and clip technique for closure of a large gastric mucosal defect. **a** Endoscopy showed a large gastric mucosal defect after endoscopic submucosal dissection. **b** A pre-detached endoloop was inserted and anchored to the edge of the defect using a metal clip (all deployed via a single working channel). **c** Five metal clips were used to anchor the endoloop around the edge of the mucosal defect. **d** Once the loop ligature was in place, the tail of the loop was identified. **e** The endoloop tail was grasped by an endoloop hook device and pulled backward to tighten the loop. **f** The loop was fastened, and the defect was closed in a purse-string manner.

Endoscopy_UCTN_Code_TTT_1AO_2AG

Competing interests: None

Guan Way Lua¹, Feng Liu²

¹ Department of Gastroenterology,
Raja Perempuan 2 Hospital, Kelantan,
Malaysia

² Department of Gastroenterology,
Changhai Hospital, Shanghai, China

References

- 1 Tokoyama T, Omote S, Okamoto A et al. Risk factors for perforation and delayed bleeding associated with endoscopic submucosal dissection for early gastric neoplasms. *J Gastroenterol Hepatol* 2012; 27: 907–912
- 2 Endo M, Inomata M, Terui T et al. New endoscopic technique to close large mucosal defects after endoscopic mucosal resection in patients with gastric mucosal tumors. *Dig Endosc* 2004; 16: 372–375
- 3 Biłek A, Wiechowska-Kozłowska A, Pertkiewicz J et al. Endoscopic submucosal dissection for treatment of gastric subepithelial tumors. *Gastrointest Endosc* 2012; 75: 276–286

Bibliography

DOI <http://dx.doi.org/10.1055/s-0034-1392869>
Endoscopy 2015; 47: E464–E465
© Georg Thieme Verlag KG
Stuttgart · New York
ISSN 0013-726X

Corresponding author

Feng Liu, MD

Department of Gastroenterology
Changhai Hospital
Second Military Medical University
168 Changhai Road
Shanghai
China
Fax: +86-21-55621735
drluiffeng@hotmail.com