Gastroscopic removal of intrahepatic stones through a large choledochoduodenal fistula

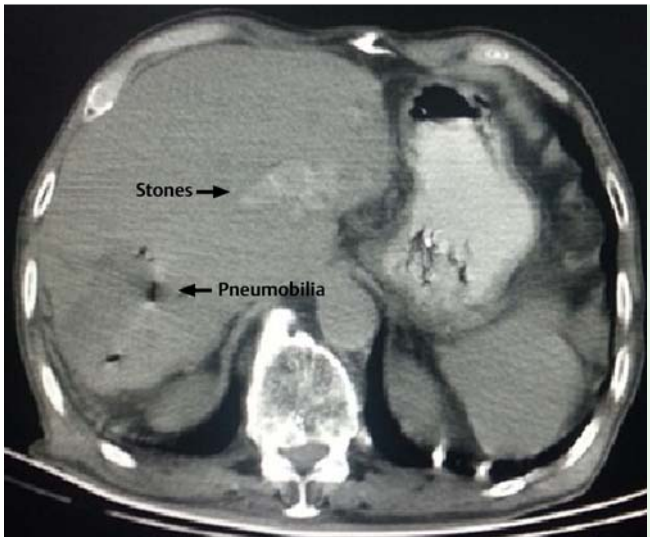

Fig. 1 Computed tomography reveals pneumobilia and intrahepatic stones in an 89-year-old man with fever of 3 days' duration and symptoms of cholangitis and cholelithiasis. The patient had undergone cholecystectomy and common bile duct exploration 30 years previously because of gallstone disease.

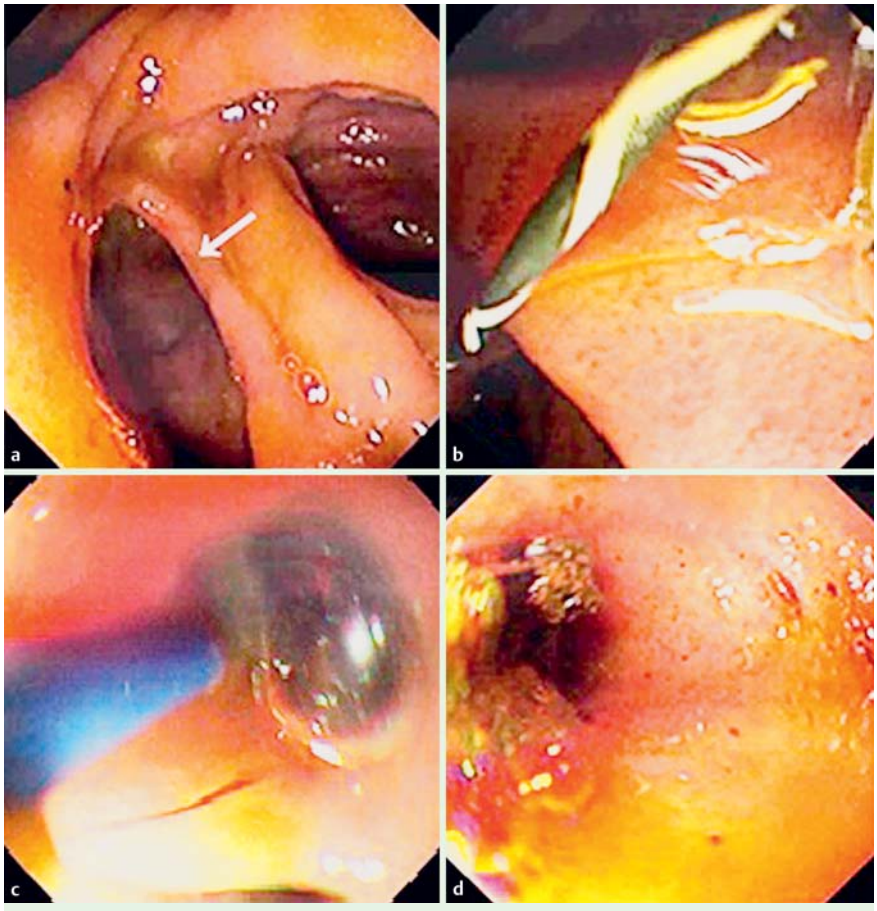

Fig. 2 **a** Fistulous opening in the interior wall of the descending duodenum (arrow). **b** Successful placement of a guidewire in the fistula with a duodenoscope. **c** Insertion of a gastroscope into the bile duct over a balloon catheter. **d** Intrahepatic biliary stone removal with a stone extractor.

An 89-year-old man was admitted to the hospital with fever of 3 days' duration. He had undergone cholecystectomy and common bile duct exploration 30 years earlier because of gallstone disease. The patient also had symptoms of cholangitis and cholelithiasis (▶ **Fig. 1**).

Considering his advanced age, we planned to perform endoscopic retrograde cholangiopancreatography (ERCP) first to relieve his symptoms and reduce the inflammatory reaction. After inserting a duodenoscope, we found a fistulous orifice, about 1.5 cm in diameter, located in the descending duodenum. Guidewire placement and radiography confirmed the presence of a choledochoduodenal fistula (CDF) (▶ **Fig. 2 a, b** and ▶ **Fig. 3 a, b**).

We then exchanged the duodenoscope for a gastroscope. The gastroscope, with a 7.5-Fr Tri-Ex Extraction Balloon (Cook Medical, Winston-Salem, North Carolina, USA) in the working channel, was inserted over the guidewire into the intrahepatic bile duct (▶ **Fig. 2 c** and ▶ **Fig. 3 c**) under radiographic guidance. Under optical view and with radiographic confirmation, after the narrow part of the bile duct had been dilated, stones, debris, and pus were removed from the distal biliary tract with the use of a retrieval basket and the extraction balloon (▶ **Fig. 2 d** and ▶ **Fig. 3 d, e**; ▶ **Video 1**). Because of the patient's advanced age, nasobiliary drainage was performed (▶ **Fig. 3 f**), and he underwent the same procedure once again 1 week later. He recovered very quickly after these procedures.

CDF has long been detected during endoscopy [1]. Most of the time, gallstones are the direct cause of CDF. Endoscopy is the best and most precise method of diagnosing CDF, although computed tomography

Video 1

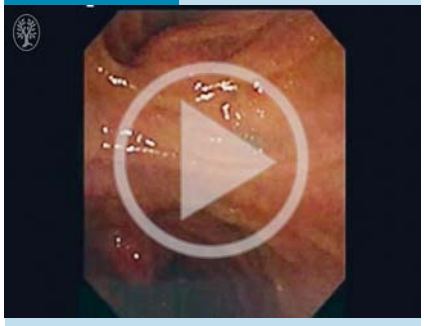

Gastroscopic removal of intrahepatic stones through a large choledochoduodenal fistula.

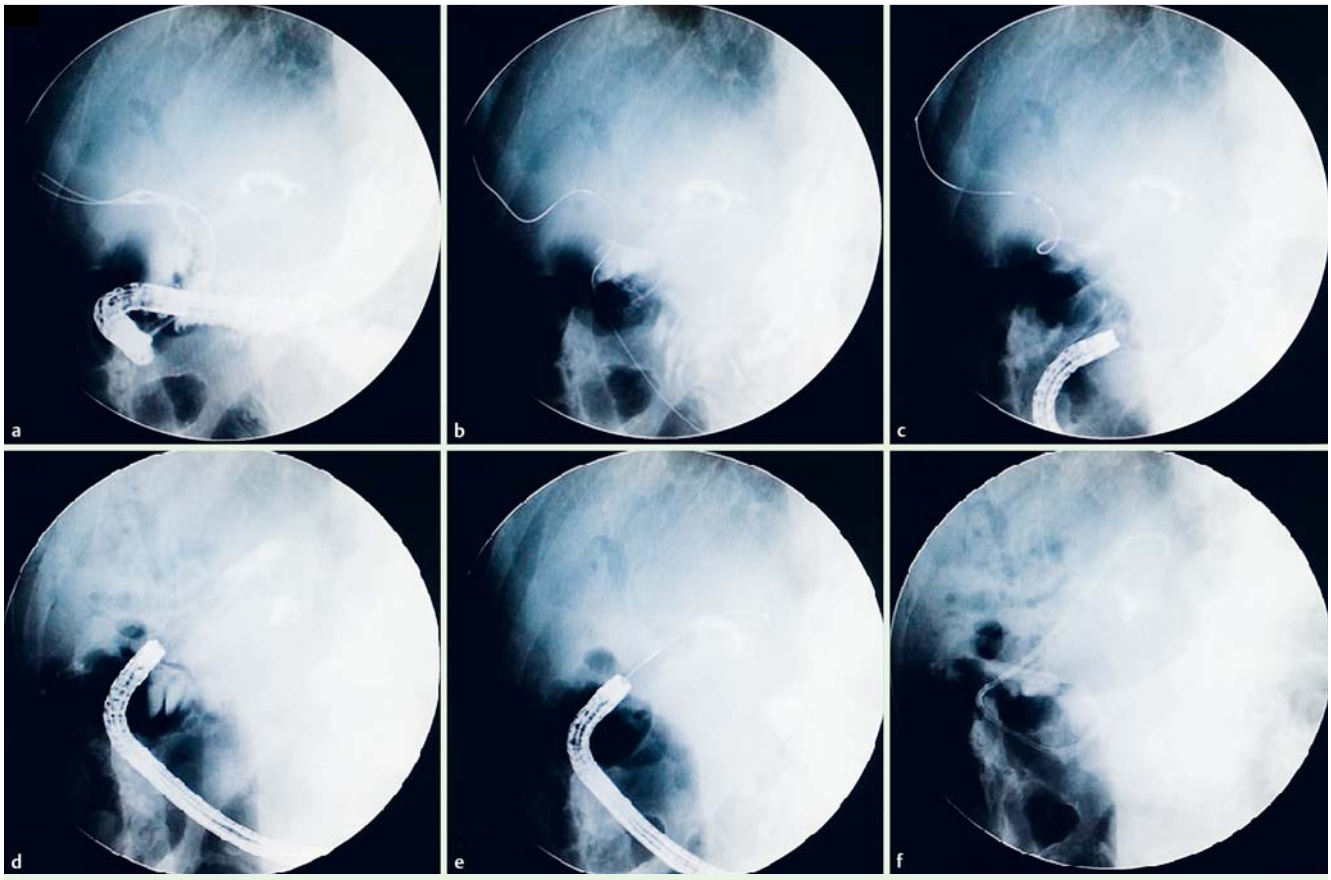

Fig. 3 **a** Cholangiography with the duodenoscope. **b** Guidewire in the bile duct. **c** Cannulation of the gastroscope over the balloon catheter and guidewire. **d** Balloon dilation of the narrow part in left intrahepatic bile duct. **e** Biliary stone removal with a stone extractor. **f** Endoscopic nasobiliary drainage.

is sometimes also useful [2]. This elderly patient's large fistula provided us with a good way to solve his problem. It appears that our case is unusual, but the operation did make it possible to avoid many of the complications, such as acute pancreatitis and bleeding, of catheterization and sphincterotomy of the papilla, and it saved an elderly man's life. We hope that this case will highlight the benefits of using a gastroscope in patients with CDF and complicated cholelithiasis.

Endoscopy_UCTN_Code_CCL_1AZ_2AZ

Competing interests: None

Lichao Zhang, Jiansheng Kang, Zhanying Qiao, Jun Guo, Senlin Hou

Department of Minimally Invasive Surgery, 2nd Hospital of Hebei Medical University, Shijiazhuang, Hebei Province, China

References

1 *Ikeda S, Okada Y.* Classification of choledochoduodenal fistula diagnosed by duodenal fiberscopy and its etiological significance. Gastroenterology 1975; 69: 130 – 137

2 *Tonolini M.* Spontaneous pneumobilia revealing choledocho-duodenal fistula: a rare complication of peptic ulcer disease. J Emerg Trauma Shock 2013; 6: 146 – 147

Bibliography

DOI http://dx.doi.org/10.1055/s-0034-1392426
Endoscopy 2015; 47: E361–E362

ISSN 0013-726X

Corresponding author
Senlin Hou, MD
Department of Minimally Invasive Surgery
2nd Hospital of Hebei Medical University
Shijiazhuang, 050000
Hebei Province
China
Fax: +86-0311-66003995
27307241@qq.com