

Fatal aortic hemorrhage after over-the-scope clipping and subsequent esophageal stenting for sealing of iatrogenic esophageal perforation

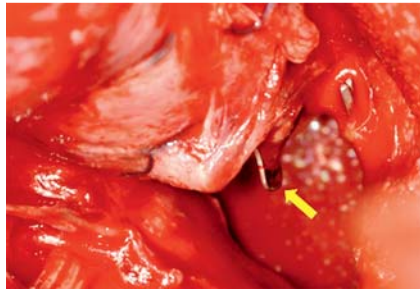


Fig. 1 Intraoperative image of the distal esophagus within the enlarged diaphragmatic hiatus. The migrated clip is clearly visible through the esophageal perforation (yellow arrow).

Endoscopic fixation using over-the-scope clips (OTSCs) is mostly done to prevent migration of esophageal stents placed in the absence of a stenosis [1–4]. Additional stenting of areas treated with OTSCs has not yet been described.

During fundoplication in a 64-year-old woman, intact esophageal submucosa was exposed. The area was covered by the fundoplication cuff. On postoperative Day 8, endoscopy showed a 3-mm esophageal leak proximal to the fundoplication cuff. It was closed using an OTSC. In addition, a self-expandable, fully covered, removable stent (SX-ELLA Danis; Ella-CS, Hradec Kralove, Czech Republic) was positioned over the closed leak to reinforce the esophageal wall at this weak point. The stent was not fixed, and 7 days later endoscopy showed slight stent dislocation. With the help of the purse string, the stent was repositioned 5 cm in the proximal direction. Sepsis developed after 5 days, but there was no detectable leakage of contrast medium on computed tomography (CT) scan. The following day, the patient had sudden massive hematemesis and underwent emergency transfer to our hospital.

Emergency surgery revealed that the clip had rotated by almost 180 degrees and one branch had protruded toward the aorta, causing an irreparable esophagoaortic fistula (Fig. 1). Emergency esophagectomy was performed to expose

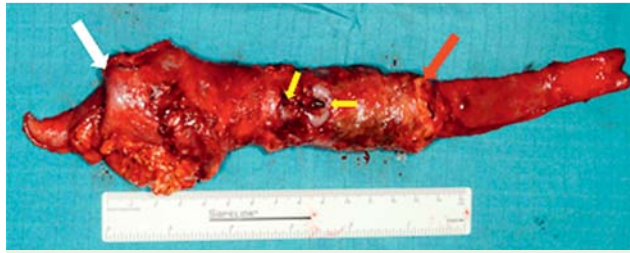

Fig. 2 Resected esophageal specimen containing the implanted esophageal stent (cranial margin: red arrow; bulged out caudal margin: white arrow) and the migrated clip through the esophageal leak (yellow arrows).

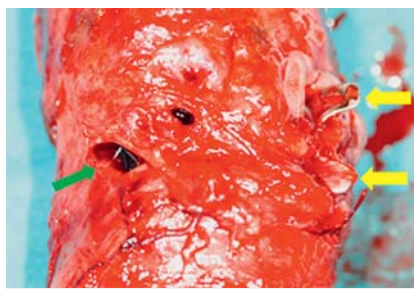


Fig. 3 Enlarged view of the resected esophagus. Esophageal perforation with the protruding mucosa around the migrated clip (yellow arrows). Second perforation sealed by the covered self-expandable esophageal stent (green arrow).

the aorta for repair. However, the aortic wall had become weakened by inflammation and necrosis, and could not be closed by any of the techniques available for vascular and cardiac surgery.

The resected specimen showed that the rotated clip had migrated in part through the esophageal leakage (Fig. 2, Fig. 3). In addition, a second leak, which was well covered by the stent, was present. In retrospect, the rotation of the clip was visible on the CT scan (Fig. 4).

In this case of esophageal stenting after OTSC clipping, the branches of the clip presumably engaged with the stent mesh, which caused its rotation when the stent was deployed. The inflammatory process following leakage caused additional weakening of the aorta. Stenting of clipped areas does not seem to be advisable.

Endoscopy_UCTN_Code_CPL_1AH_2AJ

Competing interests: None

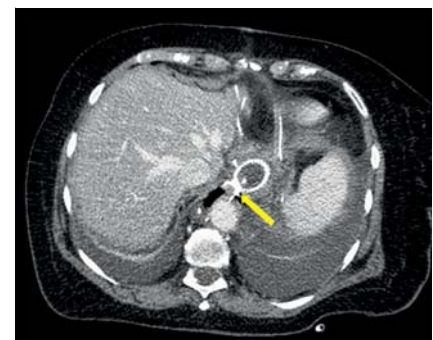

Fig. 4 Computed tomography scan showing the implanted esophageal stent and the rotated branch protruding toward the aorta (yellow arrow).

Joerg Lindenmann, Alfred Maier, Nicole Fink-Neuboeck, Freyja Maria Smolle-Juettner

Division of Thoracic and Hyperbaric Surgery, Department of Surgery, Medical University Graz, Austria

References

- 1 Toshniwal J, Zabielski M, Fry LC et al. Combination of the “bear claw” (over-the-scope-clip system) and fully covered stent for the treatment of post-operative anastomotic leak. *Endoscopy* 2012; 44 (Suppl. 02): E288–E289
- 2 Irani S, Baron TH, Gluck M et al. Preventing migration of fully covered esophageal stents with an over-the-scope clip device (with videos). *Gastrointest Endosc* 2014; 79: 844–851
- 3 Mudumbi S, Velazquez-Aviña J, Neumann H et al. Anchoring of self-expanding metal stents using the over-the-scope clip, and a technique for subsequent removal. *Endoscopy* 2014; 46: 1106–1109

4 Diana M, Swanström LL, Halvax P et al. Esophageal covered stent fixation using an endoscopic over-the-scope clip. Mechanical proof of the concept and first clinical experience. *Surg Endosc*. In press 2015. DOI: 10.1007/s00464-015-4078-0

Bibliography

DOI <http://dx.doi.org/10.1055/s-0034-1391954>
Endoscopy 2015; 47: E280–E281
© Georg Thieme Verlag KG
Stuttgart · New York
ISSN 0013-726X

Corresponding author

Joerg Lindenmann, MD
Division of Thoracic and Hyperbaric Surgery
Medical University Graz
Auenbruggerplatz 29
8036 Graz
Austria
Fax: +43-316-38514679
jo.lindenmann@medunigraz.at