

Polyglycolic acid sheets for repair of refractory esophageal fistula

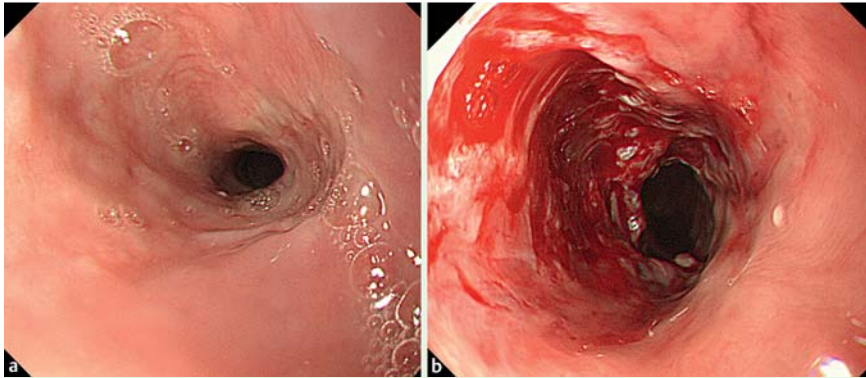


Fig. 1 **a** Endoscopic view of a moderate stricture around the scar 35 days after endoscopic submucosal dissection (ESD) of a superficial carcinoma in the midthoracic esophagus. **b** Lacerated wound and oozing blood recognized just after balloon dilation of the stricture.

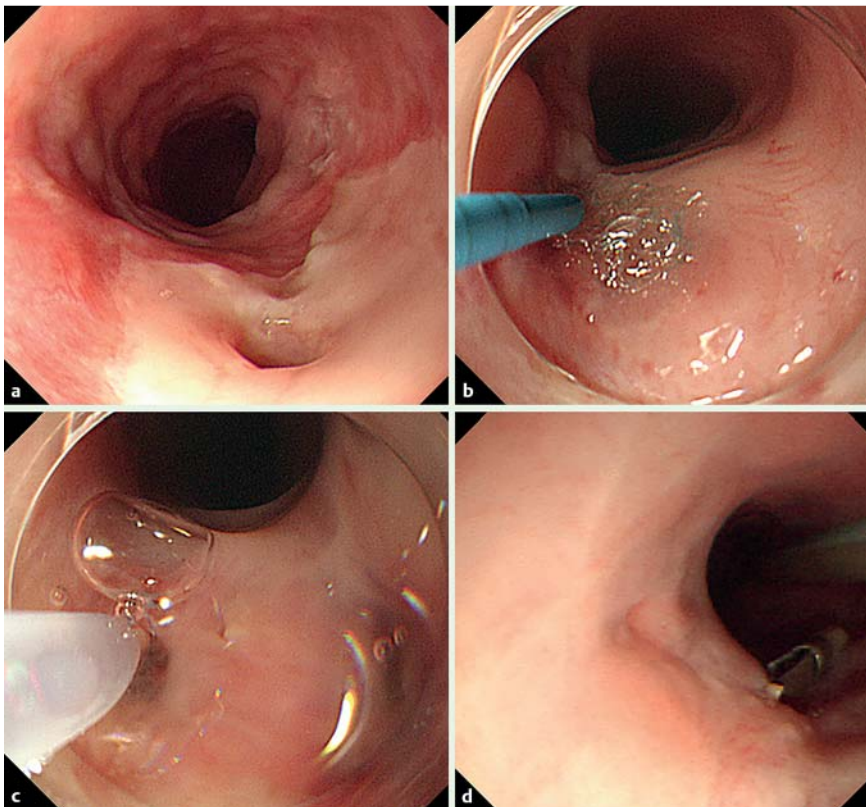


Fig. 2 **a** Endoscopic view 8 days after perforation shows a deep fistula. **b** Polyglycolic acid (PGA) sheets were cut to 4×3 mm in advance, delivered with biopsy forceps, and stuffed into the fistula using a tapered catheter (PR-110Q; Olympus, Japan). **c** Fibrin glue seeping into the PGA fragments. **d** The fistula had remained closed 5 days after the procedure.

Gastrointestinal fistulas have been treated endoscopically with various devices, but endoscopic management is occasionally difficult [1]. Here we report a case of refractory esophageal fistula successfully

closed using polyglycolic acid (PGA) sheets.

A 61-year-old man with superficial carcinoma in the midthoracic esophagus was referred to our hospital. Endoscopic sub-

mucosal dissection (ESD) was performed with subsequent intralesional steroid injection (triamcinolone acetonide 80mg) to prevent post-ESD stricture [2]. Histopathological diagnosis of the lesion was squamous cell carcinoma (pT1a-MM, ly0, v0, HM0, VM0) and no additional treatment was performed.

The patient complained of dysphagia 35 days after ESD. Endoscopic examination showed moderate stricture (● Fig. 1 a), and endoscopic balloon dilation was done using the CRE balloon dilator (Boston Scientific Co, Japan). However this resulted in perforation (● Fig. 1 b) followed by subcutaneous and mediastinal emphysema. Fistula formation was observed 8 days after perforation (● Fig. 2 a). Conservative management and four attempts at endoscopic clip closure were ineffective. Contrast radiography 44 days after perforation showed pooling of contrast agents in the mediastinum through the fistula. Therefore, we prepared three pieces of PGA sheet (Neoveil; Gunze Co, Japan). These were cut to 4×3 mm and stuffed into the fistula (● Fig. 2 b). Using the PGA as scaffolding, we filled in the gaps with fibrin glue (Bolheal; Astellas Pharma, Japan) (● Fig. 2 c), and then closed the fistula using endoclips. At 5 days after the procedure, the fistula was seen to be filled with granulation tissue (● Fig. 2 d), and oral intake was started. The patient was discharged 18 days after the procedure. Neither fistula nor emphysema was observed at follow-up computed tomography (CT) 1 month after the procedure.

PGA sheeting has been used to prevent delayed perforation after duodenal or colorectal ESD [3,4], because it acts as a scaffold for migrating cells, and is absorbed spontaneously. This case suggests a novel further use for PGA sheets in endoscopic therapy.

Endoscopy_UCTN_Code_TTT_1AO_2AI

Competing interests: None

Yoshiki Tsujii, Motohiko Kato, Shinichiro Shinzaki, Atsuo Takigawa, Yoshito Hayashi, Tsutomu Nishida, Hideki Iijima, Masahiko Tsujii, Tetsuo Takehara

Department of Gastroenterology and Hepatology, Osaka University Graduate School of Medicine, Suita, Japan

References

- 1 Raju GS. Endoscopic clip closure of gastrointestinal perforations, fistulae, and leaks. *Dig Endosc* 2014; 26 (Suppl. 01): 95–104
- 2 Hanaoka N, Ishihara R, Takeuchi Y et al. Intralesional steroid injection to prevent stricture after endoscopic submucosal dissection for esophageal cancer: a controlled prospective study. *Endoscopy* 2012; 44: 1007–1011
- 3 Takimoto K, Toyonaga T, Matsuyama K. Endoscopic tissue shielding to prevent delayed perforation associated with endoscopic submucosal dissection for duodenal neoplasms. *Endoscopy* 2012; 44 (Suppl. 02): E414–E415
- 4 Tsuji Y, Ohata K, Gunji T et al. Endoscopic tissue shielding method with polyglycolic acid sheets and fibrin glue to cover wounds after colorectal endoscopic submucosal dissection (with video). *Gastrointest Endosc* 2014; 79: 151–155

Bibliography

DOI <http://dx.doi.org/10.1055/s-0034-1390914>
Endoscopy 2015; 47: E39–E40
© Georg Thieme Verlag KG
Stuttgart · New York
ISSN 0013-726X

Corresponding author

Tetsuo Takehara, MD, PhD

Department of Gastroenterology and Hepatology
Osaka University Graduate School of Medicine
2-2 Yamadaoka, Suita
Osaka 565-0871
Japan
Fax: +81-6-68793629
takehara@gh.med.osaka-u.ac.jp