Valve-Sparing Reimplantation Technique for Treatment of Neoaortic Root Dilatation Late after the Arterial Switch Operation: Raising the Bar

Markus Liebrich[1,2] Michael Scheid[1,2] Frank Uhlemann[3] Wolfgang B. Hemmer[1,2]

[1] Department of Cardiac Surgery, Sana Cardiac Surgery Stuttgart, Stuttgart, Germany
[2] Department of Congenital Cardiac Surgery, Sana Cardiac Surgery Stuttgart, Stuttgart, Germany
[3] Department of Pediatric Cardiology/Pulmonology and Intensive Care Medicine, Klinikum Stuttgart Olgahospital, Stuttgart, Germany

Address for correspondence Ioannis Tzanavaros, MD, Department of Cardiac Surgery, Sana Cardiac Surgery Stuttgart, Herdweg 2 Stuttgart 70174, Germany (e-mail: i.tzanavaros@sana.de).

Thorac Cardiovasc Surg Rep 2014;3:16–18.

Abstract

Neoaortic root dilatation can develop during long-term follow-up after an arterial switch operation (ASO). Although few patients require surgical reintervention, significant valve regurgitation is still an important cause of late morbidity. We report on a 15-year-old boy with significant dilatation of the neoaortic root that was treated with the valve-sparing reimplantation technique. There is only one reported case of valve-preserving surgery late after the ASO. Valve preservation is believed to be superior to valve replacement in patients with aortic regurgitation due to better hemodynamic performance and avoidance of anticoagulation therapy.

Keywords
- transposition of the great arteries
- arterial switch operation
- valve-sparing reimplantation technique

Introduction

Since its introduction by Jatene and colleagues in 1976, the arterial switch operation (ASO) has become the procedure of choice for surgical repair of d-loop transposition of the great arteries (TGA) in neonates and infants.[1] However, even following successful repair, patients are at risk for long-term complications, concerning pathology of the native pulmonary root/valve in the systemic position functioning as the neoaortic root and valve, respectively.[2] The incidence of neoaortic root dilatation and neoaortic valve regurgitation is considered by some authors to be stable. However, there are increasing reports where neoaortic root dilatation and/or neoaortic valve regurgitation are considered progressive over time and this raises concerns about the need for late reoperation.[3,4] The valve-sparing reimplantation technique was first described by David and Feindel to treat patients with aortic regurgitation and ascending aortic aneurysm and has demonstrated excellent long-term outcomes in different valve pathologies.[5,6] These results inspired us to extend the indications for this operative technique. We report the use of the valve-sparing reimplantation technique in a patient with neoaortic root dilatation and concomitant neoaortic valve regurgitation arising late after the ASO.

Case Report

The patient, a 15-year-old boy, was born with a TGA, double-outlet right ventricle, subpulmonary ventricular septal defect (VSD), atrial septal defect (ASD), and aortic coarctation. A balloon atrial septostomy was performed on his 2nd day of life followed by ligation of patent ductus arteriosus, pulmonary artery (PA) banding, and aortic coarctation repair at 4 days. At the age of 3 months, he subsequently had an ASO, VSD/ASD closure, and PA debanding. He did well until the age of 15 years, when his passion for inline speed skating increased. Clinically, the patient was New York Heart

received
May 26, 2014
accepted after revision
June 16, 2014
published online
September 4, 2014

DOI http://dx.doi.org/10.1055/s-0034-1387130.
ISSN 2194-7635.

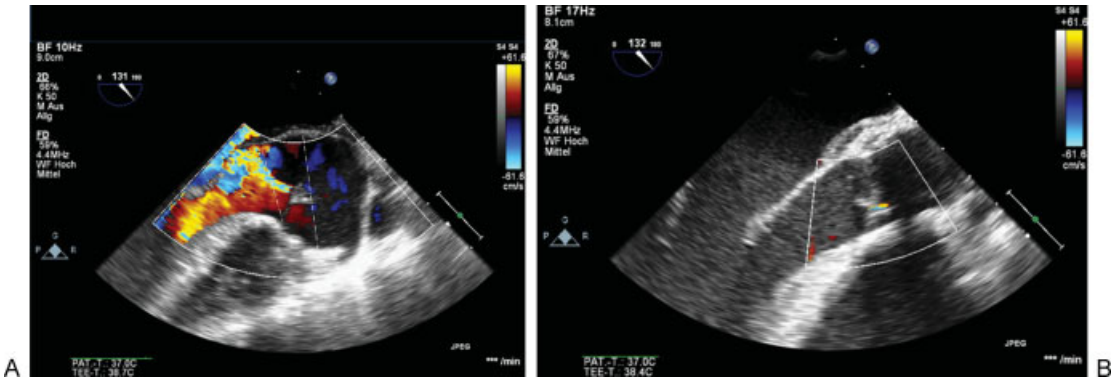

Fig. 1 (A) Preoperative echocardiography demonstrated a prolapse of the right coronary cusp into the left ventricular outflow tract, concomitant eccentric turbulent jet toward the anterior mitral leaflet, and an aneurysm of sinus of Valsalva. (B) Color Doppler examination showed trivial, central aortic regurgitation with well coapted neoaortic leaflets after valve-sparing reimplantation technique.

Association (NYHA) class II and he was found to have significant neoaortic root dilatation and concomitant neoaortic valve regurgitation. His neoaortic root dilatation, initially diagnosed at the age of 3 years, had gradually increased on serial echocardiography. His coronary anatomy was Yacoub type B; both coronary arteries arose from a common ostium in close relation to the anterior aortic commissure from the left anterior aortic sinus (1RLCx). Transesophageal echocardiography clearly delineated the diameter of the neoaortic root with 33 mm at the annulus level and 49 mm at the sinus of Valsalva with an eccentric regurgitant jet directed toward the anterior mitral valve leaflet (►**Fig. 1**). Rethoracotomy was carefully performed, and after systemic heparinization, an arterial cannula was inserted into the distal ascending aorta, and a two-stage venous cannula was inserted through the right atrium. Cardiopulmonary bypass was established, and cardioplegic arrest was achieved and maintained by infusion of antegrade and retrograde cold blood cardioplegia. The left PA was divided to facilitate sufficient exposure of the dilated aortic root and ascending aorta. The former fragile pulmonary trileaflet valve had remodeled over time toward an aortic phenotype with development of noduli Arantii (►**Fig. 2**). After excision of the mono-ostium, the aortic sinuses were resected. The proximal anastomosis was performed using horizontal U-stitches placed circumferentially through the left ventricular outflow tract using Teflon felts. The valve was reimplanted into the prosthesis (28 mm Hemashield, Natick, Massachusetts, United States) using a continuous suture line following the scalloped shape of the free margin of the native valve (►**Fig. 2**). A relevant prolapse of the free margin of the right coronary cusp was reconstructed by a central plication along the nodule of Arantius (W.L. Gore & associates, Flagstaff, Arizona, United States). The single ostium was implanted into the graft with a 5–0 Prolene (Ethicon, Norderstedt, Germany) running suture. The patient was weaned from cardiopulmonary bypass with low-dose inotropes. The postoperative course was uneventful, and the patient was discharged from hospital on postoperative day 8. The 1-month postoperative echocardiography showed good neoaortic valve and left ventricular function, with a mean gradient of 7 mm Hg, and trivial central aortic regurgitation (►**Figs. 1** and **3**). The patient was NYHA functional class I.

Comment

In this report, we present the use of the valve-sparing reimplantation technique to allow the neoaortic valve to be maintained late after an ASO. Progressive neoaortic/pulmonary dilatation and concomitant valve regurgitation in the aortic position remains a major drawback following the ASO

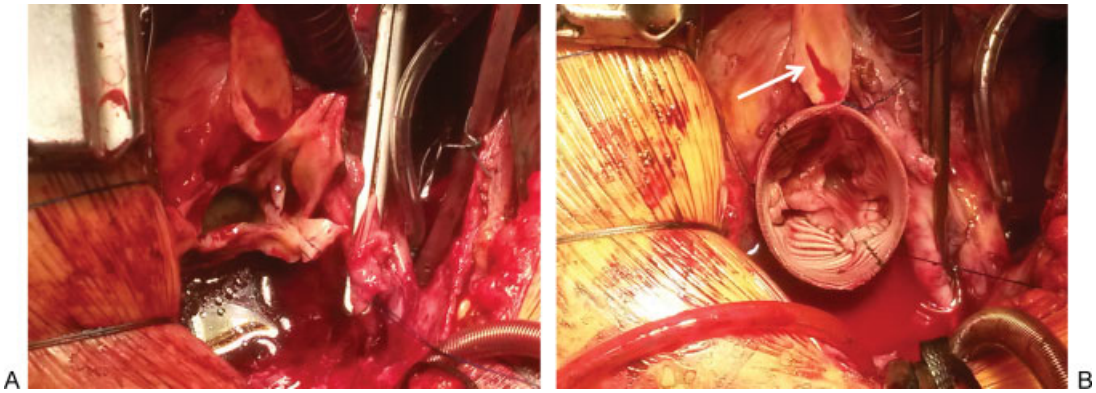

Fig. 2 (A) The former pulmonary valve in aortic position developed noduli of Arantii in high-pressure system (prominent free margin [*]). (B) The aortic cuff was reimplanted into the Dacron graft. Integration of the single coronary button into the prosthesis has to be completed (arrow).

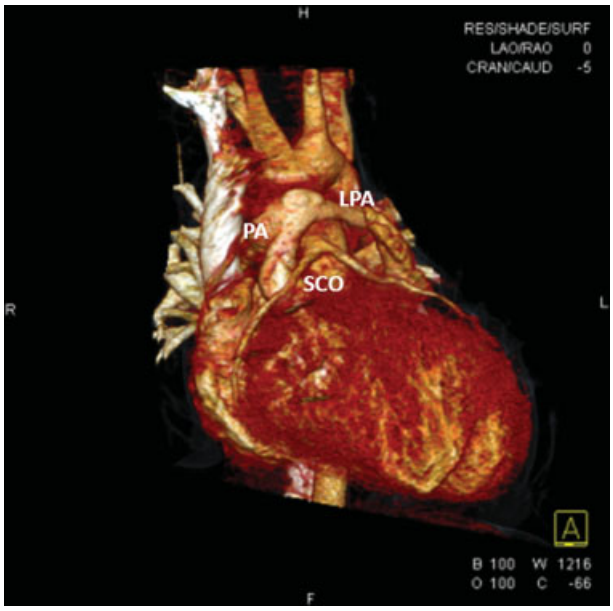

Fig. 3 Multiplanar reconstruction is demonstrating restoration of the great artery relationship and the ascending aorta after the valve-sparing reimplantation technique. LPA, left pulmonary artery; PA, pulmonary artery; SCO, single coronary ostium.

and in patients after the Ross operation.[6,7] Structural abnormality of the aortic wall, which have been proved histopathologically in patients with TGA, truncus arteriosus, and following the Ross operation might explain this phenomenon in addition to already described risk factors.[2,8] Based on the increasing number of adult patients with an ASO, the number of patients requiring reoperation for this indication will also increase.[3] The majority of these patients will be young at the time of reoperation, emphasizing the importance of preserving the neoaortic valve whenever possible instead of proceeding the aortic valve replacement or a Bentall procedure.[5] Indications for the valve-sparing reimplantation technique have been extended to various pathologies, including failing pulmonary autografts, and showed excellent mid-term results.[6] Interestingly, the valve cusps of this patient were intact and retained their trileaflet architecture. This supports the idea that prompt reintervention in patients with neoaortic root dilatation late after the ASO $\geq$ 50 mm (as per current guidelines) avoids worsening neoaortic valve regurgitation and subsequent cusp damage. We performed the valve-sparing reimplantation technique in this patient with neoaortic root dilatation and neoaortic valve regurgitation for additional annulus stabilization which is not given by using the valve-sparing remodeling technique. Because the dilated neoaortic annulus is not reinforced, recurrent annular dilatation and neoaortic valve regurgitation can occur.[9] We might overcome this disadvantage with the development of a novel three-dimensional aortic annuloplasty ring which recently underwent initial trials in humans.[10] Short-term data of this promising aortic valve repair concept are still missing. However, in our opinion, absolute contraindications for valve-preserving techniques in patients late after an ASO and concomitant neoaortic root dilatation are aortic cusps with large fenestrations, severe calcifications in bicuspid neoaortic valve morphology, and an echocardiographically documented stenotic component of the neoaortic valve. Due to the limited number of patients receiving this treatment, longer follow-up and data consolidation from multiple centers are warranted to assess the durability of valve-sparing techniques for neoaortic valve salvage late after an ASO.

Acknowledgments
The authors would like to thank Robert Nossal and Tilman Rohl for providing substantial imaging data and illuminating daily clinical work. Special thanks for improving English grammar and style to Janine Eckstein.

References

1 Castaneda AR, Norwood WI, Jonas RA, Colon SD, Sanders SP, Lang P. Transposition of the great arteries and intact ventricular septum: anatomical repair in the neonate. Ann Thorac Surg 1984;38(5): 438–443
2 Khairy P, Clair M, Fernandes SM, et al. Cardiovascular outcomes after the arterial switch operation for D-transposition of the great arteries. Circulation 2013;127(3):331–339
3 Raju V, Burkhart HM, Durham LA III, et al. Reoperation after arterial switch: a 27-year experience. Ann Thorac Surg 2013; 95(6):2105–2112, discussion 2112–2113
4 Co-Vu JG, Ginde S, Bartz PJ, Frommelt PC, Tweddell JS, Earing MG. Long-term outcomes of the neoaorta after arterial switch operation for transposition of the great arteries. Ann Thorac Surg 2013; 95(5):1654–1659
5 Liebrich M, Kruszynski MK, Roser D, et al. The David procedure in different valve pathologies: a single-center experience in 236 patients. Ann Thorac Surg 2013;95(1):71–76
6 Liebrich M, Weimar T, Tzanavaros I, et al. The David procedure for salvage of a failing autograft after the Ross operation: maintaining the principle of a living valve. Ann Thorac Surg 2014; In press
7 Pees C, Laufer G, Michel-Behnke I. Similarities and differences of the aortic root after arterial switch and ross operation in children. Am J Cardiol 2013;111(1):125–130
8 Koolbergen DR, Manshanden JS, Yazdanbakhsh AP, et al. Reoperation for neoaortic root pathology after the arterial switch operation. Eur J Cardiothorac Surg 2014 (e-pub ahead of print). doi: 10.1093/ejtcs/ezu026
9 Izumoto H, Kawazoe K, Oka T, Kazui T, Kawase T, Nasu M. Aortic valve repair for aortic regurgitation: intermediate-term results in patients with tricuspid morphology. J Heart Valve Dis 2006;15(2): 169–173, discussion 173
10 Mazzitelli D, Nöbauer C, Rankin JS, et al. Early results of a novel technique for ring-reinforced aortic valve and root restoration. Eur J Cardiothorac Surg 2014;45(3):426–430