

Severe Cystic Periventricular Leukomalacia in a Premature Infant with *Capnocytophaga* Sepsis

W. Thomas Bass, MD¹ Donna DeLoach, RN, NNP¹ Jamil H. Khan, MD¹ Glen A. Green, MD¹
Kenji M. Cunnion, MD²

¹Department of Pediatrics, Division of Neonatal Medicine, Children's Hospital of The King's Daughters, Children's Specialty Group, Eastern Virginia Medical School, Norfolk, Virginia

²Department of Pediatrics, Department of Pediatric Infectious Disease, Children's Hospital of The King's Daughters, Children's Specialty Group, Eastern Virginia Medical School, Norfolk, Virginia

Address for correspondence W. Thomas Bass, MD, Division of Neonatal Medicine, Children's Hospital of The King's Daughters, 601 Children's Lane, Norfolk, VA 23507 (e-mail: Thomas.Bass@chkd.org).

Am J Perinatol Rep 2014;4:e73–e76.

Abstract

Keywords

- ▶ neonatal sepsis
- ▶ neonatal brain injury
- ▶ chorioamnionitis

Capnocytophaga is an opportunistic gram-negative anaerobic bacillus found in the oropharyngeal cavity of mammals and is associated with periodontal disease in humans. Sepsis, osteomyelitis, lung abscess, endocarditis, and meningitis have been reported in humans following animal bites. Perinatal infection with *Capnocytophaga* is infrequent and is generally considered to have a low risk of morbidity to the mother and fetus. We report a case of neonatal *Capnocytophaga* sepsis associated with the development of severe cystic periventricular leukomalacia.

Case

A 1,496 g male infant was delivered vaginally at 30 weeks' gestation to a healthy 20-year-old female who received prenatal care. Her previous two children were reported as healthy. Prenatal screening results included blood type O negative, human immunodeficiency virus negative, Rubella immune, Group B Strep (GBS) negative, rapid plasma reagin (RPR) nonreactive, Chlamydia negative, Gonococcus (GC) negative, human papillomavirus (HPV) positive, and hepatitis B surface antigen negative. The family has no pets and the mother reported no episodes of fever, rash, or vaginal discharge during the pregnancy. There were no animal bites or scratches during the pregnancy. The mother describes her dental health as good and she received no dental procedures during the pregnancy.

The mother noted contractions during her work at a fast food restaurant 24 hours before presenting to the referring hospital. The fetal heart rate was normal. No maternal fever or vaginal discharge was noted and membranes were intact at the time of hospital admission. There was spontaneous rupture of membranes 2 hours before vaginal delivery and the fluid was clear and not foul-smelling. No abnormalities of

the placenta or umbilical cord were noted. No antibiotics or steroids were given before delivery. Nasal continuous positive airway pressure was started for retractions and grunting respiratory effort. Apgar scores were 5 at 1 minute and 7 at 5 minutes. The initial glucose level was 103 mg/dL. The neonatal transport team intubated the infant and administered surfactant because of continued respiratory distress. Initial ventilator settings were rate of 40 breaths per minute, peak airway pressure of 20 cmH₂O, and end-expiratory pressure of 5 cmH₂O. An arterial blood gas on these settings showed a pH of 7.27, pCO₂ 44 mm Hg, pO₂ 103 mm Hg, bicarbonate 20, and a base excess of – 7. An intravenous of 10% dextrose was started, a blood culture obtained, and ampicillin and gentamicin were initiated.

In the neonatal intensive care unit, a chest X-ray was consistent with mild respiratory distress syndrome and umbilical arterial and venous catheters were placed. The infant's admission weight, head circumference, and length were at the 50th percentile. The infant's temperature was 36.9°C, heart rate 162, respiratory rate 68, blood pressure 43/26 with a mean of 32 mm Hg, and the physical examination was significant for tachypnea. No vasopressors were required to maintain blood pressure.

received
January 15, 2014
accepted after revision
March 25, 2014
published online
June 10, 2014

DOI <http://dx.doi.org/10.1055/s-0034-1378147>.
ISSN 2157-6998.

Copyright © 2014 by Thieme Medical Publishers, Inc., 333 Seventh Avenue, New York, NY 10001, USA.
Tel: +1(212) 584-4662.

License terms



Admission complete blood cell count (CBC) showed a hematocrit of 31%, white blood cell (WBC) of 1,800 cells/mm³ with 28% segmented neutrophils, 8% bands (I:T = 0.22), 48% lymphocytes, and 14% monocytes (absolute neutrophil count [ANC] 648). A repeat CBC on the 2nd day of life showed a hematocrit of 22%, WBC of 9,800 cells/mm³ with 47% segmented neutrophils, 4% bands, 33% lymphocytes, and 16% monocytes. The platelet count was 173,000 cells/mm³. The baby's blood type was O positive, the direct Coombs test was negative, and a transfusion of packed red blood cells was given with good response. Phototherapy was used for 4 days for a peak bilirubin level of 10 mg/dL. The baby weaned to nasal continuous positive airway pressure (CPAP) within the 1st day of life and by the 3rd day of life was stable on room air. An echocardiogram was done to evaluate a cardiac murmur and it showed a small patent foramen ovale (PFO) and no patent ductus arteriosus (PDA).

The initial blood culture showed no growth at 48 hours and antibiotics were discontinued. However, the anaerobic blood culture grew a gram-negative bacillus at 81 hours identified as *Capnocytophaga* species using RapID ANA II Panel (Remel, Lenexa, KS) and antibiotics were restarted. The aerobic blood culture remained negative. Ampicillin was given for 14 days and gentamicin for 7 days. The lumbar puncture was unsuccessful and a repeat blood culture as well as a urine culture was negative.

Cranial ultrasound done at 1 week of age showed bilateral echogenic areas primarily in the frontal and posterior cerebral white matter (►Fig. 1). Repeat scan 2 weeks later showed extensive cystic evolution of the echogenic areas consistent with cystic periventricular leukomalacia (PVL) (►Fig. 2). Magnetic resonance imaging before discharge confirmed the previous findings of severe cystic PVL and the absence of calcifications.

Total parenteral nutrition (TPN) was started at 24 hours, nasogastric feeds were started on the 2nd day of life and by 2 weeks the baby was on full enteral feeds. Ophthalmology examinations and the hearing screen were normal. The newborn metabolic screening was normal. Full po feeding was achieved after 4 weeks and the baby was discharged home at 35 days of age.

Discussion

Capnocytophaga is a genus of capnophilic, slow-growing (48 to 96 hours in standard media), facultative anaerobic, gram-negative fusiform bacilli generally isolated from the oropharyngeal tract of mammals.¹ Reports of *Capnocytophaga* infection in the perinatal period are relatively rare despite the fact one-third of the almost 200 clinical samples submitted to the Centers for Disease Control and Prevention (CDC) in 1980 for the identification of *Capnocytophaga* were obtained from the female genital tract and amniotic fluid.²

To our knowledge, there have been eight cases of perinatal infection reported in the medical literature. Significant maternal fever was noted in only one case describing a woman with a *herpes simplex* vulvar lesion, positive placental culture for *Capnocytophaga*, and negative neonatal blood cultures.³ Four of the cases describe afebrile women presenting in

preterm labor with intact membranes and mild leukocytosis.⁴⁻⁶ In these cases, *Capnocytophaga* was cultured from amniotic fluid or gastric aspirate of the infant but not from the blood, cerebrospinal fluid, or urine of the newborn. One of these infants developed a germinal matrix hemorrhage; however, a normal neurologic outcome was implied in each case. These cases of *Capnocytophaga* intra-amniotic infection in relatively healthy women with no evidence of neonatal sepsis lead to the clinical impression that these represented relatively benign infections. An additional case involved an afebrile woman presenting in preterm labor with intact membranes. *Capnocytophaga* was grown from the endometrium, newborn tracheal aspirate, and blood.⁷ In this case, the lack of any evidence of systemic illness in the neonate suggests bacteremia without sepsis. There is no description of the infant's neurodevelopmental outcome. There have been two reported cases of infants with positive blood cultures and evidence of significant systemic illness, similar to our case.^{8,9} As in our case, the women were afebrile and presented with preterm labor. Unlike our case, the women had premature rupture of membranes, one for 48 hours, and the other undetermined. The neonates developed severe neutropenia, hypotension, respiratory distress, and disseminated intravascular coagulation. One infant developed a grade 2 intraventricular hemorrhage, while both infants were reported to have a good neurodevelopmental outcome although no follow-up neuroimaging studies were mentioned. Our neonatal patient with documented *Capnocytophaga* sepsis developing severe cystic PVL appears to be unique.

PVL is a form of brain injury in preterm infants characterized by focal necrosis and gliosis of the periventricular white matter as a result of injury to oligodendrocyte progenitor cells.¹⁰ The most severe cystic form of PVL, representing loss of significant brain parenchyma, as seen in this infant, is now rare while a more subtle diffuse noncystic form is predominant. Experimental data suggest two central themes of pathogenesis of PVL; hypoxia-ischemia and infection inflammation.¹¹ The infant described in this report had a hematocrit of 31% at birth but was hemodynamically stable, had relatively good Apgar scores, and required no vasopressor support. A Kleihauer-Betke test was not done to rule out fetomaternal transfusion; however, we feel that anemia to this degree is unlikely to be the sole etiology of such significant brain injury. Experimental studies have shown a low dose of bacterial lipopolysaccharide increases the susceptibility of newborn rats to cerebral infarction in response to otherwise harmless periods of hypoxia-ischemia.¹² The absence of nucleated red blood cells and the significant neutropenia suggest that the anemia may be part of overall bone marrow suppression secondary to infection. Monocytosis as noted in this infant is often seen following acute infection.¹³

A relationship between systemic infection and PVL has been appreciated for decades. Recent studies suggest this relationship is mediated by bacterial lipopolysaccharides (LPS) recognized by Toll-like receptors (TLR) located on central nervous system (CNS) microglia.¹⁴ The activated microglial cells then produce reactive oxygen species and various cytokines toxic to immature oligodendrocytes.

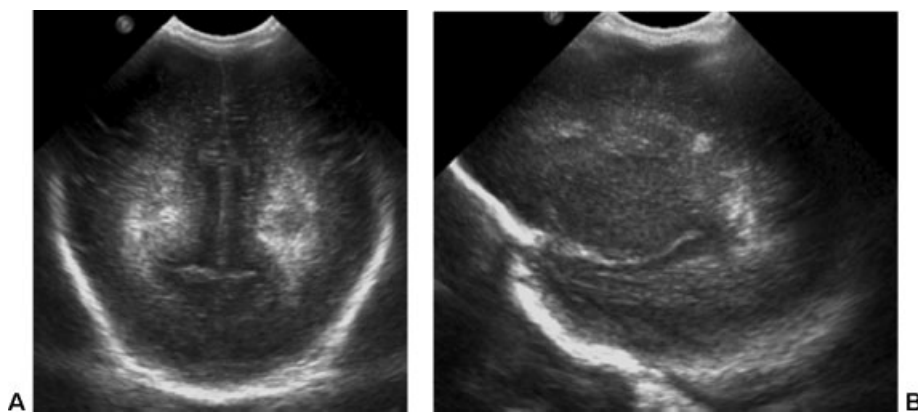


Fig. 1 (A) Coronal and (B) sagittal cranial ultrasound at 7 days of life showing periventricular echodensities.

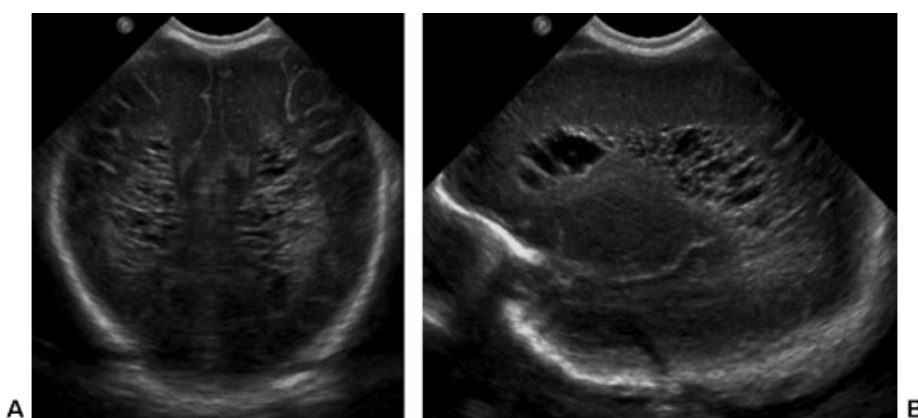


Fig. 2 (A) Coronal and (B) sagittal cranial ultrasound at 27 days of life showing cystic degeneration of prior echodensities.

Microglia expresses a specific LPS receptor, TLR4, implicated in the pathogenesis of brain injury associated with gram-negative infections. The validity of this mechanism of pathogenesis of brain injury is supported by experimental studies showing ischemic brain injury and increased levels of proinflammatory cytokines in the CNS of newborn rats after maternal injection with LPS. Furthermore, in clinical studies, the incidence of PVL and cerebral palsy is increased after maternal infection, associated with elevated levels of cytokines in amniotic fluid, cord blood, and neonatal blood.¹⁵ Current evidence indicates the Cc5 strain *Capnocytophaga* does not activate TLR4¹⁶; however, it is unknown if this feature can be generalized to all species and strains of *Capnocytophaga*. Nonetheless, it raises the possibility of another mechanism of injury in our patient.

This case reminds clinicians to consider chorioamnionitis as a cause of preterm labor even in the absence of prolonged rupture of membranes and maternal fever. The frequency of isolation of *Capnocytophaga* from the female genital tract and amniotic fluid² together with the lack of systemic illness in the women described in the case reports of *Capnocytophaga* chorioamnionitis suggests that *Capnocytophaga* is normal vaginal flora in some women. Chorioamnionitis may also result from ascending infection after oral-genital contact. The prevalence of *Capnocytophaga* infection is probably under-

reported because of the fastidious nature of the organism. In cases of chorioamnionitis associated with mild systemic symptoms, clinicians should ask the clinical microbiology laboratory to monitor the amniotic fluid culture for at least 5 days. Finally, serial neuroimaging studies of premature infants with *Capnocytophaga* sepsis are important to evaluate for the possibility of PVL.

References

- 1 Leadbetter ER, Holt SC, Socransky SS. *Capnocytophaga*: new genus of gram-negative gliding bacteria. I. General characteristics, taxonomic considerations and significance. *Arch Microbiol* 1979;122(1):9-16
- 2 Weaver RE, Hollis DG. In: Lennette EH, ed. *Capnocytophaga*. *Manual of Clinical Microbiology*. 3rd ed. Washington, DC: American Society for Microbiology; 1980:247-248
- 3 Wallace RJ. *Capnocytophaga* on the fetal surface of the placenta of a patient with ruptured membranes at 39 weeks' gestation. *Am J Obstet Gynecol* 1986;155(1):228-229
- 4 Ernest JM, Wasilauskas B. *Capnocytophaga* in the amniotic fluid of a woman in preterm labor with intact membranes. *Am J Obstet Gynecol* 1985;153(6):648-649
- 5 McDonald H, Gordon DL. *Capnocytophaga* species: a cause of amniotic fluid infection and preterm labour. *Pathology* 1988; 20(1):74-76
- 6 Edwards C, Yi CH, Currie JL. Chorioamnionitis caused by *Capnocytophaga*: case report. *Am J Obstet Gynecol* 1995;173(1): 244-245

- 7 Mercer LJ. Capnocytophaga isolated from the endometrium as a cause of neonatal sepsis. A case report. *J Reprod Med* 1985;30(1):67–68
- 8 Feldman JD, Kontaxis EN, Sherman MP. Congenital bacteremia due to Capnocytophaga. *Pediatr Infect Dis* 1985;4(4):415–416
- 9 Mayatepek E, Zilow E, Pohl S. Severe intrauterine infection due to Capnocytophaga ochracea. *Biol Neonate* 1991;60(3–4):184–186
- 10 Back SA. Perinatal white matter injury: the changing spectrum of pathology and emerging insights into pathogenetic mechanisms. *Ment Retard Dev Disabil Res Rev* 2006;12(2):129–140
- 11 Volpe JJ. Hypoxic-ischemic encephalopathy. In: *Neurology of the Newborn*. New York: Elsevier, Saunders; 2008:chap 8:370
- 12 Eklind S, Mallard C, Leverin AL, et al. Bacterial endotoxin sensitizes the immature brain to hypoxic–ischaemic injury. *Eur J Neurosci* 2001;13(6):1101–1106
- 13 Long SS. Laboratory manifestations of infectious diseases. In: Long SS, Pickering LK, Prober CG, eds. *Principles and Practice of Pediatric Infectious Diseases*. New York: Elsevier, Saunders; 2012:chap 288:1406
- 14 Lehnardt S, Lachance C, Patrizi S, et al. The toll-like receptor TLR4 is necessary for lipopolysaccharide-induced oligodendrocyte injury in the CNS. *J Neurosci* 2002;22(7):2478–2486
- 15 Perlman JM, Risser R, Broyles RS. Bilateral cystic periventricular leukomalacia in the premature infant: associated risk factors. *Pediatrics* 1996;97(6 Pt 1):822–827
- 16 Shin H, Mally M, Meyer S, et al. Resistance of Capnocytophaga canimorsus to killing by human complement and polymorphonuclear leukocytes. *Infect Immun* 2009;77(6):2262–2271