

Crisscross anchor-stents to prevent metal stent migration during endoscopic ultrasound-guided hepaticogastrostomy

Endoscopic ultrasound-guided hepaticogastrostomy (EUS-HGS) has become increasingly utilized to palliate malignant biliary obstruction in patients with inaccessible papillae as a result of duodenal tumor invasion [1,2]. Although a covered self-expandable metal stent (SEMS) is preferred to a plastic stent in EUS-HGS because of its lower risk of bile leakage [3], SEMS migration can be a fatal complication [4]. Herein, we present a case in which a SEMS at risk of proximal migration was successfully managed by adding plastic stents to serve as an anchor.

An 82-year-old man, who had undergone transpapillary stenting using a covered SEMS for distal bile duct cancer, presented with duodenal obstruction. The biliary SEMS was removed endoscopically, followed by duodenal SEMS placement, and EUS-HGS was performed in segment 3 using a covered SEMS (modified-GIOBOR, width 10 mm, length 10 cm, 1-cm uncovered portion at the proximal end; Tae-Woong Medical Inc., Gimpo, Korea). The following day, percutaneous transhepatic biliary drainage was performed for cholangitis in segment 2. During this procedure, there was proximal dislocation of the SEMS as a result of interference between the percutaneous transhepatic biliary drainage catheter and the SEMS. A therapeutic duodenoscope (JF-260V, Olympus, Tokyo, Japan) was inserted immediately, and the distal SEMS end was barely observed (● Fig. 1). The SEMS was moved 2 cm into the stomach by grasping its distal end using biopsy forceps. Subsequently, we punctured the covered mesh wall of the SEMS using an endoscopic retrograde cholangiopancreatography (ERCP) cannula using an endoscopic retrograde cholangiopancreatography (ERCP) cannula and a 0.035-inch guidewire (● Fig. 2), and placed a 5-Fr plastic stent (Geenen, Cook Endoscopy, Winston-Salem, North Carolina, USA). Another plastic stent was placed similarly in a crisscross manner (● Fig. 3). The patient did not develop any further complications, including cholangitis or SEMS migration. The management of SEMS migration in EUS-HGS is technically demanding and potentially requires surgical intervention [5]. Crisscrossing anchor stents can be used as a salvage technique to prevent this complication.

Endoscopy_UCTN_Code_TTT_1AS_2AC

Competing interests: None

Yusuke Shima^{1,2}, Hiroyuki Isayama^{1,2}, Yukiko Ito¹, Tsuyoshi Hamada², Yousuke Nakai², Takeshi Tsujino¹, Ryo Nakata¹, Kazuhiko Koike²

¹ Department of Gastroenterology, Japanese Red Cross Medical Center, Tokyo, Japan

² Department of Gastroenterology, Graduate School of Medicine, The University of Tokyo, Tokyo, Japan

References

- 1 Park do H, Koo JE, Oh J et al. EUS-guided biliary drainage with one-step placement of a fully covered metal stent for malignant biliary obstruction: a prospective feasibility study. *Am J Gastroenterol* 2009; 104: 2168–2174
- 2 Hamada T, Isayama H, Nakai Y et al. Transmural biliary drainage can be an alternative to transpapillary drainage in patients with an indwelling duodenal stent. *Dig Dis Sci* 2014, DOI: 10.1007/s10620-014-3062-1
- 3 Kawakubo K, Isayama H, Kato H et al. Multi-center retrospective study of endoscopic ultrasound-guided biliary drainage for malignant biliary obstruction in Japan. *J Hepatobiliary Pancreat Sci* 2014; 21: 328–334
- 4 Kim TH, Kim SH, Oh HJ et al. Endoscopic ultrasound-guided biliary drainage with placement of a fully covered metal stent for malignant biliary obstruction. *World J Gastroenterol* 2012; 18: 2526–2532
- 5 Hamada T, Nakai Y, Isayama H et al. Tandem stent placement as a rescue for stent misplacement in endoscopic ultrasonography-guided hepaticogastrostomy. *Dig Endosc* 2013; 25: 340–341

Bibliography

DOI <http://dx.doi.org/10.1055/s-0034-1377945>
Endoscopy 2014; 46: E563
 © Georg Thieme Verlag KG
 Stuttgart · New York
 ISSN 0013-726X

Corresponding author

Hiroyuki Isayama, MD, PhD
 Department of Gastroenterology
 Graduate School of Medicine
 The University of Tokyo
 7-3-1 Hongo, Bunkyo-ku
 Tokyo 113-8655, Japan
 Fax: +81-3-38140021
isayama-ky@umin.ac.jp

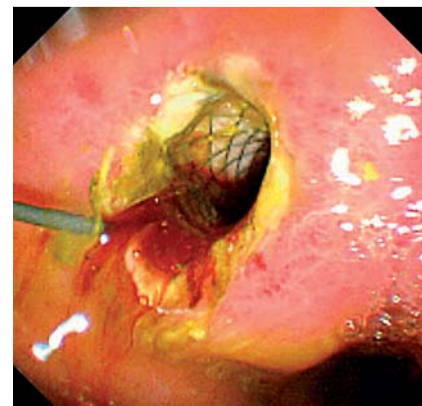


Fig. 1 A covered self-expandable metal stent (SEMS) used for endoscopic ultrasound-guided hepaticogastrostomy (EUS-HGS) had nearly migrated into the peritoneal cavity of an 82-year-old man as a result of interference between the percutaneous transhepatic biliary drainage catheter and the SEMS. The distal end of the stent could barely be seen.

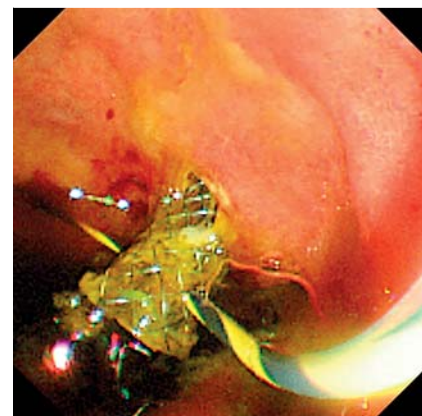

Fig. 2 An endoscopic retrograde cholangiopancreatography (ERCP) cannula was used to puncture the mesh wall of the covered self-expandable metal stent (SEMS). A guidewire was then passed through the mesh wall and the opposite wall of the metal stent.

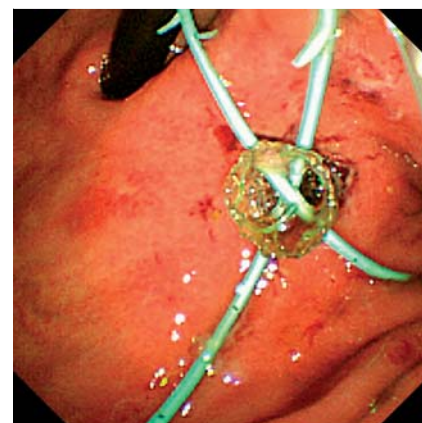


Fig. 3 The crisscrossing anchor stents technique was used to prevent proximal migration of the metal stent. Two crisscrossed 5-Fr plastic stents served as an anchor to prevent stent migration.