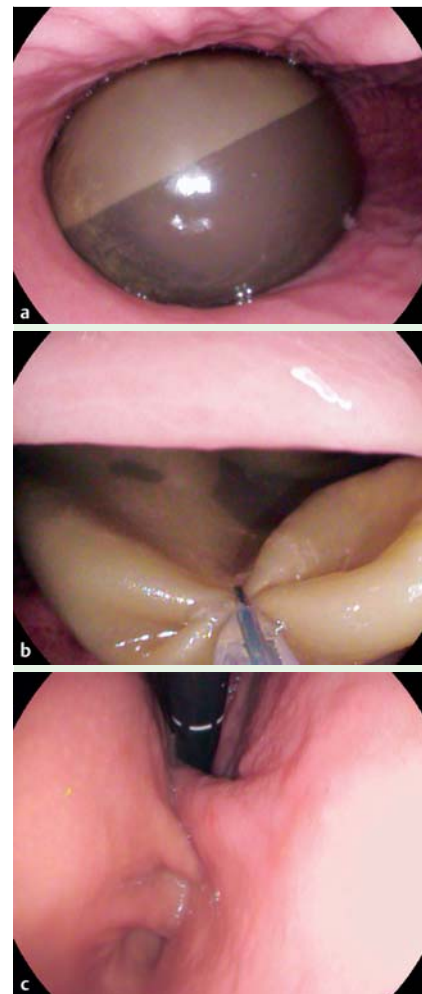
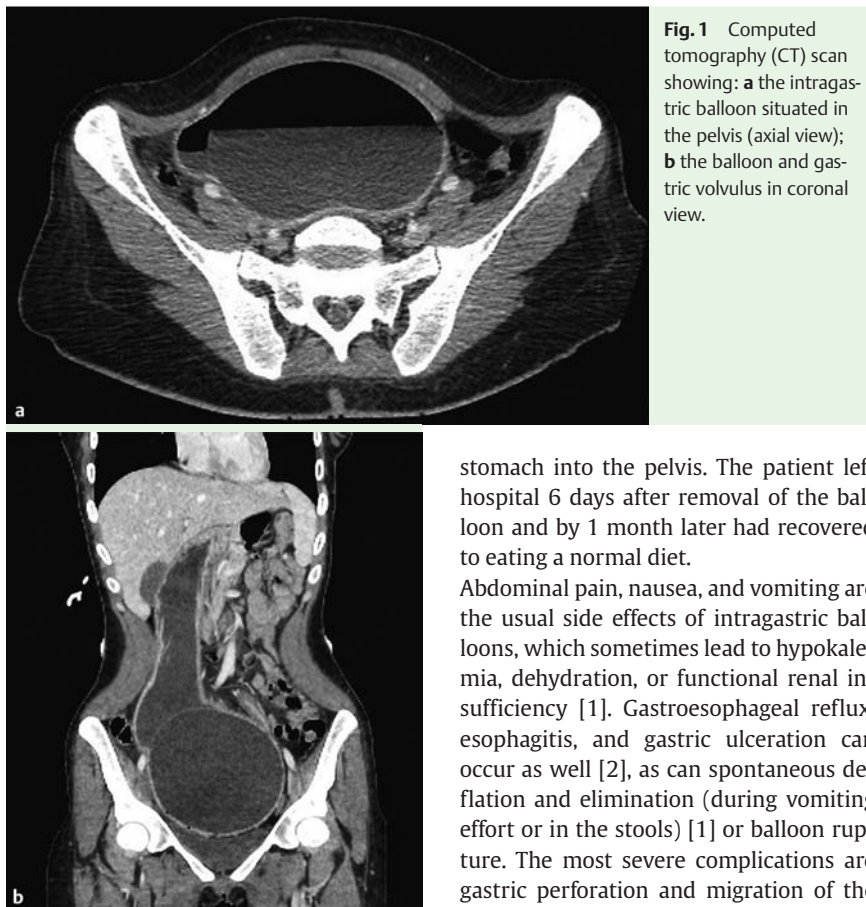


## A surprising complication of an intragastric balloon: a gastric volvulus



A 26-year-old woman attended the emergency department with severe vomiting and total anorexia for 1 week, which had caused severe hypokalemia (1.62 mmol/L) and extracellular dehydration. Her only relevant history was insertion of a saline-filled BioEnterics intragastric balloon (BIB, Santa Barbara, California, USA) at another center 6 months previously for obesity (body mass index [BMI] 30.5 kg/m<sup>2</sup>). Clinical examination showed tachycardia, which settled after potassium supplementation, and a palpable pelvic mass. A computed tomography (CT) scan revealed that the balloon was dysfunctional, having air within it, and was causing a gastric volvulus, with the balloon being situated in the pelvis (► Fig. 1). An upper gastrointestinal endoscopy was performed, and the balloon was removed after its contents had first been suctioned (► Fig. 2). The cardia and pylorus were in satisfactory positions, but the balloon had caused migration of the body of the

stomach into the pelvis. The patient left hospital 6 days after removal of the balloon and by 1 month later had recovered to eating a normal diet.

Abdominal pain, nausea, and vomiting are the usual side effects of intragastric balloons, which sometimes lead to hypokalemia, dehydration, or functional renal insufficiency [1]. Gastroesophageal reflux, esophagitis, and gastric ulceration can occur as well [2], as can spontaneous deflation and elimination (during vomiting effort or in the stools) [1] or balloon rupture. The most severe complications are gastric perforation and migration of the balloon causing small-bowel obstruction [1,2].

After 6 months (the theoretical date of removal), it is known that spontaneous deflation can occur. In this case, however, the volume of the balloon increased because of an air leak. This caused a gastric volvulus with extreme distension of the stomach, which reached into the pelvis, a situation that has never been described before. According to the manufacturer, three similar cases have been reported in France, but none of these have been associated with such major gastric distension.

Endoscopy\_UCTN\_Code\_CPL\_1AH\_2AJ

**Competing interests:** None

**Pascale Mercky, Philippe Ah-Soune, David Bernardini**

Gastroenterology Department, Sainte Musse Hospital, Toulon, France

### References

- 1 Roman S, Napoleon B, Mion F et al. Intragastric balloon for "non-morbid" obesity: a retrospective evaluation of tolerance and efficacy. *Obes Surg* 2004; 14: 539–544
- 2 Genco A, Bruni T, Doldi SB et al. BioEnterics Intragastric Balloon: The Italian Experience with 2,515 Patients. *Obes Surg* 2005; 15: 1161–1164

### Bibliography

DOI <http://dx.doi.org/10.1055/s-0034-1377368>  
Endoscopy 2014; 46: E403  
© Georg Thieme Verlag KG  
Stuttgart · New York  
ISSN 0013-726X

### Corresponding author

**Pascale Mercky, MD**  
Gastroentérologie – Hôpital Sainte Musse  
54, rue Sainte Claire Deville, 83100 Toulon  
France  
Fax: +33-494-145276  
[pascale\\_mercky@hotmail.com](mailto:pascale_mercky@hotmail.com)