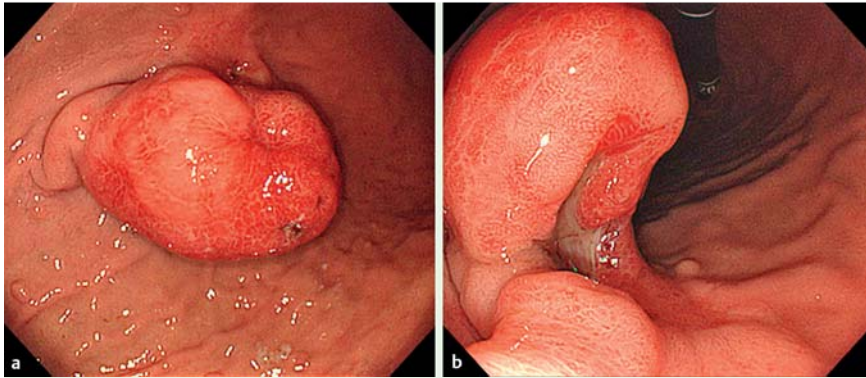
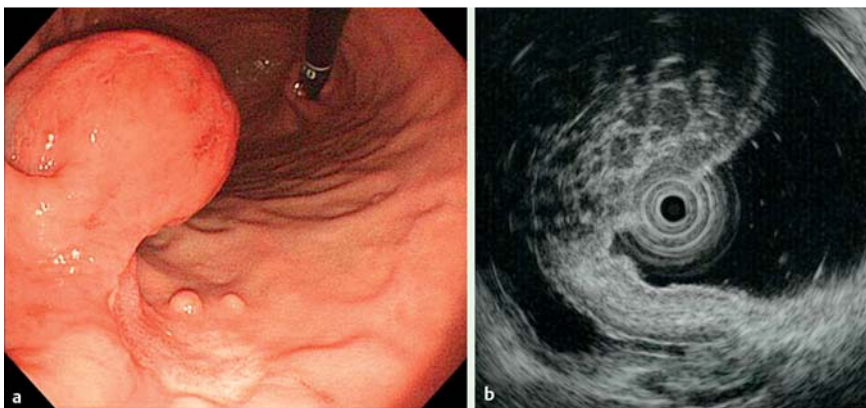


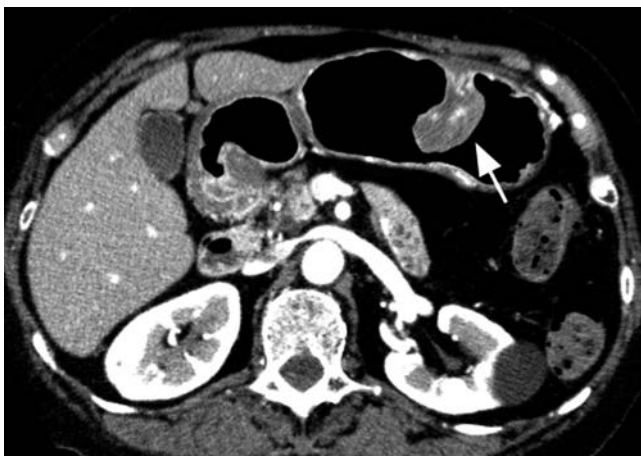
## Large polypoid lymphoid follicles in the stomach causing anemia



**Fig. 1** a Endoscopy revealed a large pedunculated polyp in the greater curvature of the gastric body. b The polyp was partly ulcerated.



**Fig. 2** a The ulceration in the polyp recovered following administration of a proton pump inhibitor. b Endoscopic ultrasound showed multiple hypoechoic nodules in the polyp.



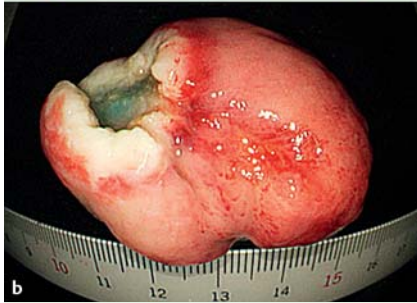
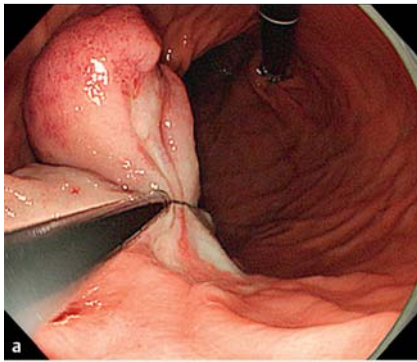
**Fig. 3** Abdominal computed tomography showed a pedunculated polyp (arrow) suspended from the gastric wall.

A 73-year-old woman with type C hepatitis underwent esophagogastroduodenoscopy because of asymptomatic anemia (hemoglobin concentration 8.6 g/dL). Endoscopy revealed a large pedunculated polyp in the greater curvature of the gastric body (Fig. 1a). The polyp was covered for the most part by normal reddish mucosa and partly by an ulcer (Fig. 1b). Biopsy specimens obtained from the polyp and the ulcer showed histopathologically benign tissue. Laboratory tests (serum antibody, fecal antigen, and urea breath test) were negative for *Helicobacter pylori*. The ulcer healed after administration of a proton pump inhibitor (Fig. 2a), and the anemia improved after administration of iron (hemoglobin concentration 13.5 g/dL). Endoscopic ultrasound showed multiple hypoechoic nodules in the polyp (Fig. 2b). Abdominal computed tomography showed a polyp suspended from the gastric wall (Fig. 3). In the absence of any other bleeding source, the gastric polyp with ulceration was suspected of being the bleeding point and the cause of the anemia. Endoscopic polypectomy was performed without complications (Fig. 4a). The size of the resected specimen was 38×28×20 mm (Fig. 4b); the cross-section of the formalin-fixed specimen had a multinodular appearance (Fig. 5). After the polypectomy, and following withdrawal of the iron treatment, the anemia did not return. Histopathological evaluation of the resected specimen demonstrated multiple primary lymphoid follicles in the mucosa and submucosa (Fig. 6). Immunohistochemical staining showed lymphocytes along with positive staining with CD10 and CD20 and negative staining with CD5, bcl-2, and cyclin-D1. This polypoid lesion was diagnosed as multiple gastric lymphoid follicles.

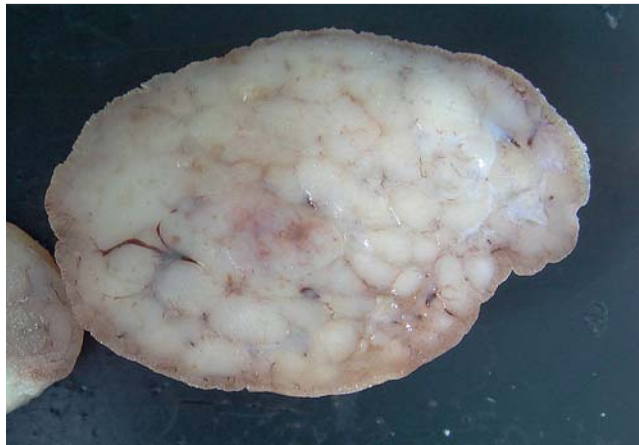Reports of lymphoid follicles occurring in *Helicobacter pylori*-negative gastric mucosa are rare [1]. Gencosmanoglu et al. reported that lymphoid follicles were detected in 9 specimens (6%) among 150 gastric polyps obtained by polypectomy [2]. However, to our knowledge, this is the first report of large polypoid lymphoid follicles in a *Helicobacter pylori*-negative stomach, and which were the cause of anemia.

Endoscopy\_UCTN\_Code\_CCL\_1AB\_2AD\_3AB

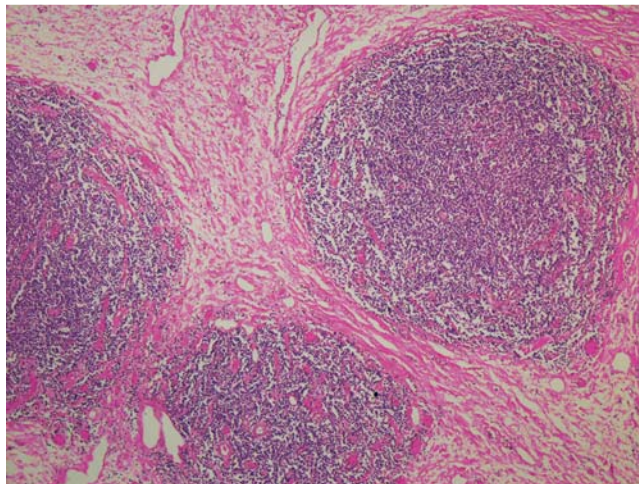
**Competing interests:** None



**Fig. 4** **a** Endoscopic polypectomy was performed with a large snare. **b** The size of the resected specimen was 38×28×20 mm.



**Fig. 5** The cross-section of the formalin-fixed resected specimen showed a multi-nodular appearance.



**Fig. 6** Microscopy showed multiple primary lymphoid follicles in the mucosa and submucosa (H&E stain).

**Kyosuke Tanaka<sup>1</sup>, Yasuhiko Hamada<sup>1</sup>, Shunsuke Tano<sup>1</sup>, Kenichiro Nishikawa<sup>2</sup>, Reiko Yamada<sup>2</sup>, Takumi Aota<sup>3</sup>**

<sup>1</sup> Department of Endoscopic Medicine, Mie University Hospital, Tsu, Japan

<sup>2</sup> Department of Gastroenterology and Hepatology, Mie University Hospital, Tsu, Japan

<sup>3</sup> Department of Internal Medicine, Nagai Hospital, Tsu, Japan

#### References

- 1 Carney JA. Gastric mucosal lymphoid follicles: histology, distribution, frequency, and etiologic features. *Am J Surg Pathol* 2010; 34: 1019–1024
- 2 Gencosmanoglu R, Sen-Oran E, Kurtkaya-Yapicier O et al. Gastric polypoid lesions: analysis of 150 endoscopic polypectomy specimens from 91 patients. *World J Gastroenterol* 2003; 9: 2236–2239

#### Bibliography

**DOI** <http://dx.doi.org/10.1055/s-0034-1377217>  
*Endoscopy* 2014; 46: E351–E352  
 © Georg Thieme Verlag KG  
 Stuttgart · New York  
 ISSN 0013-726X

#### Corresponding author

**Kyosuke Tanaka, MD**  
 Department of Endoscopic Medicine  
 Mie University Hospital  
 2-174 Edobashi  
 Tsu, Mie  
 514-8507 Japan  
 Fax: +81-59-2315200  
 kyosuket@qa2.so-net.ne.jp