

Surgical Treatment of Lumbosacral Pseudarthrosis and Spondyloptosis in a Patient with Neurofibromatosis Type 1 and a Large Lumbar Anterior Meningocele. Case Report and Review of the Literature

Benjamin Brokinkel¹ Juliane Schroeteler¹ Bernd Kasprzak² Angela Brentrup¹ Christian Ewelt¹
Walter Stummer¹ Mark Klingenhoefer¹

¹Department of Neurosurgery, Universitätsklinikum Münster, Münster, Germany

²Clinic for Vascular and Endovascular Surgery, University Hospital Münster, Münster, Germany

Address for correspondence Benjamin Brokinkel, MD, Department of Neurosurgery, University Hospital Münster, Albert-Schweitzer-Campus 1, Building A1, 48149 Münster, Germany (e-mail: benjamin.brokinkel@ukmuenster.de).

J Neurol Surg A 2015;76:172–175.

Abstract

Background Lumbar anterior meningocele (MC) is rare in patients with neurofibromatosis type 1 (NF1). Although spinal fusion with maximum possible resection of the cele might be indicated in these special cases, reports describing operative procedures are lacking.

Clinical Presentation We present a young woman with NF1 and lower back pain due to lumbar anterior MC, extensive osteolysis, and deformation of the lumbar spine. After Harrington spondylodesis from T12 to S1 in 1989, she developed lumbosacral pseudarthrosis and transcutaneous migration of the spondylodesis. Thus the left pole of the spondylodesis was shortened below the level of L5 in 2005. Years later, the patient presented with lower back pain and wound infection. Imaging revealed the MC and avulsion of the right S1 screw with lumbosacral pseudarthrosis and spondyloptosis, and transcutaneous migration of the right spondylodesis pole. Three-stage surgery was indicated with explantation of the Harrington system in the first step and posterior fusion from T10 to S2 in the second step. Finally, vertebral resection, gathering of the cele, and implantation of a customized titanium cage was achieved through an anterior transabdominal approach. Postoperatively, the patient reported sufficient reduction of lower back pain.

Conclusions Lumbar anterior MC is rare in patients with NF1 and may cause spinal instability. When surgery is indicated, long-range spinal fusion and reduction of the cele should be considered. Surgery may be challenging requiring a staged operative procedure and an interdisciplinary collaboration.

Keywords

- ▶ meningocele
- ▶ neurofibromatoses
- ▶ spinal fusion
- ▶ von Recklinghausen disease
- ▶ spinal instability

received
December 6, 2013
accepted
January 3, 2014
published online
May 12, 2014

© 2015 Georg Thieme Verlag KG
Stuttgart · New York

DOI <http://dx.doi.org/10.1055/s-0034-1372439>.
ISSN 2193-6315.

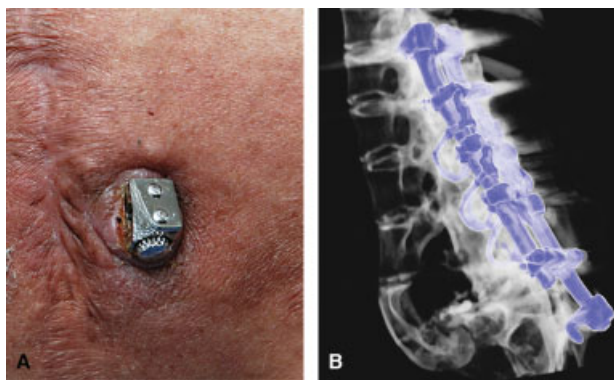


Fig. 1 (A) Caudal end of the right spondylodesis pole perforating the sacral skin 14 years after initial surgery. (B) Three-dimensional reconstructed computed tomography scan reveals posterior fusion from T12 to S1 (Harrington) with secondary shortened pole below L5 on the left and the evulsion of the S1 screw on the right side.

Introduction

Neurofibromatosis type 1 (NF1) is one of the most frequent neurocutaneous disorders, presenting with multivariou central nervous and osseous malformations including spine deformity or meningoceles (MC). Although MC and myelomeningoceles (MMC) predominantly occur posteriorly,¹ numerous case reports also describe anterior manifestations of MC/MMC along the cervical and thoracic spine.²⁻⁶ Compared with those, descriptions of anterior lumbar MC/MMC in patients with NF1 are considerably more infrequent with only very few published cases so far.^{7,8} Besides congenital deformation, it is believed that continuous pulsatile pressure of the thecal sac presumably stresses the adjacent bone and therefore leads to osteolysis and subsequent deformity and instability of the vertebrae.⁹ Although spinal instrumentation without underlying MC/MMC as well as resection of anterior celes without spondylodesis in patients with NF1 was previously described,^{10,11} to our knowledge spondylodesis for spinal instability and deformity with surgery for underlying MC/MMC has not yet been published. We report here on the surgical treatment of a female NF1 patient with a lumbar spine deformity and anterior MC presenting with lower back pain.

Case Report

In 1989, a 16-year-old young woman was initially subjected to surgery due to severe lower back pain and lumbar lordotic deformation and an anterior MC. The diagnosis of von Recklinghausen disease had already been established in childhood based on the typical clinical stigmata. At that time, treatment included lumbar Harrington spondylodesis ranging from T12 to S1 but excluded gathering or resection of the cele. Although the back pain initially improved steadily after the operation, the patient developed secondary lumbosacral pseudarthrosis. Due to progressive spondyloptosis, the left pole of the Harrington spondylodesis induced late-onset disturbance of wound healing and ultimately transcutaneous migration and subsequent wound infection. Thus the left pole of the fixateur was shortened below L5 in 2005. Although wound healing had partially been achieved, in 2013 the patient finally presented in our department with progressive lower back pain and sacral skin perforation caused by the caudal part of the right pole of the Harrington fixateur (→**Fig. 1**). Radiographic imaging revealed a marked spine deformation due to lumbosacral pseudarthrosis and lordotic spondyloptosis of the hypoplastic lumbar vertebrae, which were largely osteolytic and tilted ventrally toward the lesser pelvis despite the fixateur (→**Fig. 1**). Spondyloptosis was considered progressive comparing the current scans with computed tomography (CT) scans from 2008 (→**Fig. 2A, B**). The Harrington fixateur, however, was shown to be deficient due to the removal of the left-sided sacral screw and evulsion of the right S1 screw. Additional magnetic resonance imaging depicted the large anterior MC prolapsing through an osseous defect of the scarce remnants of the lumbar vertebrae into the lesser pelvis (→**Fig. 3A, B**). Because spondyloptosis was considered progressive and the inlaying fixateur as insufficient and infested, we planned a three-stage surgical revision.

Surgical Technique

After removal of the fixateur interne in a first step and a 3-week course of antibiotics, the patient was subjected to dorsal stabilization under neurophysiologic monitoring. Regarding clearly reduced subcutaneous soft tissue due to cachexia, the

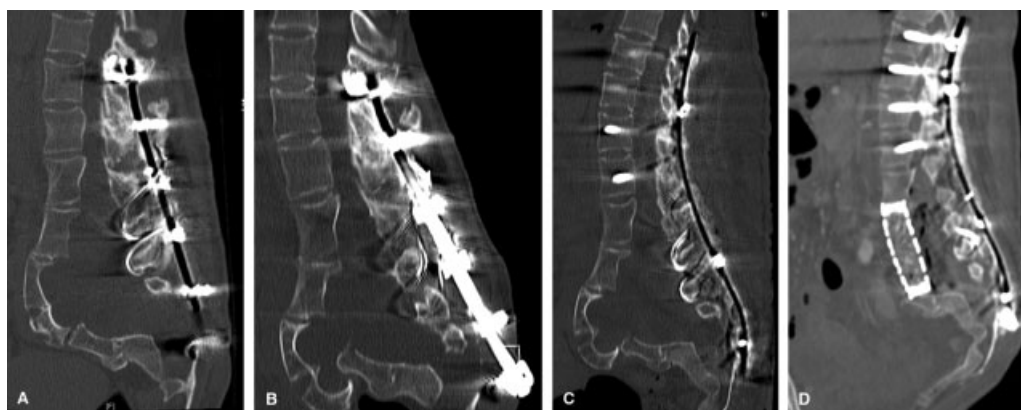


Fig. 2 Sagittal computed tomography scans from (A) 2008 and (B) 2013 revealing osteoporosis with progressive spondyloptosis toward the lesser pelvis. (C) After removing the Harrington system, a low-profile fixateur was implanted. (D) After gathering the meningocele, resection of the lumbar vertebrae L2-L4 with subsequent implantation of an anteflexed titanium mesh (100 × 17 × 22 mm) was performed.

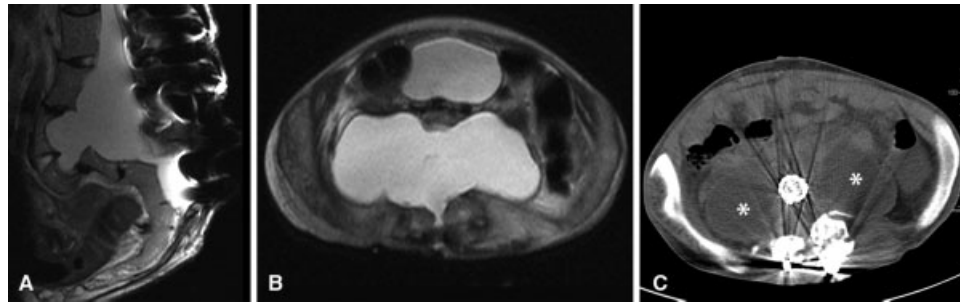


Fig. 3 (A) T2-weighted sagittal and (B) transversal magnetic resonance imaging reveals deformity of the lumbar spine and the extensive meningocele that is partially filling the lesser pelvis. (C) Axial computed tomography scan after the final operation reveals persistence of the lateral parts of the cele (asterisks) whereas the median parts had been gathered.

decision was made to use a low-profile fixateur. Intraoperatively, cranial fixation was performed with bilateral pedicle screws from T10 to L1 (►Fig. 2C). A left-sided S2 screw could not be placed due to osseous instability of the sacrum, and stability was finally achieved using a transversal pole connecting the left with the right sacral screws. Pseudarthrosis was further treated by the implantation of 12 mg recombinant bone morphogenetic protein-2 as well as autologous bone flakes mixed with tricalcium phosphate. About 3 weeks later, access to the anterior MC and lumbar spine was achieved through an anterior transabdominal approach under neurophysiologic monitoring in a collaborative operation with a vascular surgeon. After resection of vertebrae L2, L3, L4, and

partially L5, the MC was mobilized and subsequently gathered at its median parts. However, because the wall of the cele appeared to consist solely of a thin arachnoid layer and was therefore hardly stitchable, we decided not to perform complete resection to minimize the risk of a large cerebrospinal fluid fistula but reconstructed ventral parts of the dural sleeve with layers of TachoSil (Taceda Pharmaceuticals International, Zurich, Switzerland), DuraSeal (Covidien, Dublin, Ireland), and Tutopatch (Bess Medizintechnik, Berlin, Germany). Subsequently, a customized oval, slightly lordotic titanium mesh (100 × 17 × 22 mm) was implanted (►Figs. 2D, 3C, and 4).

After the final operation, due to intraoperative dural incision, 7 days of bed rest were prescribed, and the patient recovered well without any focal neurologic deficit. Wound healing was unremarkable, and lower back pain was reduced to a minimum at the time of discharge to neurophysiologic rehabilitation. At clinical presentation 3 months after surgery, the patient was mobile without neurologic deficits and considerably reduced low back pain and was looking forward to integration into employment.

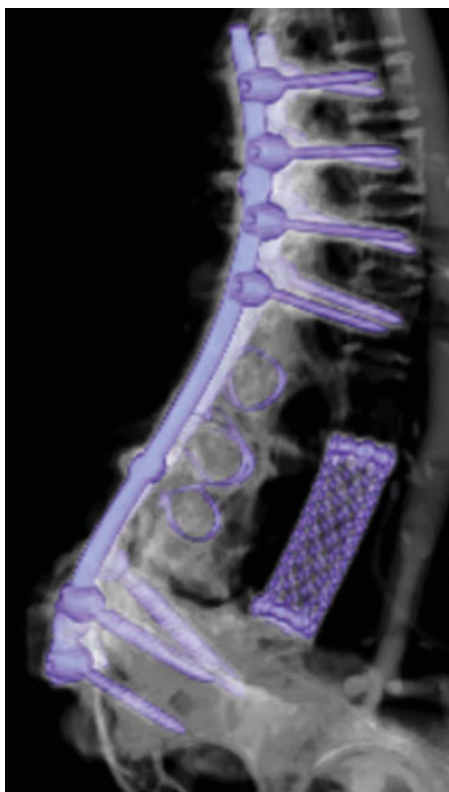

Fig. 4 Postoperative reconstructed three-dimensional computed tomography scan demonstrating posterior fusion and vertebral replacement by a customized slightly flexed titanium mesh.

Discussion

Anterior MC and MMC occasionally occur in patients with NF1 and are predominantly in a thoracic location,^{2,3,5,6} whereas lumbar location is uncommon and has only been described in two patients.^{7,8} In non-NF1 patients, although cases of anterior celes along the thoracolumbar¹² and sacral⁹ spine have been published, reports about MC restricted to the lumbar spine are lacking. Due to their anatomical location, anterior celes often prolapse into the thoracic and abdominal visceral cavities and can therefore remain asymptomatic.⁹ Apart from this, clinical manifestation of anterior thoracolumbar or sacral MC can be manifold and include, for example, abdominal and lower back pain, infertility, bladder retention, constipation, or purulent meningitis.^{13,14} Although commonly regarded as a defect in neural tube formation,¹ there is still uncertainty concerning the etiology of anterior celes of the caudal parts of the spine and their frequently associated osseous malformations. As a possibly underlying mechanism, continuous pulse synchronous stress caused by the cele is assumed to induce erosion and subsequent lysis and deformation of the underlying bony structures of the spine, causing

variable size osseous defects.⁹ Thus it is certainly conceivable that occurrence of an anterior MC/MMC with attended osseous malformation could affect the shape and stability of the involved spine segments. Surgery for symptomatic sacral anterior celes is advised in numerous reports with a large variety of surgical procedures (e.g., laparoscopic, posterior [through a sacral laminectomy], or through anterior trans-abdominal approaches).^{9,13,15} Surgical procedures in these cases exclusively deal with isolation and resection of the thecal sac. Conversely, although spinal instrumentation in the case of deformity in NF1 patients has been published,^{10,11,16} descriptions about underlying MC/MMC are lacking. A literature search revealed one report from Ebara et al describing a 59-year-old patient with NF1 who received both resection of an intrathoracic MC and extensive posterior fusion. Presenting with severe dyspnea, resection of the cele was initially performed through a wide laminectomy from T2 to T5. Because the patient subsequently developed neurologic deterioration due to spinal instability, spondylodesis was finally indicated from C3 to L2. In contrast to our case, the authors considered extended laminectomy as the cause of the spinal instability in their case.²

Conclusion

Anterior lumbar MC is rarely observed in both NF1 and non-NF1 patients. Although pathogenesis is not fully understood, in severe cases celes are assumed to cause osteolysis due to the pulsatile erosion of the adjacent bone. Because this may lead to instability with spondyloptosis and subsequent deformity, surgery should aim at spinal reconstitution with stabilization and, if possible, gathering or resection of the cele. Depending on the approach and extent of surgery, we advise a multistaged procedure in an interdisciplinary collaboration.

References

- Greenberg MS. Neurocutaneous disorders. In: Greenberg, ed. *Handbook of Neurosurgery*. 7th ed. New York, NY: Thieme Medical Publishers; 2010:722–724
- Ebara S, Yuzawa Y, Kinoshita T, et al. A neurofibromatosis type 1 patient with severe kyphoscoliosis and intrathoracic meningocele. *J Clin Neurosci* 2003;10(2):268–272
- Sakamoto H, Hoshino A, Ito K, et al. Intrathoracic giant meningocele associated with neurofibromatosis. *Intern Med* 2003;42(8):767–768
- Kos MP, Peerdeman SM, David EF, Mahieu HF. Multiple cervical anterior meningoceles in a patient with neurofibromatosis type 1 cause dysphagia and dyspnoea. *Otolaryngol Head Neck Surg* 2009;140(4):612–613
- Jeong JW, Park KY, Yoon SM, Choe W, Kim CH, Lee JC. A large intrathoracic meningocele in a patient with neurofibromatosis-1. *Korean J Intern Med* 2010;25(2):221–223
- Huang TW, Huang HP, Ye QY, et al. A neurofibromatosis type 1 patient with thoracic encapsulated fluid and intracranial hypotension syndrome: a case report. *Neurologist* 2011;17(3):167–171
- Scheltens P, Burger CW, Valk J, Bertelsmann FW. Anterolateral lumbar meningocele presenting as an ovarian cyst, in a patient with neurofibromatosis. *Clin Neurol Neurosurg* 1989;91(4):351–354
- Rainov NG, Heidecke V, Burkert W. Thoracic and lumbar meningocele in neurofibromatosis type 1. Report of two cases and review of the literature. *Neurosurg Rev* 1995;18(2):127–134
- Massimi L, Calisti A, Koutzoglou M, Di Rocco C. Giant anterior sacral meningocele and posterior sagittal approach. *Childs Nerv Syst* 2003;19(10–11):722–728
- Crawford AH. Pitfalls of spinal deformities associated with neurofibromatosis in children. *Clin Orthop Relat Res* 1989;(245):29–42
- Singh K, Samartzis D, An HS. Neurofibromatosis type I with severe dystrophic kyphoscoliosis and its operative management via a simultaneous anterior-posterior approach: a case report and review of the literature. *Spine J* 2005;5(4):461–466
- Maciejewski A. Anterior meningoceles presenting as abdominal swellings. *J Pediatr Surg* 1972;7(1):48–49
- Trapp C, Farage L, Clatterbuck RE, et al. Laparoscopic treatment of anterior sacral meningocele. *Surg Neurol* 2007;68(4):443–448; discussion 448
- Miletic D, Poljak I, Eskinja N, Valkovic P, Sestan B, Troselj-Vukic B. Giant anterior sacral meningocele presenting as bacterial meningitis in a previously healthy adult. *Orthopedics* 2008;31(2):182
- Tani S, Okuda Y, Abe T. Surgical strategy for anterior sacral meningocele. *Neurol Med Chir (Tokyo)* 2003;43(4):204–209
- Lewis SJ, Canavese F, Keetbaas S. Intralaminar screw insertion of thoracic spine in children with severe spinal deformities: two case reports. *Spine (Phila Pa 1976)* 2009;34(7):E251–E254