

## Statement of the Section Internal Medicine of the DEGUM

# Ultrasound Obtains Pole Position for Clinical Imaging in Acute Diverticulitis

On the background of the German Guideline Diverticular Disease / Diverticulitis.

## Key words

- ▶ Diverticulitis
- ▶ diverticular disease
- ▶ intestinal ultrasonography
- ▶ ultrasound

This paper reviews and interprets the role of ultrasonography in view of the recently published Guideline on diverticular disease of the Consensus conference of the German Societies of Gastroenterology (DGVS) and Visceral Surgery (DGAV) implying a new classification of diverticular disease (CDD). Qualified US is not only equipotent to qualified CT and frequently effectual for diagnosis but considers relevant legislation for radiation exposure protection. Unsurpassed resolution allows detailed resolution thereby allowing to differentiate and stratify the relevant types of diverticular disease. Subsequently, US is considered the first choice of imaging in diverticular disease. Vice versa, CT has definite indications in unclear / discrepant situations – or insufficient US-performance.

The 2014 Consensus conference of the German Societies of Gastroenterology (DGVS) and Visceral Surgery (DGAV) on diverticular disease has passed a new classification of diverticulitis and the different facets of diverticular disease (CDD). This classification addresses and stratifies different types of diverticulitis but also comprises asymptomatic diverticulosis, symptomatic diverticular disease (SUDD; largely resembling irritable bowel syndrome), and diverticular bleeding (Table 1) [1].

Among the diagnostic keynotes, the guideline stresses (1) the necessity to expand physical examination and laboratory analyses (CRP, WBC, urine analysis) by an imaging method (US or CT) for a safe diagnosis of diverticulitis, and (2) the obligation to classify diverticular disease. (3) In

contrast to other guidelines the CDD for the first time favors abdominal US as the method of choice for cross sectional imaging.

Because published work for now more than 25 years and the excellence of few individuals, etching the standing of US in their institutions in stone [2-9], may not represent general standards of US for diverticulitis, this paper attempts to outline the fundamental characteristics of diverticulitis at US as well as their technical and personal prerequisites against the back-

ground of the new classification and guideline.

## Classification

Until now any classification of diverticular disease has been overcome and modified with time because new aspects in diagnosis or therapy arose [10-18].

The German guideline 2014 [1] unanimously came to a new classification (CDD, classification of diverticular disease),

Table 1: Classification of diverticular disease (CDD)

<b>type 0</b>	<b>asymptomatic diverticulosis</b>	random finding; asymptomatic condition not a disease per se
<b>type 1</b>	<b>acute uncomplicated diverticulitis</b>	
type 1a	diverticulitis/diverticular disease without peridiverticulitic phlegmon	symptoms attributable to diverticula signs of inflammation (CRP, WBC): optional typical cross-sectional imaging
type 1b	diverticulitis with phlegmonous peridiverticulitis	signs of inflammation (CRP, WBC): mandatory cross-sectional imaging: phlegmonous diverticulitis
<b>type 2</b>	<b>acute complicated diverticulitis</b>	
type 2a	microabscess	signs of inflammation (CRP, WBC): mandatory typical cross sectional imaging plus concealed perforation, small abscess ( $\leq 1$ cm); minimal paracolic air
type 2b	macroabscess	paracolic or mesocolic abscess ( $> 1$ cm)
type 2c	free perforation	free perforation, free air / fluid generalized peritonitis
	type 2c1	purulent peritonitis
	type 2c2	fecal peritonitis
<b>type 3</b>	<b>chronic diverticular disease</b>	relapsing or persistent symptomatic diverticular disease
type 3a	symptomatic uncomplicated diverticular disease (SUDD)	localized symptoms lab test (calprotectin): optional cross sectional imaging: normal
type 3b	relapsing diverticulitis without complications	signs of inflammation (CRP, WBC): present cross-sectional imaging: indicates inflammation
type 3c	relapsing diverticulitis with complications	identification of stenoses, fistulas, conglomerate tumor
<b>type 4</b>	<b>diverticular bleeding</b>	diverticula identified as the source of bleeding

which takes – against a more sophisticated Dutch classification [19] – practical algorithms (symptomatic, asymptomatic, complicated, uncomplicated, acute, recurrent), ongoing surgical aspects (purulent vs faecal peritonitis) and contemporary diagnostic standards in clinics and in practice into account. As a result, the CDD comprises the entire spectrum of diverticular disease facets. It is not tied to a specific diagnostic preference and it does not refer to stages (indicating progressive severity with increasing stages) but to different types of presentation [1] (Table 1).

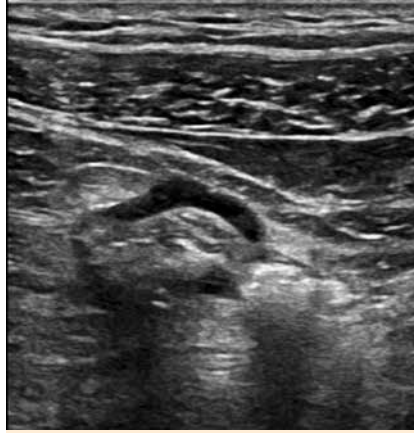
### Anatomy

Colonic diverticula are acquired outpouchings of the mucosal and submucosal layers penetrating a muscular hiatus of the colonic wall next to mucosa supplying arteries. Muscular hypertrophy with elastosis is the morphological hallmark and prerequisite for the development of sigmoid (pseudo)diverticula [20-23]. Thus muscular hypertrophy is almost always visible by US (Fig. 1).

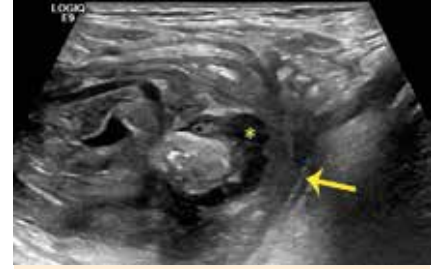### Macropathology and pathogenesis

As an inflammatory process diverticulitis usually starts within the diverticulum (sequel to occlusion by a koprocolith) or at the neck of the diverticulum (ischemia or mechanical injury) (Fig. 2). Accordingly, initially only one diverticulum is concerned. Inflammation leads to increased pressure followed by microperforation evoking a peridiverticular mesenteric inflammatory reaction which may progress to a pericolic and mural phlegmonous infiltration which secondarily may involve further diverticula and / or cause fistulisation, sealed perforation, abscess, free perforation, peritonitis, or a stenosing inflammatory sigmoidal tumor [1,23]. The peridiverticular reaction is a macroscopically visible fibrofatty hyperperfused mass, which is an important element for diagnosis both at US (including CEUS, Fig. 3) and CT ('stranding').

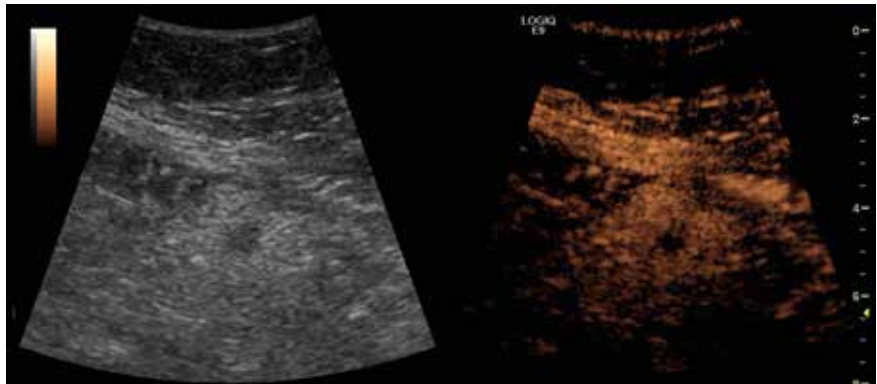
Accordingly (in theory), any acute diverticulitis encompasses microperforation. The differentiation between complicated and uncomplicated diverticulitis refers to the presence / absence of a perforation detected by air, fistula or abscess at the respective imaging method or at operation. Not only from US-experience but also because CT almost exclusively relies on broadening of the sigmoid wall and pericolic



**Fig. 1** Muscular hypertrophy as a prerequisite for diverticulosis (left colon) is well visible at US. Impressive hypertrophy / elastosis of the muscular layer in diverticulosis (type 0).



**Fig. 2** Occluding koprolith which has not passed the diverticular neck. As a consequence, inflammatory suppuration (\*) has concentrated in the diverticulum and perforation appears on the brink. As far as shown here, this is considered CDD type 1b because of the echopoor sealing (arrow); in fact perforation was visible in other sections



**Fig. 3** Contrast enhanced ultrasound (CEUS) clarifies that the fibrofatty mass / 'mesenteric cap' comprises a hyperperfused peridiverticular mesenteric inflammatory reaction. Acute diverticulitis CDD type 1a (transverse section through the inflamed diverticulum). Enhancement of Sonovue®-bubbles 1.33 min p.i.

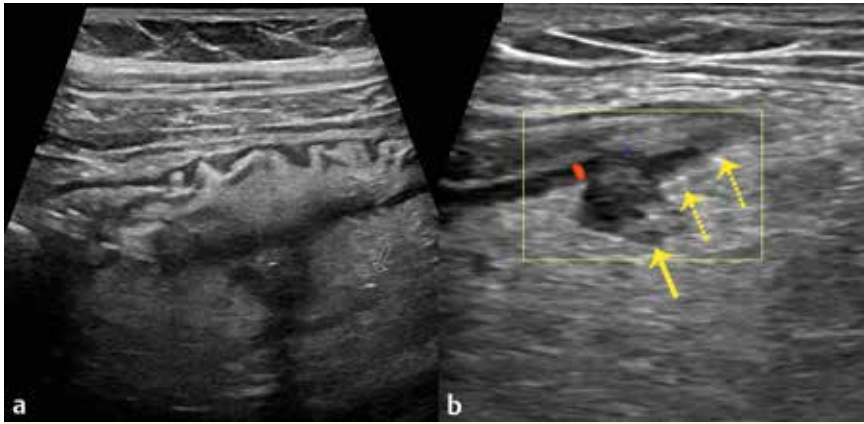
stranding but detects inflamed diverticula in acute diverticulitis in a minority of 30% only [24] US is superior to CT in detecting traces of gas next to a diverticulum (Fig. 4). Empirically, at CT the differentiation of such small gas bubbles inside vs outside a diverticulum can easily be misleading whereas gas covering an abscess is more likely masked at US (but rare in small abscesses (Fig. 5a) and technically avoidable in larger ones (Fig. 5b)).

The term *symptomatic uncomplicated diverticular disease* (SUDD) must not be confused with uncomplicated diverticulitis because it does not meet the criteria of diverticulitis (i.e. inflammation and imaging), rather representing irritable bowel syndrome in carriers of diverticulosis. Accordingly, US may visualize diverticulosis and accentuated colonic wall but does not reflect any correlate of inflammation in these patients [1].

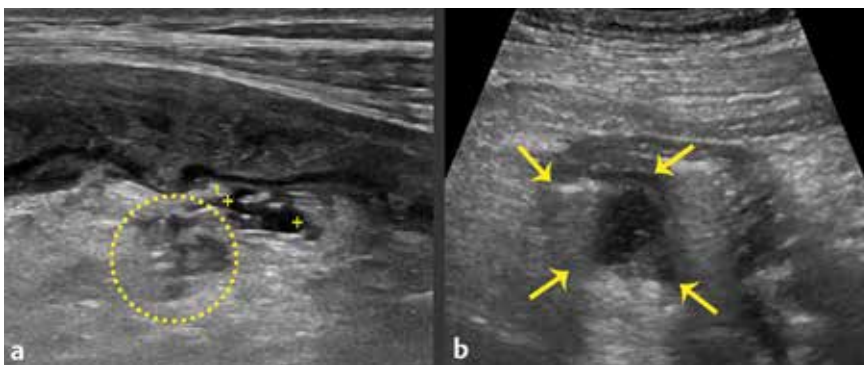
The term *segmental colitis associated with diverticula* (SCAD) refers to an unspecific segmental inflammation between sigmo-

idal diverticula. This form of sigmoidal pathology is of particular importance against the background of impressive cyclic variations of hospital admissions for 'acute diverticulitis' with highest frequencies during the summer months [25]. Because SCAD leads to segmental broadening of the affected colonic wall and may also cause a mesenteric reaction, this seasonal periodicity but also the new tendency towards a non antibiotic treatment of 'uncomplicated diverticulitis' [26, 27] (possibly misdiagnosed and representing only minor summer infections) may be regarded important issues for a differential diagnosis of SCAD vs. 'true' acute diverticulitis.

*Smoldering diverticulitis* is a surgically coined phrase for patients with sustained symptomatic diverticulitis, in whom diverticulitis remained obscure at CT, sometimes also barium enema and / or colonoscopy until sigmoidal resection was performed (histological diagnosis) [28]. The



**Fig. 4** Typical characteristics of acute diverticulitis. **a** shows a blurred boundary surface of the inflamed diverticulum passing in an echopoor / echofree lane with a gas bubble at its lateral end (arrow) (CDD type 2a). In **b** (same patient as Fig 6 but 12hrs later) gas bubbles (dotted arrows) have left the perforated diverticulum (full arrow).



**Fig. 5** Examples for peridiverticular abscesses. **a** Displays a perforated diverticulum with minimal fluid and some gas bubbles (asterisks) and a mesenteric 1x1.5cm abscess (circle) (CDD type 2a) in another patient by using a 9-15 MHz linear array. **b** 'Routine' convex transducer: acute diverticulitis CDD type 2b with a 3cm abscess, partially "hidden" by gas bubbles within the dome of the abscess.

role of US in this condition is entirely unexplored.

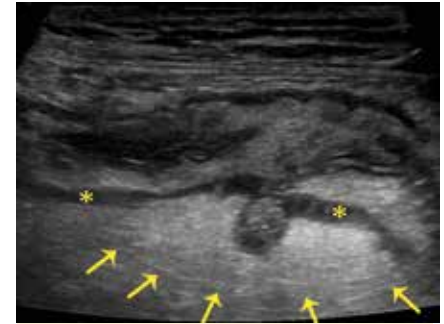
### Ultrasonography

The core finding of diverticulitis at US is (i) "THE diverticulum with different echogenicity in the centre of a pericolonic fatty tissue reaction (Hollerweger [7])", i.e. a diverticulum with a prominent hypoechoic mucosa ( $\pm$  fluid collection,  $\pm$  echogenic koproolith) surrounded by an echogenic mesenteric cap (Fig. 3, 4, 6) in conjunction with (ii) a hypoechoic initially asymmetrical wall thickening ( $>4-5$  mm) with loss of wall layering, reduced wall compliance under pressure and narrowing of the lumen, and (iii) occasionally hypoechoic 'inflammation lanes' which are considered inflammatory exsudation. Abscess, microperforation and fistulas are characterized by gas echos on top of a fluid collection in the mesentrium (at US easier recognized if closer to the diverticulum) or within a hypoechoic lane. Free

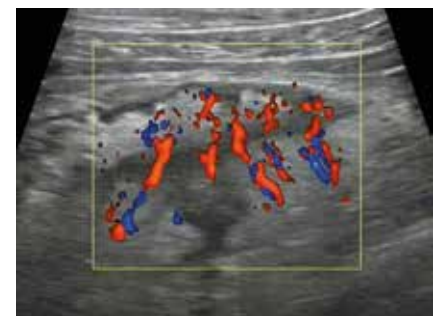peritoneal or retroperitoneal gas proves free or retroperitoneal perforation.

Hypertrophy / elastosis of the hypoechoic external circular muscle layer is an obligatory sign in diverticular disease and leads to uprightening of the arterioles allowing outpouching of the diverticula parallel to the arterioles under increased pressure. This pattern is well visible at US (Fig. 4b, 7).

As diverticulitis starts in a single diverticulum only, this is usually the site of maximum pain under compression (and the classical point of interest to put the transducer on), but inflammation can secondarily spread in longitudinal direction. Beginning in the outpouched mucosa inflammation of the diverticulum is invisible at colonoscopy unless inflammation spreads back from peridiverticulitis to the mucosa or unless a tear in the diverticular neck due to the passage of a koproolith has triggered diverticulitis [29]. Hence, the desired information from cross sectional imaging is not only whether abscess or



**Fig. 6** Acute diverticulitis CDD type 1a. Regard the muscular hypertrophy (\*) and increased wall thickness. This figure has been obtained during his night duty by an assistant with 2 years experience in medicine (S. Ntovas). The inflamed diverticulum is empty (dome-sign) and surrounded by the inflammatory mesenteric reaction (arrows).



**Fig. 7** Uprightening of the arterioles at their penetration site through the colonic wall (a consequence of muscular hypertrophy and elastosis in diverticular disease). See also Fig. 4b

perforation are present, but also whether the a.m. morphological criteria of diverticulitis are present, or segmental colonic inflammation involves 'innocent' diverticula only.

Uncomplicated and complicated diverticulitis are distinguished variants in a spectrum of different severity, rarely an escalating process, and perforated diverticular disease, if present, usually occurs as the first manifestation and not as a complication of prior episodes as claimed in Parks' understanding [30-32]. However, acute diverticulitis may progress overnight (Fig. 4b, 6). By nature, inflammation is a dynamic process, and a qualified visualization would require reiterative examinations. This – to a certain extent – precludes CT from being a method of choice.

### Quality considerations

Frequently the objection is raised that ultrasonography depends on the equipment



and on the examiner. This is pretended against the background that some physicians, but mainly surgeons, tend to refrain from accepting clinical evidence and statements reported from the US suite. If used as an excuse, however, this won't hold water [33].

However, some problems should not be overseen: as "routine" US still is frequently performed on a low level standard in Germany (overcome equipment, little experience) consequent continuous quality control covering the real needs should be applied with respect to (i) equipment, (ii) individual qualification, and (iii) pictorial quality.

### Equipment

Modern US devices usually provide all technical prerequisites for diagnosing acute diverticulitis. A curved probe with ~3.5-6 MHz is the transducer of choice for the first approach (overview, point of maximum pain) and frequently effective for diagnosis (◻Fig. 5b). However, a linear probe with ~5-12 MHz is required to reach the state-of-art diagnostic standard (◻Fig. 5a) and allows detailed resolution of the wall layers and identification of the classification criteria.

### Examiner

No medical technique ever can be valid if the examiner is not familiar with it. This holds true for US, - as it does for the CT. Irrespective of variable individual talents literature lets us assume adequate training in US for diverticulitis giving valid results (only) after ~500 (targeted) US-examinations [34, 35]. Similarly, a basic course followed by 3 months (supervised) practical training in the US suite has also shown adequate reliability in diagnosing acute diverticulitis [36]. Practically, among all frequent diseases of the intestines (appendicitis, IBD, infections, ischemia), diverticulitis will be the easiest one to be safely recognized by a trainee.

Equally important to US expertise, profound knowledge of the respective differential diagnoses including their pathogenesis, pathology, and course is mandatory. In summary the concept to which in Middle-Europe the term "Clinical Ultrasound" refers.

## Ultrasonography on the background of the CDD



### Principles and practice

Obviously it becomes clear to everybody from the radiation exposure (increasingly

important with the decreasing age of the affected patients) that not every patient with suspected diverticulitis can and should undergo CT, and it has also become evident, that not every patient with minor perforation / abscess must be operated. As a consequence, however, without CT-scan or operation, no classification of diverticulitis for the vast majority of patients exists, because the hitherto used classifications (Hinchey, Hansen-Stock) were based on either operative or CT-criteria. On the other hand, merely 'clinical diagnosis' of diverticulitis is insufficient (sensitivity ~65%) and potentially misleading [4, 37-40]. Also apostrophized as 'left sided appendicitis', the triad (i) spontaneous pain in the left lower quadrant, exaggerated by movements, (ii) an inflammatory reaction (CRP, WBC, temperature) and (iii) local guarding upon palpation, is unspecific, time-dependent, and variable, and thus may raise the suspicion of diverticulitis but neither satisfies contemporary diagnostic needs nor excludes most differential diagnoses [4, 29]. The German Guideline [1] fosters the development that this diagnostic gap can definitely be closed by qualified ultrasonography.

Because in Germany legal radiation protection applies according § 23(1) RöV from 2011, radiology is only allowed, "if a justifying indication applies. For such a balanced consideration other techniques with equivalent health benefit which do not bear radiation hazards must be taken into account".

Subsequently, long in the shade of CT, US has entered the pole position for imaging diverticulitis. Not only (i) because a meta-analysis certifies "the best evidence for diagnosis of diverticulitis in the literature is on ultrasonography; only one small study of good quality was found on CT or MRI-colonoscopy" [41], but (ii) because ultrasonography is applicable in all patients with suspected diverticulitis (e.g. outpatients and emergency cases), (iii) because it is cheap, and, (iv) because - apart from a reliable initial diagnosis - it allows a close follow up, and - last not least - (v) because it has higher resolution power than the CT-scan.

US is applied directly at the point of pain and guarding which usually guides to the inflamed diverticulum and / or its complication [42].

The inflamed diverticulum may (◻Fig. 2) or may not contain a hyperechoic more or less crescent-shaped koprocolith (◻Fig. 3-6), but once extruded, spontane-

ous drainage of pus into the colon is hypothesized to decrease pressure and the risk for perforation [43]. This is an interesting observation which deserves further subtle research.

In the case of conflicting results (e.g. disparate to the clinical impression) CT is regarded a valuable complementary method. Occasionally, abscesses deep in the pelvis or distant mesenteric abscesses originating from the lower sigmoid are responsible for such discrepancies. CT is considered decisive here, but vaginal or rectal US with endfire transducers may be a valuable US alternative, which is probably underused in Germany.

The current status shows that US meets almost all requirements for an exact diagnosis of acute diverticulitis. Equally important: reiterative examinations enable the physician to precisely follow the disease course and to detect complications as early as possible. Two points deserve further attention: the need for research as mentioned above, and the need for training which will be addressed in a pictorial essay.

### References: online

Lembcke B, J; Frankfurt/M\*; Strobel D, Erlangen; Dirks K, Winnenden; B ecker D, Hausham; Menzel J, Ingolstadt

\*Representing the Section Internal Medicine of the DEGUM at the Guideline Conference

Korrespondenzadresse: Prof. Dr.med. Dr. med.habil. Bernhard Lembcke  
E-Mail: lembcke@em.uni-frankfurt.de

\*Dedicated to

Professor Dr. med. Wolfgang F. Caspary on the occasion of his 75th birthday

## References (online)

- 1 Leifeld L, Germer CT, Böhm S, Dumoulin FL, Häuser W, Kreis M, Labenz J, Lembcke B, Post S, Reinshagen M, Ritz J-P, Sauerbruch T, Wedel T, von Rahden B, Kruijs W. S2k-Leitlinie Divertikelkrankheit/Divertikulitis. S2k Guidelines Diverticular Disease/Diverticulitis. DOI <http://dx.doi.org/10.1055/s-0034-1366692>. Z Gastroenterol 2014; 52: 663–710
- 2 Federmann G. Sonographie in der Diagnostik der akuten Colondivertikulitis. Chirurg 1989; 60: 43–46
- 3 Wilson ASR, Toi A. The value of sonography in the diagnosis of acute diverticulitis of the colon. AJR 1990; 154: 1199–1202
- 4 Schwerek WB, Schwarcz S, Rothmund M. Sonography in Acute Colonic Diverticulitis. Dis Colon Rectum 1992; 35: 1077–1084
- 5 Pradel JA, Adell JF, Taourel P, Djafari M, Monnin-Delhom E, Bruel JM. Acute colonic diverticulitis: prospective comparative evaluation with US and CT. Radiology 1997; 205: 503–512
- 6 Kori T, Nemoto M, Maeda M, Tsuzuki Y, Ando T, Sekihara M, Uchida N, Mochida Y, Kogure K, Kuwano H. Sonographic Features of Acute Colonic Diverticulitis: The "Dome Sign". J Clin Ultrasound 2000; 28: 340–346
- 7 Hollerweger A, Macheiner P, Rettenbacher T, Brunner W, Gritzmann N. Colonic diverticulitis: diagnostic value and appearance of inflamed diverticula – sonographic evaluation. Eur. Radiol. 2001; 11: 1956–1963
- 8 Ripolles T, Agramunt M, Martinez MJ, Costa S, Gomez-Abril SA, Richart J. The role of ultrasound in the diagnosis, management and evolution prognosis of acute left-sided colonic diverticulitis: a review of 208 patients. Eur. Radiol 2003; 13: 2587–2595
- 9 Farag Soliman M, Wüstner M, Sturm J, Werner A, Diehl SJ, Düber C, Post S. Primärdiagnostik der akuten Sigmadivertikulitis. Sonographie versus Computertomographie, eine prospektive Studie. Ultraschall in Med. 2004; 25: 342–347
- 10 Hughes ES, Cuthbertson AM, Carden AB. The surgical management of acute diverticulitis. Med J Aust 1963; 50(1): 780–782
- 11 Hinchey EJ, Schaal PG, Richards GK. Treatment of perforated diverticular disease of the colon. Adv Surg 1978; 12: 85–109
- 12 Sher ME, Agachan F, Bortul M et al. Laparoscopic surgery for diverticulitis. Surg Endosc 1997; 11: 264–267
- 13 Wasvary H, Turfah F, Kadro O et al. Same hospitalization resection for acute diverticulitis. Am Surg 1999; 65: 632–635
- 14 Hansen O, Stock W: Prophylaktische Operation bei der Divertikelkrankheit des Kolons – Stufenkonzept durch exakte Stadieneinteilung. Langenbecks Arch Surg 1999; suppl II:1257–1260
- 15 Neff CC, van Sonnenberg E. CT of diverticulitis: diagnosis and treatment. Radiol Clin North Am 1989; 27: 743–752
- 16 Siewert JR, Huber FT, Brune IB. Early elective surgery of acute diverticulitis of the colon. Chirurg 1995; 66: 1182–1189
- 17 Ambrosetti P, Becker C, Terrier F. Colonic diverticulitis: impact of imaging on surgical management—a prospective study of 542 patients. Eur Radiol 2002; 12: 1145–1149
- 18 Tursi A, Brandimarte G, Giorgetti G, Elisei W, Maiorano M, Aiello F. The clinical picture of uncomplicated versus complicated diverticulitis of the colon. Dig Dis Sci 2008;53: 2474–2479
- 19 Klarenbeek BR, deKorte N, van der Peet DL, Cuesta MA. Review of current classifications for diverticular disease and a translation into clinical practice. Int J Colorectal Dis 2012; 27: 207–214
- 20 Stollman N, Raskin JB. Diverticular disease of the colon. Lancet 2004;363:631–639
- 21 Whiteway J, Morson BC: Elastosis in diverticular disease of the sigmoid colon. Gut 1985;26:258–266.
- 22 Hellwig I, Bottner M, Barrenschee M, Harde J, Egberts JH, Becker T, Wedel T: Alterations of the enteric smooth musculature in diverticular disease. J Gastroenterol 2014;49(8):1241–1252
- 23 Wedel T, Barrenschee M, Lange Chr, Cossais F, Böttner M. The Morphologic Basis for Developing Diverticular Disease, Diverticulitis, and Diverticular Bleeding. Viszeralmedizin 2015 (in press)
- 24 Kircher MF, Rhea JT, Kihiczak D, Novelline RA. Frequency, Sensitivity, and Specificity of Individual Signs of Diverticulitis on Thin-Section Helical CT with Colonic Contrast Material: Experience with 312 Cases. AJR 2002; 178: 1313–1318
- 25 Ricciardi R, Roberts PL, Read TE et al. Cyclical increase in diverticulitis during the summer months. Arch. Surg. 2011; 146: 319–23
- 26 De Korte N, Kuyvenhoven J Ph, van der Peet DL, Felt-Bersma RJ, Cuesta MA, Stockmann HBAC. Mild colonic diverticulitis can be treated without antibiotics. A case-control study. Colorectal Disease 2011; 14: 325–330
- 27 Chabok A, Pählman L, Hjern F, Haapaniemi S, Smedh K, AVOD Study Group. Randomized clinical trial of antibiotics in acute uncomplicated diverticulitis. Br.J. Surg 2012; 99: 532–539
- 28 Horgan AF, McConnell EJ, Wolff BG, The S, Paterson C. Atypical diverticular disease: surgical results. Dis Colon Rectum 2001; 44: 1315–1318
- 29 Lembcke B. Diagnosis, differential diagnosis, and classification of diverticular disease. Viszeralmedizin 2015 in press (DOI: 10.1159/000380833)
- 30 Eglington T, Nguyer T, Raniga S, Dixon L, Dobbs B, Frizelle FA. Patterns of recurrence in patients with acute diverticulitis. Br. J. Surg. 2010; 97: 952–957
- 31 Chapman J, Davies M, Wolff B. Complicated diverticulitis: is it time to rethink the rules? Ann Surg. 2005; 242: 576–583
- 32 Parks TG. Natural history of diverticular disease of the colon. A review of 521 cases. Br Med J 1969;4:639–642
- 33 Seitz K. Sonographische Divertikulitisdiagnostik: Der mühsame Weg zur Akzeptanz. Ultraschall in Med 2004; 25: 335–336
- 34 van Randen A, Laméris W, Wouter van Es H, van Heesewijk HPM, van Ramshorst B, ten Hove W, Bouma WH, van Leeuwen MS, van Keulen EM, Bossuyt PM, Stoker J, Boermeester MA on behalf of the OPTIMA study group. A comparison of the Accuracy of Ultrasound and Computed Tomography in common diagnoses causing acute abdominal pain. Eur. Radiol. 2011; 21: 1535–1545
- 35 Hertzberg BS, Kliewer MA, Bowie JD, Carroll BA, DeLong DH, Gray L, Nelson RC. Physician training requirements in sonography: how many cases are needed for competence? AJR 2000; 174: 1221–1227
- 36 Zielke A, Hasse C, Nies C, Kisker O, Voss M, Sitter H, Rothmund M. Prospective evaluation of ultrasonography in acute colonic diverticulitis. Br. J. Surg 1997; 84: 385–388
- 37 Toorenvliet BR, Bakker RFR, Breslau PJ, Merkus JWS, Hamming JF. Colonic diverticulitis: a prospective analysis of diagnostic accuracy and clinical decision-making. Colorectal Diseases 2010; 12: 179–187
- 38 Laméris W, van Randen A, van Gulik TM, Busch OR, Winkelhagen J, Bossuyt PM, Stoker J, Boermeester MA. A Clinical Decision Rule to Establish the Diagnosis of Acute Diverticulitis at the Emergency Department. Dis Colon Rectum 2010; 53: 896–904
- 39 Laurell A, Hansson L-E, Gunnarsson U. Acute diverticulitis – clinical presentation and differential diagnostics. Colorectal Diseases 2007; 9: 496–502
- 40 O'Connor ES, Smith MA, Heise CP. Outpatient diverticulitis: mild or myth? J Gastrointest Surg. 2012; 16: 1389–1396
- 41 Liljegren G, Chabok A, Wickbom M, Smedh K, Nilsson K. Acute colonic diverticulitis: a systematic review of diagnostic accuracy. Colorectal Dis. 2007; 9: 480–488
- 42 Mauch M, Seitz KH. Divertikulitis. CME Fortbildung/Continuing Education. Ultraschall in Med. 2007; 28: 346–371
- 43 Puylaert JBCM. Ultrasound of Colon Diverticulitis. Dig. Dis 2012; 30: 56–59