

Endovascular Aneurysm Repair of Abdominal Aortic Aneurysms: Standards, Technical Options and Advanced Indications

Endovaskuläre Therapie abdomineller Aortenaneurysmen: Standards, technische Optionen und erweiterte Indikationen

Authors

D. Ketelsen¹, C. Thomas¹, J. Schmehl¹, C. W. König¹, R. Syha¹, K. Rittig², B. Balletshofer², C. D. Claussen¹, K. Brechtel¹

Affiliations

¹ Diagnostic and Interventional Radiology, University Hospital Tuebingen

² Internal Medicine IV – Angiology, University Hospital Tuebingen

Key words

- endovascular aneurysm repair
- EVAR
- AAA
- abdominal aortic aneurysm
- chimney graft
- periscope graft
- fenestrated graft
- branched graft
- endostapling

received 20.11.2013

accepted 10.2.2014

Bibliography

DOI <http://dx.doi.org/10.1055/s-0034-1366185>
Published online: 2014
Fortschr Röntgenstr 2014; 186: 337–347 © Georg Thieme Verlag KG Stuttgart · New York · ISSN 1438-9029

Correspondence

PD Dr. Dominik Ketelsen
University Hospital Tuebingen,
Department of Diagnostic and
Interventional Radiology
Hoppe-Seyler-Straße 3
72076 Tuebingen
Germany
Tel.: ++49/70 71/298 66 77
Fax: ++49/70 71/29 44 78
dominik.ketelsen@med.uni-tuebingen.de

License terms



Abstract

▼
Since the introduction of endovascular aneurysm repair (EVAR) in 1991, the endovascular therapy with newest stent grafts has assumed a prominent role in the clinical management of abdominal aortic aneurysms (AAA) with a superior perioperative mortality of EVAR and an equivalent mid-term outcome, compared to open surgery. Newest techniques using chimney or periscope grafts and customized fenestrated and branched stent grafts allow the endovascular treatment of complex pararenal AAA. This article reviews EVAR in the treatment of AAA, evidence based results and advanced indication by newest interventional techniques and technical developments.

Key Points:

- ▶ EVAR has become standard treatment of abdominal aortic aneurysm with equivalent results to open surgery.
- ▶ Technical advancements and the introduction of newest stent grafts continually expand the indication of EVAR.
- ▶ Chimney- and periscope grafts as well as custom-made prosthesis systems allow endovascular treatment of complex para- and suprarenal aneurysms.

Citation Format:

- ▶ Ketelsen D, Thomas C, Schmehl J et al. Endovascular Aneurysm Repair of Abdominal Aortic Aneurysms: Standards, Technical Options and Advanced Indications. Fortschr Röntgenstr 2014; 186: 337–347

Zusammenfassung

▼
Seit der Einführung der endovaskulären Aneurysmtherapie (EVAR) im Jahre 1991 hat diese Therapieoption mit neuesten Stentgrafts eine zunehmend wichtige Rolle in der Behandlung

abdomineller Aortenaneurysmen (AAA) eingenommen. Die EVAR ist der offen chirurgischen Therapie bezüglich der perioperativen Mortalität überlegen und zeigt ein vergleichbares Outcome im mittleren Follow-up. Neueste Techniken mit dem Einsatz von Chimney- und Periscope-Grafts sowie fenestrierten und gebranchten Prothesen erlauben mittlerweile die EVAR bei komplexen pararenalen AAA. Dieser Artikel bietet eine Übersicht zur EVAR bei AAA, diskutiert evidenzbasierte Daten und zeigt erweiterte Indikationen durch neueste interventionelle Techniken und technologische Entwicklungen.

Introduction

▼
Endovascular aneurysm repair (EVAR) was first published in 1991 by Parodi [1] and has since become a recognized standard method of treating infrarenal abdominal aortic aneurysms (AAA). The advantage of this minimally invasive treatment method is a reduced perioperative morbidity rate. EVAR is therefore the preferred treatment option particularly for older patients with an increased risk profile [2].

Technical advancements and the introduction of flexible low-profile systems continually expand the indications. The latest techniques, such as the chimney technique, or custom-made prosthesis systems allow treatment of complex para- and suprarenal aneurysms with the possibility of endovascular recanalization of the visceral vessels [3, 4].

The present study explains the indications for EVAR, presents evidence-based data regarding endovascular aneurysm repair, and discusses the current technical possibilities including the latest techniques for treating complex pararenal aortic aneurysms.

Etiology and pathogenesis

▼ An aneurysm is defined as localized enlargement of a vessel $\geq 50\%$ of the normal vessel diameter. By definition, the abdominal aorta is aneurysmal starting at a diameter of 3 cm [5]. The incidence of abdominal aortic aneurysms (AAAs) is 38 in 100 000 and increases with age particularly in men. 90% of patients with atherosclerotic aneurysms are men [5].

Different pathogenetic factors have been discussed: As a result of reduced diffusion of nutrients into the media of the vascular wall, mucoid-cystic media degeneration occurs resulting in a turbulent blood flow with endothelial damage and enlargement of the vascular lumen. Additional theories include transmural inflammation or an exaggerated immune response [6].

The etiology and pathogenesis of an AAA have not been conclusively clarified but atherosclerosis seems to be a decisive risk factor. Since AAAs occur more frequently in patients with other cardiovascular diseases, nicotine abuse, hypertonia, hyperlipidemia, and diabetes are general risk factors. The rupture risk can be lowered by antihypertensive treatment and statins reduce the growth rate of AAAs [7].

A genetic component has also been discussed. Therefore, siblings of patients with an AAA have an AAA incidence rate of 20–30%. Moreover, patients with Marfan's syndrome, Ehlers-Danlos syndrome, neurofibromatosis, or Turner syndrome have a significantly greater risk for AAA [5].

Rare forms of aneurysm are post-traumatic aneurysms, mycotic aneurysms, syphilitic aortitis, and post-stenotic or inflammatory aneurysms [5].

Treatment indication

▼ The goal of EVAR is to prevent aortic rupture and prolong life. Clinical decisions in interdisciplinary consensus are based on rupture risk, the operative mortality risk, life expectancy, and on patient preference [8]. The estimated annual rupture risk ranges from 5% in the case of an AAA diameter of less than 5 cm to a rupture risk of 50% in the case of a diameter of greater than 8 cm [8, 9]. In a cohort of 2257 patients, the rupture risk was significantly increased in women, and in the case of chronic obstructive lung disease (COPD), nicotine abuse, and elevated blood pressure. Due to the significantly increased rupture risk, EVAR is recommended in women starting at a diameter of 4.5 cm and at a diameter of 5.0 to 5.5 cm in men [10]. A further factor for evaluating rupture risk is the morphology of the aneurysm sac. Eccentric or saccular aneurysms have a greater risk of rupture compared to cylindrical aneurysms due to the increased mechanical strain [11]. Moreover, fast growing aneurysms (larger than 0.5 cm to 1 cm per year) require treatment [8, 12].

The operative risk must be weighed against the rupture risk. Independent risk factors for perioperative mortality include elevated creatinine levels, congestive heart failure, cardiac ischemia, pulmonary diseases, advanced age, and female gender [13].

In addition to the life expectancy of the patient, the patient's wishes should also be included in the clinical deci-

sion. One study showed a predominant patient preference for EVAR (84%) despite concerns regarding long-term outcome [14]. However, due to the lack of long-term data, open surgical aneurysm repair is preferred for younger patients (<65 years) [8].

Evidence-based EVAR data

▼ In a prospective, randomized multicenter study, the EVAR 1 trial [15, 16] examined the long-term results of EVAR compared to open aortic surgery. The primary end point was mortality, and the secondary end points were aneurysm-related mortality, health-related quality of life, and post-operative complications. 1082 patients were randomized and were treated by endovascular repair (n=543) or open surgery (n=539). The average AAA diameter was 6.5 cm in both groups. The patients were observed for 4 years. The inclusion criteria were patient age ≥ 60 years and an aneurysm diameter ≥ 5.5 cm. As a result of endovascular repair, the 30-day mortality rate was able to be significantly lowered from 4.6% to 1.6%. After 4 years, this survival advantage in relation to the aneurysm-based mortality was still significant in favor of EVAR (4% vs. 7%). However, the all-cause mortality (28% in both groups) did not differ between endovascular and surgical repair. Endovascular repair had significantly more complications over time than surgical repair (41% vs. 9%) and required more frequent reinterventions. The health-based quality of life 12 months after the end of treatment was the same for both treatment methods. This data was able to be confirmed after 8 years. Despite the substantial improvement in the perioperative mortality rate due to EVAR, neither of the treatment methods provided a significant survival advantage in the long term. However, endovascular repair resulted in increased costs due to graft-related complications and the increased rate of reinterventions compared to surgery [17].

The EVAR 2 trial [18] prospectively randomized 338 inoperable patients ≥ 60 years and with an AAA diameter ≥ 5.5 cm into an endovascular repair (n=166) and a conservative (n=172) treatment arm. The primary and secondary end points correspond to those of the EVAR 1 trial. The patients were observed for 4 years. The 30-day mortality rate for EVAR was 9% and shows the potential of this treatment option in inoperable patients with poor general condition. The all-cause mortality rate after 4 years was 64%. Neither the all-cause mortality rate nor the aneurysm-related mortality rate could be significantly improved by endovascular repair compared to conservative treatment. It must be noted that 9 patients of the EVAR group died of aortic rupture before the intervention and 20% of the patients in the conservative treatment arm underwent open surgery in the course of the study so that the results of the EVAR 2 trial can only be applied on a limited basis to the original study objective.

The DREAM trial (Dutch Randomized Endovascular Aneurysm Management) [19] prospectively randomized 351 patients ≥ 60 years and with an AAA diameter ≥ 5.0 cm into an endovascular repair (n=173) and an open surgery (n=178) treatment arm. The study largely confirmed the results of the EVAR 1 trial and showed no significant differences regarding the all-cause mortality rate after the first postoperative year and in contrast to the EVAR 1 trial also

showed no differences regarding the aneurysm-related mortality rate between the two treatment methods.

Additional prospectively randomized multicenter studies include the OVER trial (Open Versus Endovascular Repair) [20] and the UK EVAR trial [21]. These also showed an early survival advantage for endovascular repair but the all-cause mortality rate could not be significantly improved by EVAR. These results were also substantiated by the EUROSTAR Register (European Collaborators on Stent/Graft Techniques for Aortic Aneurysm Repair) [22]. After a 6-year follow-up period, long-term results of an additional prospective study (n = 351) show continued equivalent results between endovascular and open surgical repair [23].

In contrast to elective aneurysm repair, only non-randomized data regarding the treatment of ruptured AAAs is available. In a retrospective study with 37 patients (n = 17 EVAR cases, n = 20 surgeries), an early survival advantage was seen for endovascular repair with a significantly improved 30-day mortality rate of 23.5% vs. 50% but it must be taken into consideration that patients with severe hemodynamic instability primarily underwent open surgery [24]. Randomized long-term data are currently not available.

Numerous registration studies have showed high technical success rates for different stent systems but will not be described in greater detail here.

Endovascular aneurysm repair

The technical feasibility and success rate of EVAR mainly depend on the experience of the interventionalist as well as the anatomy of the abdominal aorta and the iliac axis. Evidence-based data show a significantly increased risk of peri- and post-interventional complications in the case of insufficient patient selection [25, 26]. A multicenter observational study (n = 10 228) showed a patient age ≥ 80 years, a diameter of the aneurysm neck ≥ 28 mm, angulation of the aneurysm neck $\geq 60^\circ$ and a diameter of the common iliac artery ≥ 20 mm as independent predictors for post-interventional aneurysm sac enlargement [27].

Preinterventional imaging

CT angiography (CTA) is the reference standard for preoperative EVAR imaging. It provides all necessary information regarding the anatomical relationships of the aneurysm sac, the proximal and distal landing zones, and the iliac vessels. The CTA protocols include contrast-enhanced examinations of the abdomen and pelvis in the arterial phase and, depending on the issue, also in the portal venous phase. Dedicated workstations for interpreting three-dimensional datasets facilitate analysis [25].

Anatomical exclusion criteria

Proximal aneurysm neck

The proximal aneurysm neck is the aortic segment with non-aneurysmal dilation directly proximal to the AAA and is the most common contraindication for EVAR in up to 44% of cases [28]. The diameter in the short axis of the aneurysm

neck should not exceed 30 mm since the largest diameter of commercially available stent grafts is 36 mm and oversizing of 10–20% should be targeted [29]. The length of the aneurysm neck in the craniocaudal extent describes the proximal landing zone of the stent graft and describes the length between the most caudal renal artery and the proximal aneurysm. To achieve adequate anchoring and sealing in a healthy vessel segment and to minimize the risk of prosthesis migration or type I endoleak, a distance of 15 mm for infrarenal and 10 mm for transrenal prosthesis fixation must be maintained [29]. The latest prosthesis systems (e.g. Ovation, Trivascular, Santa Rosa, USA) use innovative concepts of suprarenal fixation and proximal polymer sealing to allow treatment of aneurysm necks with a length ≥ 7 mm. A further important parameter is the angulation of the aneurysm neck. This is defined as the angle between the suprarenal aorta and the first portion of the aneurysm neck (within the first 3 cm) [25]. An angle greater than 60° is a relative contraindication since this is associated with a greater complication rate (primarily type I endoleaks) [30]. Even with an initially good result, the risk of migration, stent fracture, or separation of the prosthesis components in the case of angulation $> 60^\circ$ is significantly increased [31]. Whether a reverse tapered aneurysm neck (proximal diameter more than 3 mm greater than the distal diameter) or focal saccululation (> 3 mm) of the neck is present must be morphologically evaluated [25]. These changes are associated with an increased rate of endoleaks and represent a relative contraindication [32]. Finally, calcification and mural thrombi affect the anchoring of the endovascular prosthesis. Extensive calcifications or mural thrombi that exceed more than 90° of the circumference of the aneurysm neck are associated with an increased incidence of endoleaks [29].

Aneurysm sac

The maximum diameter of the aneurysm sac should be between 4.5 cm and 6.5 cm for EVAR. Data from the EUROSTAR Register (n = 4400) has shown that an aneurysm diameter greater than 6.5 cm results in a significantly increased perioperative risk and an increased rate of type I endoleaks [33]. Therefore, aneurysm diameters of 6.5 cm to 7.0 cm are a relative contraindication. Another factor is the diameter of the residual lumen, i.e., the perfused lumen, within the proximal and distal landing zones and in the region of the aortic bifurcation. To allow passage of the stent graft and secure anchoring of the main body and the contralateral prosthesis body, a bifurcation diameter ≥ 12 –18 mm depending on the prosthesis type is necessary [25]. In the case of smaller diameters of the residual lumen, a monoiliac prosthesis with cross-over bypass can be implanted as necessary [25]. Whether an inflammatory AAA that is an absolute contraindication for EVAR is present must be evaluated morphologically. However, recent data from the EUROSTAR Register shows equivalent results for an endovascular repair (n = 52) compared to open surgery (n = 3613) of an inflammatory AAA even in the case of persistent postinterventional inflammation [34].

Iliac arteries

The prerequisites for successful endovascular treatment are complication-free passage of the stent graft through the iliac access vessels and anchoring in an adequate distal

landing zone [25, 35]. A retrospective analysis of 307 patients showed that up to 34% of patients do not meet the anatomical requirements for EVAR, with 47% of those being due to an insufficient diameter of the iliac arteries and 10% due to high torsion of the pelvic axis [36]. The diameter of the common iliac artery should be at least 2 mm smaller than the prosthesis diameter to achieve adequate anchoring through moderate oversizing. This results in a maximum diameter of the landing zone of 24 mm based on available stent grafts. If the aneurysm is larger than the internal iliac artery, the external iliac artery should meet the above criteria. However, in these cases it is necessary to preinterventionally embolize the internal iliac artery to prevent retrograde perfusion of the aneurysm sac [37]. Alternatively, aneurysm treatment via iliac side branch prosthesis can be considered.

If these systems are not used, simultaneous closure of the contralateral internal iliac arteries or closure of both internal iliac arteries in an iliac aneurysm on both sides, i. e., endovascular repair, is relatively contraindicated even though individual case reports show that internal iliac artery closure on both sides can remain asymptomatic [38]. To allow complication-free passage of the stent graft (13–22 French), a diameter of the external iliac artery of at least 7 mm must be maintained to prevent dissection or vascular rupture. In the case of arterial occlusive disease, the vascular segment may need to be treated preinterventionally via stent angioplasty [25]. The length of the landing zone should be comparable to the aneurysm neck, i. e., approximately 10 mm to 15 mm [25]. An important aspect is the elongation and the resulting kinking of the iliac axis. This affects stent graft passage as well as stent apposition to the vascular wall. Angulation of the iliac axis $\geq 90^\circ$ is a relative contraindication for endovascular repair [25]. One possibility is the use of stiff wires that straighten the iliac axis and allow passage of the stent graft [39]. Calcification and mural thrombi additionally complicate passage of the stent graft and should be considered in connection with elongated iliac axes [25].

Visceral arteries

Accessory renal arteries can be reliably identified in preinterventional CTA to decide whether a possibly necessary closure of the arteries would result in an acceptable parenchymal loss [25]. Moreover, large lumbar arteries and the inferior mesenteric artery originating from the aneurysm sac should be visualized to determine whether embolization to prevent type II endoleak would be useful [29]. Brountzos et al. analyzed the predictors for a persistent type II endoleak on the basis of preoperative computed tomography scans of 136 AAA patients treated by endovascular repair. The rate of persistent type II endoleaks increases with the number of perfused aortic side branches on CTA while a circular thrombus has a protective effect on the development of type II endoleaks [40].

Advanced indications

▼ The aspects discussed above describe the general anatomical requirement for successful EVAR implantation. The following addresses the latest interventional techniques and prosthesis systems with which patients with the above „re-

lative“ contraindications can still be treated by endovascular repair in many cases. Since aneurysm severity correlates with age and comorbidities, the risk of open surgery with the necessity for reimplantation of the visceral arteries or ischemic time due to clamping of the aorta is significantly increased in this patient collective [41].

Special wire techniques in the case of significant kinking of the iliac arteries

Newer flexible prosthesis systems also require stiff wires in order to reliably anchor the system and to prevent graft jumping, prosthesis migration, or stent collapse [42]. However, primary passage via stiff wires is often not possible particularly in the case of significant twisting and kinking of the iliac axis. In the EUROSTAR Register, endovascular repair is unsuccessful in up to 13% of patients due to impossible passage of a stiff wire through the pelvic axis [43]. Different techniques for installing a so-called buddy wire to straighten the pelvic axis are described. These range from surgical iliac or aortic conduits to the so-called body flossing technique which uses a stiff wire between a left brachial and left femoral sheath to straighten the pelvic axis [44, 45]. While the conduit technique is used only rarely today because of the increased invasiveness and the associated complication rate, there are concerns regarding neurological complications in the case of the body flossing technique [45]. Ketelsen et al. described a step-by-step wire technique with a combination of flexible and stiff wires using a femoral access via which the pelvic axis can be incrementally straightened in order to place a stiff buddy wire and to allow secure graft implantation [46]. The technical success in $n=8$ patients was 100% and the endovascular prosthesis was able to be securely placed in all cases. Torsion stenoses caused by a so-called accordion effect of the iliac vessels and requiring treatment occurred after EVAR in 1 of 8 patients effectively treated by stent angioplasty [46].

Chimney and periscope technique

In recent years, the so-called chimney and periscope techniques have become established as an “off-the-shelf” solution for treating pararenal AAAs (► Fig. 1). Chimney grafts run between the aortic wall and the endovascular prosthesis in a cranial (chimney) or caudal (periscope graft) direction and thus allow perfusion of the visceral vessels covered by the aortic prosthesis [3, 47, 48]. Complex juxtarenal or pararenal aneurysms can be completely endovascularly repaired with this technique with revascularization of the celiac trunk, the superior mesenteric artery, and both renal arteries [3, 4]. Prior to release of the aortic stent graft, the affected visceral arteries are catheterized via a femoral or brachial or subclavian access with stiff wires and covered stents are introduced into the visceral arteries under sheath protection [3, 4, 47]. After release of the chimney or periscope grafts, the stents and the endovascular prosthesis dilate simultaneously (“kissing balloon”) to prevent collapse and to shape the landing zones of the aortic stent graft [49]. In addition to visual analysis of the flow dynamics, pressure measurements can be helpful postinterventionally to ensure proper perfusion of the visceral arteries [4]. There are concerns in particular with regard to the occurrence of type I endoleaks due to compromising of the landing zones. In a prospective

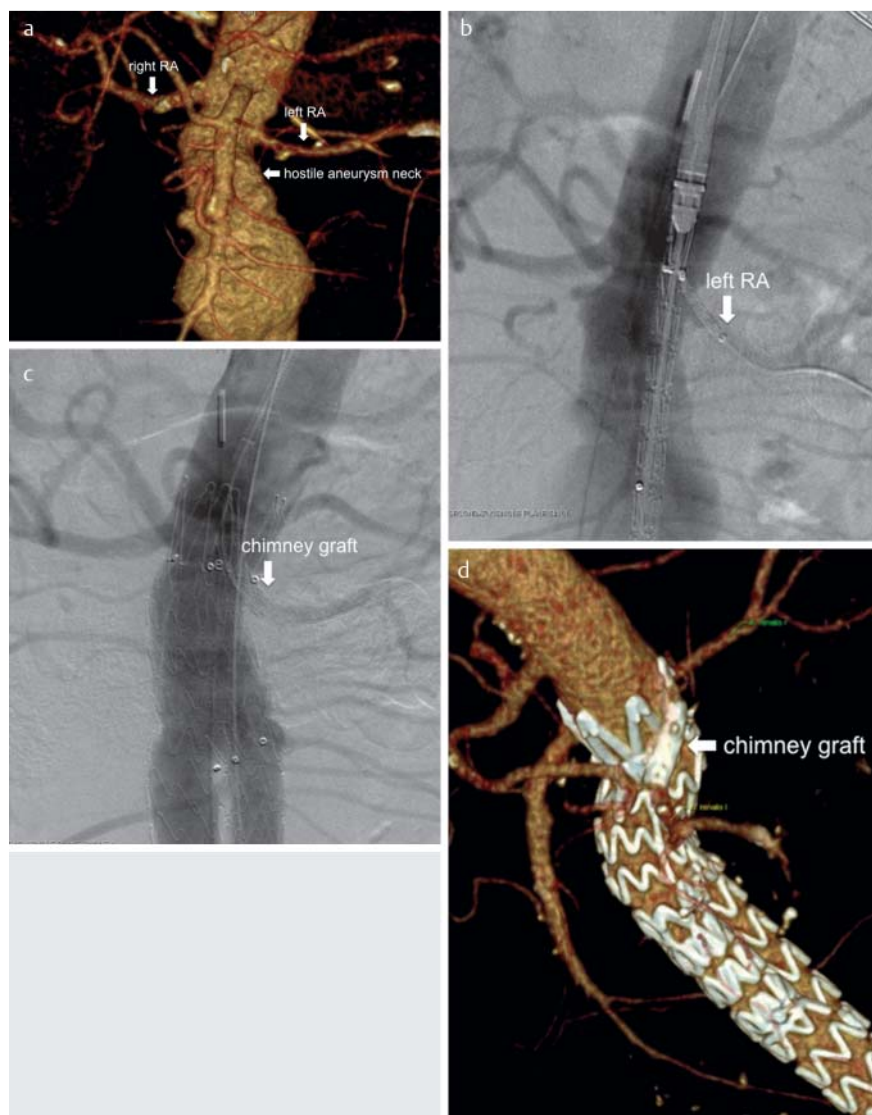


Fig. 1 a–d Chimney grafts. 71-year-old male patient with abdominal aortic aneurysm (AAA) with maximum diameter of 52 mm. The pre-interventional CT angiography (CTA) in volume rendering technique (VRT) shows a cone-shaped, short aneurysm neck **a**. To achieve sufficient graft fixation, the left renal artery has to be covered by the aortic stent graft. The pre-interventional angiogram **b** shows the aortic stent graft and the covered stent / chimney (Advanta V12 5/22 mm, Atrium Europe, SL Mijdrecht, The Netherlands) placed in the left renal artery via a left brachial access. After deployment of the aortic stent graft and the chimney graft, both stent grafts were dilated simultaneously with balloon catheters (not shown). The final angiogram **c** shows good perfusion of both renal arteries without any type I endoleak. The VRT of the post-interventional CTA shows the chimney graft running parallel to the aortic stent graft to preserve flow into the renal artery **d**.

observational study in 2 centers, Donas et al. [47] reported on 72 consecutive patients in whom 107 renal arteries, 14 mesenteric arteries, and 6 celiac trunks had to be recanalized via chimney grafts. Peri-interventional low-flow type Ia endoleaks of which only one required treatment were seen in 6 of 72 patients. One symptomatic renal artery occlusion occurred in the 30-day follow-up and was treated by surgical bypass. Persistent renal insufficiency or the necessity for long-term dialysis was not seen in any patient at the 1-year follow-up. The mortality rate was 0% [47]. Balloon-expandable bare metal stents and self-expanding nitinol stents were used as the chimney grafts. There were no significant differences between the two stent groups and the various endovascular prostheses [47]. Additional studies are necessary to evaluate whether the number of chimney or periscope grafts affects the occurrence of type I endoleaks. Moreover, the long-term patency of treated visceral arteries is of great importance [3]. Endovascular repair of pararenal aneurysms via chimney graft has proven effective particularly in acute situations and in high-risk patients due to the high primary technical success rate and the good results in the 1 and 2-year follow-up. This represents a good alterna-

tive to the demanding surgical repair of pararenal AAAs with a perioperative mortality rate of 3–19% [47, 50].

Fenestrated and branched prostheses

Fenestrated stent grafts are usually customized prostheses which allow perfusion of the visceral arteries via 5–8 mm openings (fenestrations) (Fig. 2). These fenestrations can be adjusted on an individual basis based on anatomical characteristics. During the procedure, the fenestrations that are reinforced by nitinol rings are connected to the visceral arteries via stent grafts [51]. Scallops can be made in the proximal prosthesis in the region of the landing zone, normally for supply of the superior mesenteric artery or the celiac trunk, in order to allow perfusion of a visceral artery [51]. The design of the fenestrated grafts should be planned with modern 3D vessel software to allow exact measurement even in significantly kinked aortic segments via center line reconstructions [51]. However, the above general contraindications which require certain anatomical conditions also apply when using these systems.

A series of peri-interventional radiopaque markers help with the placement of the fenestrated graft. Special carrier systems primarily allow only partial deployment of the endo-

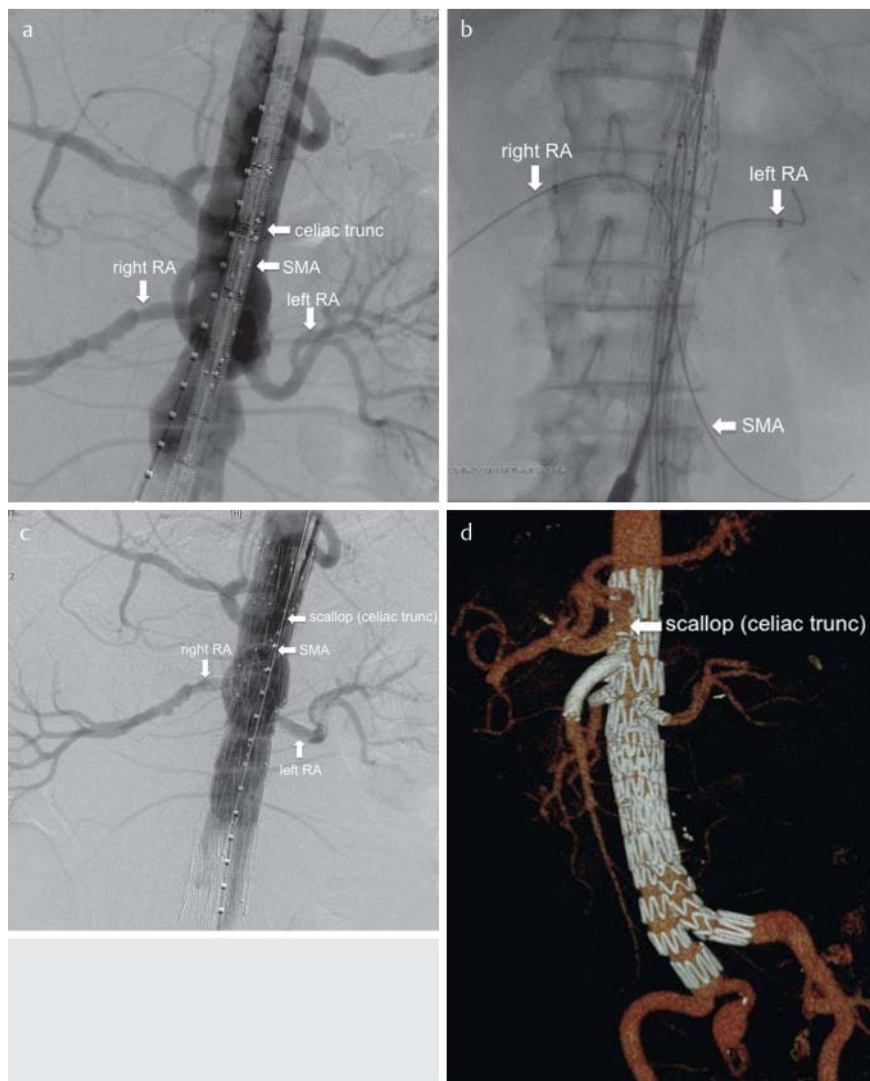


Fig. 2 a–d Fenestrated grafts (fEVAR). 64-year-old male patient with juxtarenal AAA and a maximum diameter of 56 mm. The initial angiogram **a** shows the pararenal aneurysm including the origins of the visceral arteries. After placement of the fenestrated aortic stent graft, the visceral arteries were catheterized via a femoral access and sheaths were placed into superior mesenteric and both renal arteries to allow an exact deployment of the fenestrated graft **b**. After final deployment of the fenestrated graft, the covered stents (Advanta V12, Atrium Europe, SL Mijdrecht, The Netherlands) were implanted and flaired inside the aorta to improve the seal and to avoid endoleaks. The perfusion of the celiac trunk is established by a scallop **c**. The final angiogram **c** and the postinterventional CTA-VRT **d** shows no endoleak and good perfusion of the visceral arteries via three fenestrations and one scallop (celiac trunk).

graft. After the accesses to the visceral arteries have been secured by sheaths or stiff wires, the fenestrated graft is released and the visceral arteries are then connected to the fenestrations via stents. To prevent endoleaks, fenestrations are primarily suitable for areas in healthy aortic segments with the fenestration in contact with the aortic wall and thus the branch of the visceral vessel.

In contrast, branched prostheses are suitable for treating visceral arteries in aneurysmatic aortic segments. The branch is used to bridge the gap between the stent graft and the aortic wall. Branched systems can be comprised of one or more modular parts. Moreover, the branches can run inside or outside the prosthesis [51]. Visceral branches normally run cranial to caudal so that catheterization and stent anchoring of the branches should be performed via a brachial access [51].

So-called iliac side branch systems that make revascularization of the iliac arteries on one or both sides possible are a further possibility for individualized prostheses (► Fig. 3) [52].

However, in contrast to the off-the-shelf chimney and periscope graft solutions, the mentioned prosthesis system is only available in elective situations due to the production times for the individualized grafts.

In a metaanalysis of 155 patients, Bakoyiannis et al. [53] reported a technical success rate of 94.2% for the implantation of fenestrated and branched endografts. The 30-day mortality rate was 7.1% and the 1-year survival rate was 82.6%. The periprocedural mortality rate could be significantly lowered by performing endovascular repair in these high-risk patients. The perioperative mortality rate after open surgical repair in a comparable patient collective is 5–34% [53]. In a retrospective study including 107 patients, Troisi et al. [50] reported the necessity for reinterventions after implantation of fenestrated and branched grafts. With a median follow-up of 25 months, 34 reinterventions were performed in 28 patients in a median period of the first reintervention of 12.9 months after prosthesis implantation. The causes of reintervention were graft stenosis or thrombosis (17.6%), in-stent restenosis or occlusion of the visceral arteries (23.5%), migration or type I endoleaks (31%) or type III endoleaks (35.3%). 23.5% of these complications had to be surgically revised. 77% of the patients survived the follow-up period (median 25 months). The most commonly reported complication, i.e., type III endoleak, was due to a disconnection of the visceral stent from the fenestration or branch. All type III endoleaks were able to be successfully treated by extending the stent [50].

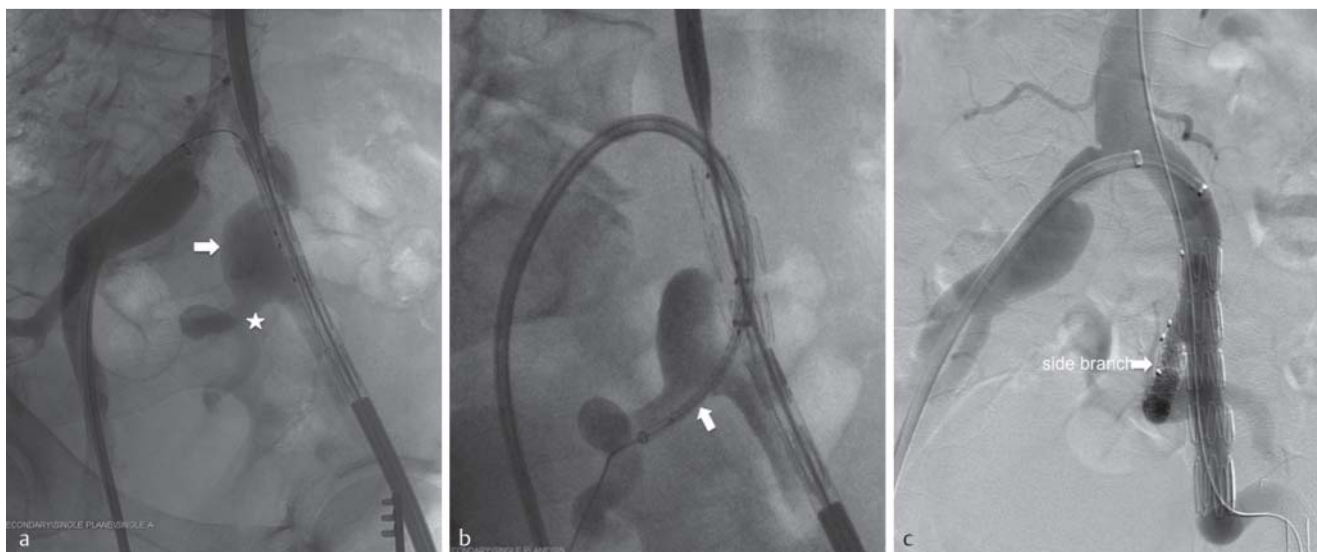


Fig. 3 a–c Iliac side branch. 71-year-old male patient with isolated iliac aneurysms on both sides **a** with a maximum diameter of 28 mm on the left. The left internal iliac artery is involved in the aneurysm (star). After placement of the iliac-side-branched graft via an ipsilateral femoral access, a 12F sheath from contralateral femoral access is placed in the branch after partial

deployment of the iliac side branch **b**. After complete deployment, a covered stent (Advanta V12, Atrium Europe, SL Mijdrecht, The Netherlands) was inserted into the internal iliac artery **b**. The final angiogram **c** after complete implantation of the iliac side branch shows an exclusion of the iliac aneurysm preserving the flow into the left internal iliac artery **c**.

Percutaneous vascular access

The femoral accesses in endovascular aneurysm repair require sheath sizes between 13F and 25F. The so-called pre-closing technique was first described by Haas et al. and allows minimally invasive off-label closure of the femoral arteries [55]. After a cutaneous stab incision, blunt preparation to the vascular wall, puncture of the common femoral artery, and insertion of a 6F sheath via a 0.035-inch guidewire, the sheath is removed and a percutaneous suture system (e.g. 10F Prostar XL Device; Abbott, Menlo Park, CA) is inserted into the common femoral artery via the guidewire and the guidewire is removed. The Prostar XL Device is comprised of 4 components: (1) a hydrophilic catheter with an inner lumen of 0.035 inches, (2) a marker lumen for documenting an intraarterial position, (3) a needle deployment system with a handle that inserts four needles and two braided sutures into the vascular wall when turned in a clockwise direction, and (4) a rotating barrel that receives the deployed nitinol needles in a non-traumatic manner. The sutures are then pulled out of the device, secured and positioned radially around the puncture site. After exchange of the guidewire, the suture system can be removed and a sheath with an outer diameter of up to 27F can be inserted [56]. After completion of the intervention and removal of the sheath under manual compression of the external iliac artery via a guidewire, the access point is closed using the two sutures with a modified fisherman's knot and a knot pusher.

In a prospective evaluation of the Prostar XL devices [57] in 500 patients ($n=903$ access vessels) with sheath sizes between 14F and 24F and a media follow-up of 28.5 ± 8.0 months, a primary success rate of the closure system could be achieved in 96.1% of cases. A revision of the access vessel was necessary in 3.9% of cases due to insufficient hemostasis ($n=4$), a false aneurysm ($n=4$), or arterial thrombosis

($n=3$). Severe calcifications of the common femoral artery, the experience of the interventionalist with the suture system (< 30 percutaneous closures), previous groin operations, and sheath size correlated significantly with the complication rate. Adiposity, defined as a body mass index > 35, had no effect on the complication rate [57].

The complication rate of the percutaneous access of 3.9% shows the advantages compared to open surgical repair. For a patient group of 186 patients with surgical groin incision during EVAR, Dalainas et al. reported wound complications in 14.5% of cases and the occurrence of lymphoceles in 4.8% of cases [58].

Endoleaks and treatment

Endoleaks are defined as persistent blood flow in the aneurysm sac after EVAR with an incidence of 10–50% [59].

Endoleak type I and graft migration

A type I endoleak is caused by insufficient apposition of the endograft to the aortic wall either at the proximal (type Ia) or distal (type Ib) end of the stent graft with persistent perfusion of the aneurysm sac. Risk factors for the occurrence of a type I endoleak are the configuration and length of the aneurysm neck and the landing zones [29]. One cause of a late type I endoleak is distal graft migration caused by graft failure in the region of the proximal anchoring with an incidence of 3.5–4.9% [60]. Graft migration represents the greatest risk factor for aneurysm rupture after EVAR [61].

Endoleak type II

Type II endoleaks are caused by retrograde perfusion of the aneurysm sac by the inferior mesenteric artery, the lumbar arteries, or rarely by other visceral vessels, e.g. accessory renal arteries. The data regarding the risk factors for develop-

ing type II endoleaks is contradictory. Individual studies view a large-caliber, perfused inferior mesenteric artery or more than two lumbar arteries visible on the preinterventional CTA as potential risk factors and discuss preinterventional coil embolization [62]. However, the course of type II endoleaks is usually benign and self-limiting and rarely results in a relevant increase in the aneurysm sac [63].

Endoleak type III

Type III endoleaks occur due to a disconnection of a prosthesis limb or due to a defect. While this complication is rare in newer prosthesis systems, type III endoleaks occur in up to 35.3% of cases in fenestrated and branched prostheses. However, these cases can be effectively treated with a stent extension into the visceral arteries [50].

Endoleak type IV

Type IV endoleaks are caused by porosity of the implant (graft porosity leak) but are very rare in newer implants [63].

Endoleak type V

The type V endoleak referred to as endotension describes an increasing diameter of the aneurysm sac without morphological evidence of an endoleak. The pathogenesis has not been definitively clarified [63].

Treatment of endoleaks

The risk of rupture after EVAR using the latest prosthesis systems is 0.6–0.7% per year according to the data of the EUROSTAR Register [64]. Type I and type III endoleaks are associated with a significant rupture risk and require early reintervention. Type I endoleaks are treated via balloon dilation of the proximal and distal landing zones to optimize the graft apposition and extension of the prosthesis components as necessary.

So-called endostapling is an innovative treatment concept for further active fixation of endovascular prostheses (● Fig. 4). Pathophysiologically speaking, the aortic wall is subjected to radial forces in the region of the proximal landing zone due to the deployment force of the endovascular prosthesis. If the radial force of the stent graft is greater

than the recoil of the elastic aortic wall, the treated aneurysm neck dilates with the risk of a type I endoleak or prosthesis migration [65] primarily in the long-term course after initial implantation. Commercially available endostapling devices (e.g. Aptus Endovascular AAA Repair System) allow subsequent fixation of the endovascular prosthesis to the aortic wall using helix screws that are screwed into the prosthesis/aortic wall via a specific system to prevent longitudinal migration and to reduce rotation forces [66]. Donas et al. evaluated an endostapling device in a prospective study in 8 patients in whom the endovascular prosthesis had already been additionally secured in the primary intervention. No device-based complications, prosthesis migration, endoleaks, or operative conversions occurred peri-interventionally and in the median follow-up of 18.2 ± 2.2 months [67]. Long-term results to rule out prosthesis migration and type I endoleaks in the long-term course are not available. A further option for treating a type Ia endoleak was described by Rajani et al. who stabilized the pros-

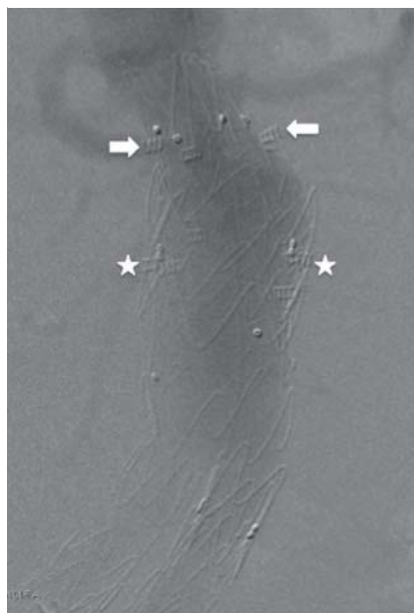


Fig. 4 Endostapling. 69-year-old male patient with graft migration after EVAR 9 years ago. After fixation of the migrated TALENT Graft (stars) (Medtronic, Meerbusch, Germany), the aortic stent graft was extended proximally by an abdominal tube (Endurant II Endoprothese; Medtronic, Meerbusch, Germany) with suprarenal fixation. Due to the cone-shaped aneurysm neck and oversizing, the abdominal tube was also fixed by endostapling (arrow).

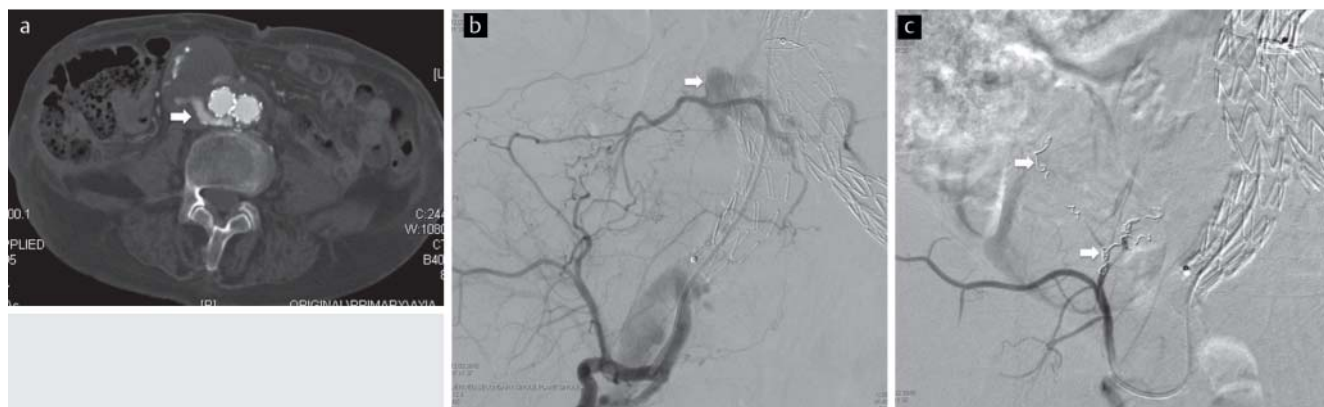

Fig. 5 a–c Treatment of type II endoleak. 84 years old male patient with EVAR one week ago. The postinterventional CTA shows a type II endoleak with substantial perfusion of the aneurysm sack a. The selective angiogram of the right internal iliac artery via a brachial access shows a typical type II

endoleak supplied by a lumbar artery b. After selective coil embolization of the feeding arteries c there was no evidence for persistent type II endoleak in the angiograms as well as in the postinterventional CTA (not shown).

thesis neck with a self-expanding stent already in the primary intervention in the case of verifiable type Ia endoleak in order to achieve better graft apposition [68].

For example, visceral stent grafts are extended to treat type III endoleaks [63].

The clinical significance of type II and type IV endoleaks is unclear and there is currently no consensus regarding treatment strategy. In individual cases, coil embolization (► Fig. 5) or laparoscopic vessel ligation is a feasible treatment option [63].

Type V endoleaks or type I-IV endoleaks that cannot be managed interventionally may need to be treated by open surgical conversion [63].

Follow-up

Follow-up after EVAR should be performed according to the EUROSTAR guidelines or the guidelines of the German Society for Vascular Surgery [69]. The recommendations include a CTA in the arterial and venous phase to detect complications. The first follow-up is performed starting on the third postoperative day prior to discharge. In the first year follow-ups after 3, 6, and 12 months and then annual and later biennial CT angiography scans are recommended. This corresponds to a radiation exposure within 5 years after EVAR of 145 mSv to 205 mSv as a result of the CT examinations [70]. A radiation exposure of 145 mSv corresponds to a lifetime-attributable malignancy risk from CT angiography of 0.42% (1 in 240) for a 70-year-old man to a radiation exposure-based malignancy risk of 0.73% (1 in 140) for a 50-year-old woman [70].

The risk of this cumulative radiation exposure results increasingly in the establishment of alternative examination methods that have not yet been included in the guidelines. Possible alternatives include single-phase CTA in the arterial phase for detecting treatment-relevant endoleaks or MR angiography in the arterial and venous phase or contrast-enhanced ultrasound with comparable sensitivity for the detection of endoleaks after EVAR [71–75].

Acknowledgement

The authors dedicate this article to Prof. Dr. Claus D. Clausen in occasion of his retirement.

References

- 1 Parodi JC. Endovascular repair of abdominal aortic aneurysms and other arterial lesions. *Surg Technol Int* 1994; 3: 431–436
- 2 Ricotta JJ 2nd, Malgor RD, Oderich GS. Endovascular abdominal aortic aneurysm repair: part I. *Annals of vascular surgery* 2009; 23: 799–812
- 3 Brechtel K, Ketelsen D, Endisch A et al. Endovascular repair of acute symptomatic pararenal aortic aneurysm with three chimney and one periscope graft for complete visceral artery revascularization. *Cardiovascular and interventional radiology* 2012; 35: 413–417
- 4 Lachat M, Frauenfelder T, Mayer D et al. Complete endovascular renal and visceral artery revascularization and exclusion of a ruptured type IV thoracoabdominal aortic aneurysm. *J Endovasc Ther* 2010; 17: 216–220
- 5 Wagner M, Voshage G, Busch T et al. Infrarenales Bauchortenaneurysma. *Radiologe* 2008; 48: 881–898
- 6 Eliason JL, Upchurch GR Jr. Endovascular abdominal aortic aneurysm repair. *Circulation* 2008; 117: 1738–1744
- 7 Greenhalgh RM, Powell JT. Endovascular repair of abdominal aortic aneurysm. *N Engl J Med* 2008; 358: 494–501
- 8 Brewster DC, Cronenwett JL, Hallett JW Jr et al. Guidelines for the treatment of abdominal aortic aneurysms. Report of a subcommittee of the Joint Council of the American Association for Vascular Surgery and Society for Vascular Surgery. *J Vasc Surg* 2003; 37: 1106–1117
- 9 Nevitt MP, Ballard DJ, Hallett JW Jr. Prognosis of abdominal aortic aneurysms. A population-based study. *N Engl J Med* 1989; 321: 1009–1014
- 10 Brown LC, Powell JT. Risk factors for aneurysm rupture in patients kept under ultrasound surveillance. UK Small Aneurysm Trial Participants. *Ann Surg* 1999; 230: 289–296 discussion 296–287
- 11 Fillinger MF, Raghavan ML, Marra SP et al. In vivo analysis of mechanical wall stress and abdominal aortic aneurysm rupture risk. *J Vasc Surg* 2002; 36: 589–597
- 12 Limet R, Sakalikhassan N, Albert A. Determination of the expansion rate and incidence of rupture of abdominal aortic aneurysms. *J Vasc Surg* 1991; 14: 540–548
- 13 Steyerberg EW, Kievit J, de Mol Van Otterloo JC et al. Perioperative mortality of elective abdominal aortic aneurysm surgery. A clinical prediction rule based on literature and individual patient data. *Arch Intern Med* 1995; 155: 1998–2004
- 14 Winterborn RJ, Amin I, Lyraztopoulos G et al. Preferences for endovascular (EVAR) or open surgical repair among patients with abdominal aortic aneurysms under surveillance. *J Vasc Surg* 2009; 49: 576–581 e573
- 15 EVAR trial participants. Endovascular aneurysm repair versus open repair in patients with abdominal aortic aneurysm (EVAR trial 1): randomised controlled trial. *Lancet* 2005; 365: 2179–2186
- 16 Greenhalgh RM, Brown LC, Kwong GP et al. Comparison of endovascular aneurysm repair with open repair in patients with abdominal aortic aneurysm (EVAR trial 1), 30-day operative mortality results: randomised controlled trial. *Lancet* 2004; 364: 843–848
- 17 Greenhalgh RM, Brown LC, Powell JT et al. Endovascular versus open repair of abdominal aortic aneurysm. *N Engl J Med* 2010; 362: 1863–1871
- 18 EVAR trial participants. Endovascular aneurysm repair and outcome in patients unfit for open repair of abdominal aortic aneurysm (EVAR trial 2): randomised controlled trial. *Lancet* 2005; 365: 2187–2192
- 19 Blankensteijn JD, de Jong SE, Prinssen M et al. Two-year outcomes after conventional or endovascular repair of abdominal aortic aneurysms. *N Engl J Med* 2005; 352: 2398–2405
- 20 Lederle FA, Freischlag JA, Kyriakides TC et al. Outcomes following endovascular vs open repair of abdominal aortic aneurysm: a randomized trial. *JAMA* 2009; 302: 1535–1542
- 21 Brown L, Powell J, Thompson S et al. The UK Endovascular Aneurysm Repair (EVAR) trials: randomised trials of EVAR versus standard therapy. *Health Technol Assess* 2012; 16: 1–218
- 22 Leurs IJ, Buth J, Harris PL et al. Impact of study design on outcome after endovascular abdominal aortic aneurysm repair. A comparison between the randomized controlled DREAM-trial and the observational EUROSTAR-registry. *European journal of vascular and endovascular surgery: the official journal of the European Society for Vascular Surgery* 2007; 33: 172–176
- 23 De Bruin JL, Baas AF, Buth J et al. Long-term outcome of open or endovascular repair of abdominal aortic aneurysm. *The New England journal of medicine* 2010; 362: 1881–1889
- 24 Alsac JM, Desgranges P, Kobeiter H et al. Emergency endovascular repair for ruptured abdominal aortic aneurysms: feasibility and comparison of early results with conventional open repair. *European journal of vascular and endovascular surgery: the official journal of the European Society for Vascular Surgery* 2005; 30: 632–639
- 25 Iezzi R, Cotroneo AR. Endovascular repair of abdominal aortic aneurysms: CTA evaluation of contraindications. *Abdom Imaging* 2006; 31: 722–731
- 26 Rockman C. Reducing complications by better case selection: anatomic considerations. *Semin Vasc Surg* 2004; 17: 298–306
- 27 Schanzer A, Greenberg RK, Hevelone N et al. Predictors of abdominal aortic aneurysm sac enlargement after endovascular repair. *Circulation* 2011; 123: 2848–2855
- 28 Arko FR, Filis KA, Seidel SA et al. How many patients with infrarenal aneurysms are candidates for endovascular repair? The Northern California experience. *Journal of endovascular therapy: an official journal of the International Society of Endovascular Specialists* 2004; 11: 33–40
- 29 Armerding MD, Rubin GD, Beaulieu CF et al. Aortic aneurysmal disease: assessment of stent-graft treatment-CT versus conventional angiography. *Radiology* 2000; 215: 138–146

- 30 Sternbergh WC 3rd, Carter G, York JW et al. Aortic neck angulation predicts adverse outcome with endovascular abdominal aortic aneurysm repair. *Journal of vascular surgery: official publication, the Society for Vascular Surgery [and] International Society for Cardiovascular Surgery, North American Chapter* 2002; 35: 482–486
- 31 Balm R, Stokking R, Kaatee R et al. Computed tomographic angiographic imaging of abdominal aortic aneurysms: implications for transfemoral endovascular aneurysm management. *Journal of vascular surgery: official publication, the Society for Vascular Surgery [and] International Society for Cardiovascular Surgery, North American Chapter* 1997; 26: 231–237
- 32 Stanley BM, Semmens JB, Mai Q et al. Evaluation of patient selection guidelines for endoluminal AAA repair with the Zenith Stent-Graft: the Australasian experience. *Journal of endovascular therapy: an official journal of the International Society of Endovascular Specialists* 2001; 8: 457–464
- 33 Peppelenbosch N, Buth J, Harris PL et al. Diameter of abdominal aortic aneurysm and outcome of endovascular aneurysm repair: does size matter? A report from EUROSTAR. *J Vasc Surg* 2004; 39: 288–297
- 34 Lange C, Hobo R, Leurs LJ et al. Results of endovascular repair of inflammatory abdominal aortic aneurysms. A report from the EUROSTAR database. *European journal of vascular and endovascular surgery: the official journal of the European Society for Vascular Surgery* 2005; 29: 363–370
- 35 Ahn SS, Ro KM. Design of endovascular grafts for abdominal aortic aneurysm repair. *Ann Vasc Surg* 2001; 15: 123–127
- 36 Carpenter JP, Baum RA, Barker CF et al. Impact of exclusion criteria on patient selection for endovascular abdominal aortic aneurysm repair. *J Vasc Surg* 2001; 34: 1050–1054
- 37 Yano OJ, Morrissey N, Eisen L et al. Intentional internal iliac artery occlusion to facilitate endovascular repair of aortoiliac aneurysms. *Journal of vascular surgery: official publication, the Society for Vascular Surgery [and] International Society for Cardiovascular Surgery, North American Chapter* 2001; 34: 204–211
- 38 Engelke C, Elford J, Morgan RA et al. Internal iliac artery embolization with bilateral occlusion before endovascular aortoiliac aneurysm repair-clinical outcome of simultaneous and sequential intervention. *JVIR* 2002; 13: 667–676
- 39 Dawson DL, Hellinger JC, Terramani TT et al. Iliac artery kinking with endovascular therapies: technical considerations. *JVIR* 2002; 13: 729–733
- 40 Brountzos E, Karagiannis G, Panagiotou I et al. Risk factors for the development of persistent type II endoleaks after endovascular repair of infrarenal abdominal aortic aneurysms. *Diagn Interv Radiol* 2012; 18: 307–313
- 41 Dias NV, Ivancev K, Malina M et al. Does the wide application of endovascular AAA repair affect the results of open surgery? *European journal of vascular and endovascular surgery: the official journal of the European Society for Vascular Surgery* 2003; 26: 188–194
- 42 Peterson BG, Matsumura JS. Creative options for large sheath access during aortic endografting. *J Vasc Interv Radiol* 2008; 19: S22–S26
- 43 Cuypers PW, Laheij RJ, Buth J. Which factors increase the risk of conversion to open surgery following endovascular abdominal aortic aneurysm repair? The EUROSTAR collaborators. *Eur J Vasc Endovasc Surg* 2000; 20: 183–189
- 44 Criado FJ. Iliac arterial conduits for endovascular access: technical considerations. *J Endovasc Ther* 2007; 14: 347–351
- 45 Criado FJ, Wilson EP, Abul-Khoudoud O et al. Brachial artery catheterization to facilitate endovascular grafting of abdominal aortic aneurysm: safety and rationale. *J Vasc Surg* 2000; 32: 1137–1141
- 46 Ketelsen D, Bail D, Heuschmid M et al. A Technical Approach for Transfemoral Managing of Hostile Angulated Pelvic Vessel Access in Abdominal Endovascular Aneurysm Repair: A New Technique for Establishing a Buddy Wire. *Fortschr Röntgenstr* 2012; 184: 899–904
- 47 Donas KP, Pecoraro F, Torsello G et al. Use of covered chimney stents for pararenal aortic pathologies is safe and feasible with excellent patency and low incidence of endoleaks. *Journal of vascular surgery: official publication, the Society for Vascular Surgery [and] International Society for Cardiovascular Surgery, North American Chapter* 2012; 55: 659–665
- 48 Ketelsen D, Kalender G, Heuschmid M et al. Endovascular aneurysm repair using a reverse chimney technique in a patient with Marfan syndrome and contained ruptured chronic type B dissection. *Cardiovascular and interventional radiology* 2011; 34: 1080–1084
- 49 Mayer D, Rancic Z, Pfammatter T et al. Choice of treatment for the patient with urgent AAA: practical tips. *The Journal of cardiovascular surgery* 2009; 50: 595–598
- 50 Troisi N, Donas KP, Austermann M et al. Secondary procedures after aortic aneurysm repair with fenestrated and branched endografts. *J Endovasc Ther* 2011; 18: 146–153
- 51 Malina M, Resch T, Sonesson B. EVAR and complex anatomy: an update on fenestrated and branched stent grafts. *Scand J Surg* 2008; 97: 195–204
- 52 Donas KP, Torsello G, Pitoulias GA et al. Surgical versus endovascular repair by iliac branch device of aneurysms involving the iliac bifurcation. *Journal of vascular surgery: official publication, the Society for Vascular Surgery [and] International Society for Cardiovascular Surgery, North American Chapter* 2011; 53: 1223–1229
- 53 Bakoyiannis CN, Economopoulos KP, Georgopoulos S et al. Fenestrated and branched endografts for the treatment of thoracoabdominal aortic aneurysms: a systematic review. *Journal of endovascular therapy: an official journal of the International Society of Endovascular Specialists* 2010; 17: 201–209
- 54 Natrella M, Castagnola M, Navarretta F et al. Treatment of juxtarenal aortic aneurysm with the Multilayer stent. *Journal of endovascular therapy: an official journal of the International Society of Endovascular Specialists* 2012; 19: 121–124
- 55 Haas PC, Krajcer Z, Diethrich EB. Closure of large percutaneous access sites using the Prostar XL Percutaneous Vascular Surgery device. *Journal of endovascular surgery: the official journal of the International Society for Endovascular Surgery* 1999; 6: 168–170
- 56 Starnes BW, Andersen CA, Ronsivalle JA et al. Totally percutaneous aortic aneurysm repair: experience and prudence. *Journal of vascular surgery: official publication, the Society for Vascular Surgery [and] International Society for Cardiovascular Surgery, North American Chapter* 2006; 43: 270–276
- 57 Eisenack M, Umscheid T, Tessarek J et al. Percutaneous endovascular aortic aneurysm repair: a prospective evaluation of safety, efficiency, and risk factors. *Journal of endovascular therapy: an official journal of the International Society of Endovascular Specialists* 2009; 16: 708–713
- 58 Dalainas I, Nano G, Casana R et al. Mid-term results after endovascular repair of abdominal aortic aneurysms: a four-year experience. *European journal of vascular and endovascular surgery: the official journal of the European Society for Vascular Surgery* 2004; 27: 319–323
- 59 Norwood MG, Lloyd GM, Bown MJ et al. Endovascular abdominal aortic aneurysm repair. *Postgrad Med J* 2007; 83: 21–27
- 60 Leurs LJ, Laheij RJ, Buth J. What determines and are the consequences of surveillance intensity after endovascular abdominal aortic aneurysm repair? *Annals of vascular surgery* 2005; 19: 868–875
- 61 Chuter TA, Parodi JC, Lawrence-Brown M. Management of abdominal aortic aneurysm: a decade of progress. *Journal of endovascular therapy: an official journal of the International Society of Endovascular Specialists* 2004; 11: I182–I195
- 62 Arko FR, Rubin GD, Johnson BL et al. Type-II endoleaks following endovascular AAA repair: preoperative predictors and long-term effects. *Journal of endovascular therapy: an official journal of the International Society of Endovascular Specialists* 2001; 8: 503–510
- 63 Hinchliffe RJ, Ivancev K. Endovascular aneurysm repair: current and future status. *Cardiovascular and interventional radiology* 2008; 31: 451–459
- 64 Lindholt JS. Endovascular aneurysm repair. *Lancet* 2004; 364: 818–820
- 65 Malas MB, Ohki T, Veith FJ et al. Absence of proximal neck dilatation and graft migration after endovascular aneurysm repair with balloon-expandable stent-based endografts. *J Vasc Surg* 2005; 42: 639–644
- 66 Donas KP, Kafetzakis A, Umscheid T et al. Vascular endostapling: new concept for endovascular fixation of aortic stent-grafts. *J Endovasc Ther* 2008; 15: 499–503
- 67 Donas KP, Torsello G. Midterm results of the Anson Refix endostapling fixation system for aortic stent-grafts. *J Endovasc Ther* 2010; 17: 320–323
- 68 Rajani RR, Arthurs ZM, Srivastava SD et al. Repairing immediate proximal endoleaks during abdominal aortic aneurysm repair. *J Vasc Surg* 2011; 53: 1174–1177
- 69 Harris PL, Buth J, Mialhe C et al. The need for clinical trials of endovascular abdominal aortic aneurysm stent-graft repair: The EUROSTAR Project. EUROPEAN collaborators on Stent-graft Techniques for abdominal aortic Aneurysm Repair. *Journal of endovascular surgery: the offi-*

- cial journal of the International Society for Endovascular Surgery 1997; 4: 72–77 discussion 78–79
- 70 White HA, Macdonald S. Estimating risk associated with radiation exposure during follow-up after endovascular aortic repair (EVAR). *The Journal of cardiovascular surgery* 2010; 51: 95–104
- 71 Cantisani V, Ricci P, Grazhdani H *et al.* Prospective comparative analysis of colour-Doppler ultrasound, contrast-enhanced ultrasound, computed tomography and magnetic resonance in detecting endoleak after endovascular abdominal aortic aneurysm repair. *European journal of vascular and endovascular surgery: the official journal of the European Society for Vascular Surgery* 2011; 41: 186–192
- 72 Kranokpiraksa P, Kaufman JA. Follow-up of endovascular aneurysm repair: plain radiography, ultrasound, CT/CT angiography, MR imaging/MR angiography, or what? *JVIR* 2008; 19: S27–S36
- 73 Truijers M, Resch T, Van Den Berg JC *et al.* Endovascular aneurysm repair: state-of-art imaging techniques for preoperative planning and surveillance. *The Journal of cardiovascular surgery* 2009; 50: 423–438
- 74 Uthoff H, Pena C, Katzen BT *et al.* Current clinical practice in postoperative endovascular aneurysm repair imaging surveillance. *JVIR* 2012; 23: 1152–1159 e1156
- 75 Verhoeven EL, Oikonomou K, Ventin FC *et al.* Is it time to eliminate CT after EVAR as routine follow-up? *JVIR* 52: 193–198