

A Case of Recurrent Anaplastic Meningioma of the Skull Base with Radiologic Response to Hydroxyurea

Joshua Gurberg¹ Nathaniel Bouganim² George Shenouda³ Anthony Zeitouni⁴

¹Division of Otolaryngology–Head and Neck Surgery, The University of British Columbia, Vancouver, British Columbia, Canada

²Department of Oncology, McGill University, Montreal, Quebec, Canada

³Department of Radiation Oncology, McGill University, Montreal, Quebec, Canada

⁴Department of Otolaryngology–Head and Neck Surgery, Royal Victoria Hospital, McGill University Health Center, Montreal, Quebec, Canada

Address for correspondence Dr. Anthony Zeitouni, MD, MSc, Department of Otolaryngology–Head and Neck Surgery, Royal Victoria Hospital, Room E4.45, 687 Pine Avenue West, Montreal, QC, H3A 1A1, Canada (e-mail: Anthony.Zeitouni@mcgill.ca).

J Neurol Surg Rep 2014;75:e52–e55.

Abstract

Anaplastic meningiomas are rare and aggressive tumors with a high propensity for local recurrence. Surgical resection and postoperative radiotherapy are the standard of care for primary disease and local recurrences. Refractory disease is managed with chemotherapy with limited success. A highly efficacious, well-tolerated chemotherapeutic agent has yet to be found for this disease entity. Hydroxyurea is currently receiving renewed attention because of its efficacy in inducing apoptosis of meningioma cells in vitro and its favorable side-effect profile. Thus far, in humans, this agent has only induced stable disease.

Keywords

- ▶ meningioma
- ▶ anaplastic meningioma
- ▶ hydroxyurea
- ▶ radiotherapy
- ▶ recurrent
- ▶ malignant transformation

We describe the first patient showing a near complete/partial clinical and radiological regression after 5 months of 25 mg/kg of hydroxyurea once daily, given within 1 month after stereotactic fractionated reirradiation of a previously irradiated and operated anaplastic meningioma of the skull base. Magnetic resonance imaging showed a significant and sustained response with tumor shrinkage and cavitation.

Introduction

Meningiomas account for 13 to 26% of intracranial neoplasms.¹ Of these, 2 to 3% are anaplastic (World Health Organization [WHO] grade III) as characterized by neoplastic cytologic features and a high mitotic index.^{2,3} These lesions rarely metastasize but commonly recur, especially if they are subtotally excised, located at the skull base, or infiltrate the brain parenchyma.^{1,4} Anaplastic meningiomas carry a particularly poor prognosis, with a median survival time of 1.5 years and a 5-year mortality of 68%.¹

The current standard of care for anaplastic meningiomas, at initial presentation, is surgery followed by postoperative fractionated radiotherapy.⁵ For recurrent meningiomas, if the tumor is not surgically accessible and reirradiation is not possible, chemotherapy is then attempted.⁵ Options include cytotoxic agents, hormonal therapy, and targeted agents.² One agent being aggressively pursued is hydroxyurea (HU), a selective inhibitor of ribonucleoside diphosphate reductase, because of its ability to induce apoptosis of meningioma cells in vitro, ease of administration, and acceptable toxicity profile.^{6,7} Thus far, many case series have only shown HU

received
April 12, 2013
accepted after revision
September 17, 2013
published online
April 17, 2014

DOI <http://dx.doi.org/10.1055/s-0033-1359300>.
ISSN 2193-6358.

© 2014 Georg Thieme Verlag KG
Stuttgart · New York

License terms



to induce stable disease, with no documented objective radiologic responses.²

This article reviews the literature pertaining to the use of HU for anaplastic meningioma and presents a report of the only known case of partial response to HU given after reirradiation for a recurrent anaplastic meningioma of the skull base.

Case Report

The patient is a 58 year-old female professor who first presented to the Head and Neck clinic in October 2008 with left-sided facial pain, otalgia, and aural fullness. She was a smoker and had a past history of cataract surgery, salpingo-oophorectomy for severe endometriosis, and left otitis media with effusion requiring pressure equalization tube several months prior. Physical examination revealed a left-sided V2/V3 dyesthesia and a left middle ear effusion. Magnetic resonance imaging (MRI) with gadolinium infusion of the base of the skull demonstrated a left $2.8 \times 2.8 \times 3.3$ cm isointense left infratemporal fossa mass involving the left wing of the sphenoid and pterygopalatine fossa, extending through the foramen ovale to involve the meninges of the left middle cranial fossa. Endoscopically guided biopsy using a transnasal and trans-antral pterygopalatine approach demonstrated a WHO grade I meningioma. The consensus at the tumor board was to recommend treatment with stereotactic fractionated radiotherapy. Instead, the patient sought a second opinion and underwent gamma knife radiosurgery at an outside institution in November 2008, where she received a dose of 12 Gy in a single fraction with a peripheral dose of 12 Gy covering 98% of the tumor volume (30.1 cc) with a maximal dose of 24 Gy. The maximal dose to the optic structures did not exceed 4 Gy. She was followed periodically with imaging that revealed interval stability of the residual tumor mass.

In October 2011, the patient returned to the clinic with headache, facial pain, respiratory difficulty, and nasopharyngeal reflux. MRI revealed local recurrence of the tumor invading the left masticator and parapharyngeal spaces and at the skull base with cortical bone invasion of the left mandibular ramus. A metastatic work-up did not demonstrate distant spread. With tumor board consensus, the patient underwent a wide local excision of the mass via a left lateral rhinotomy with a left maxillectomy, left partial palatotomy, and left level I–III neck dissection. Pathology revealed anaplastic (WHO grade III) meningioma with positive surgical margins. She then received adjuvant reirradiation consisting of fractionated stereotactic radiotherapy of 60 Gy in 30 daily fractions of 2 Gy each over an overall treatment time of 6 weeks. The treatment was delivered using 6 MV photons on a Novalis linear accelerator and BrainLab planning system. The planning target volume (PTV) consisted of the gross tumor volume with a 3-mm margin. The patient was immobilized using a relocatable mask with daily verification using kv-kv verification. The reirradiation was given with concomitant Temodol (75 mg/m² daily) ending in March 2012.

Unfortunately, in April 2012 the patient presented to the emergency department with epistaxis, and MRI revealed progression of the mass with increased invasion of the left temporal bone and orbit (►Figs. 1A, 1C). At this point palliative care was consulted, and medical oncology began a palliative course of HU 1800 mg daily by mouth, subsequently reduced to 1500 mg because of grade 3 pancytopenia. Surprisingly, after 5 months of therapy, follow-up MRI in September 2012 demonstrated a significant interval decrease in tumor volume with cavitation of the lesion (►Figs. 1B, 1D). The patient is currently doing well on 1500 mg HU daily.

Discussion

To our knowledge, this is the first reported case of a WHO grade III meningioma with an objective radiologic response to HU following reirradiation. Several clinical studies of HU have been published including patients with WHO grade III meningiomas (►Table 1). In 1997, Schrell and colleagues evaluated the activity of HU (20 mg/kg/day) in four patients with recurrent unresectable meningiomas. The one patient harboring a WHO grade III tumor had no shrinkage of the tumor but had disease stabilization over 24 months of therapy.⁸ In a similar study, Mason et al evaluated the efficacy of 20–30 mg/kg/day HU in a cohort of 20 patients over a 2-year treatment period. The one patient with a grade III malignant neoplasm had progressive disease on neuroimaging after 24 weeks of therapy.⁹

Hahn and colleagues evaluated the use of 20 mg/kg/day HU and concurrent conformational radiation therapy for 12 weeks in 21 patients with recurrent or progressive disease.³ The two patients with WHO grade III lesions had no radiologic responses to treatment with a median progression-free survival time of 13 months.³ In another modification, Reardon and associates evaluated the effect of 500 mg HU given twice a day along with imatinib 400 to 1000 mg daily. Four patients had grade III lesions, and the best response was stable disease and only 46.2% progression-free survival at 6 months.¹⁰

In 2012, Chamberlain published a retrospective case series focusing on high-grade lesions that consisted of 22 patients with WHO grade II and 13 patients with WHO grade III recurrent meningiomas treated with 1000 mg/m² HU.⁷ There were no radiologic responses.⁷

Thus HU has been used in 21 patients with anaplastic meningioma without a single objective radiologic response (►Table 1). Our patient, like these others, is in her 6th decade of life and had already had disease progression after two courses of radiotherapy, Temodol, and surgery. The dose of HU and dosing schedule were also similar. However, this patient differed from most of the described cases in that she had been previously treated with Temodol chemotherapy and that the time between completing reirradiation and beginning HU was < 1 month.

One must ask why this patient responded when the other 21 did not. There are several possibilities. Perhaps the number needed to treat with HU is such that one has not seen the full

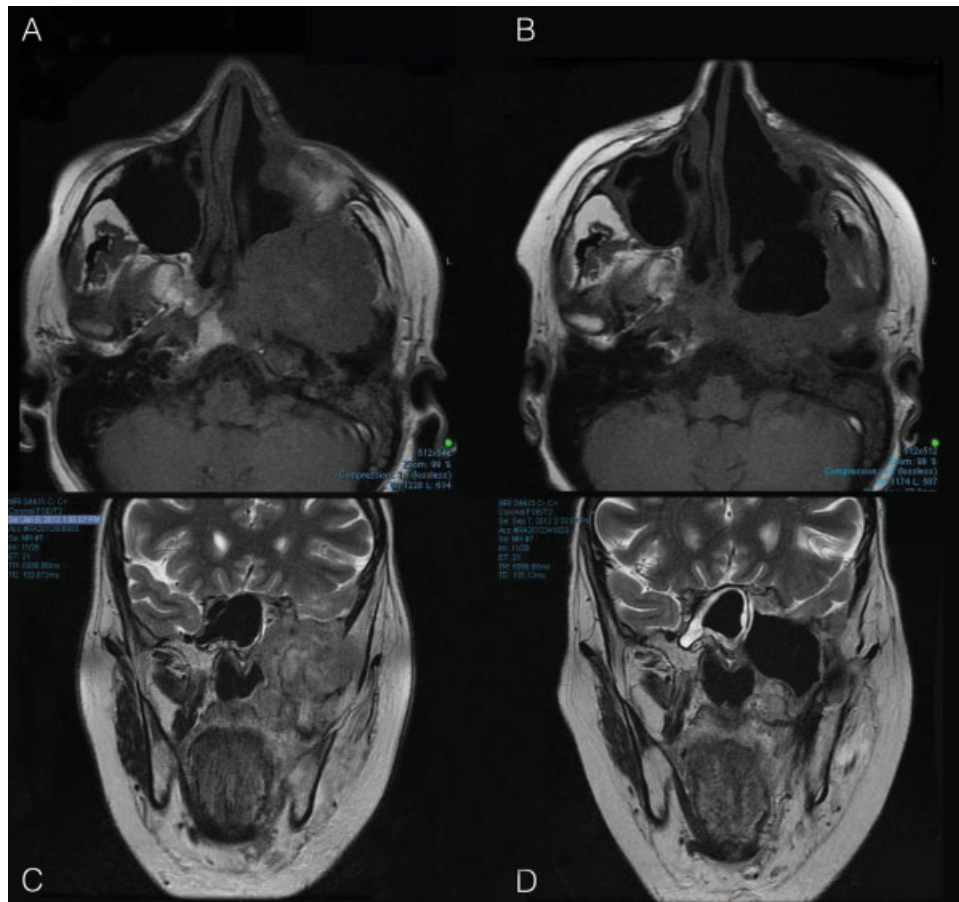


Fig. 1 Magnetic resonance Imaging of the sinuses (A) April 2012 axial, (B) September 2012 axial, (C) April 2012 coronal, (D) September 2012 coronal. Pre- and post-hydroxyurea demonstrating a significant objective radiologic response.

effect of this agent with such a small number of cases. An interaction between HU and the previously administered Temodol is also possible. More plausible, however, is an interaction between HU and the stereotactic reirradiation therapy that was given shortly before the drug.

Before discussing the possible interaction between ionizing radiation and HU, the interaction between ionizing radiation (IR) and tumor progression is of interest. Several cases have been reported in the literature describing malignant transformation of meningioma after gamma knife radiosurgery (GKR)¹¹⁻¹⁴. In the present case, the patient's meningioma was first classified as WHO grade I in 2008; however, it recurred as WHO grade III disease, 3 years after GKR. This is yet another example of possible progression of benign meningioma secondary to GKR. However, as discussed by Kubo and colleagues in their case series on this topic, the histologic diagnosis of irradiation-induced malignant transformation is extremely challenging, and the relationship may in fact be the result of GKR being used to treat recurrent disease that may have actually transformed prior to irradiation.¹¹

In discussing the temporal relationship between HU and reirradiation of the lesion, it is important to mention that in the Hahn et al study,³ concurrent HU and radiotherapy only induced stable disease. There are, however, intriguing reports

in the basic science literature of the effects of HU administered closely after ionizing radiation. HU is an inhibitor of the DNA repair enzyme ribonucleotide reductase (RR). The molecular target of HU is the tyrosyl radical of the R₂ subunit of the RR enzyme. By inhibiting the RR, HU inhibits the conversion of the ribonucleotide phosphates to deoxyribonucleotide forms that are essential for DNA synthesis and repair. Many investigators have studied the temporal relationship of the interaction of HU and IR. In 1997, Kuo and colleagues studied the effect of sequencing of HU exposure before and after IR exposure in human cancer cell lines. The authors reported a larger degree of radiosensitization when HU shortly followed IR as compared with HU delivered before IR.¹⁵ The proposed mechanism of the observed radiosensitization was that IR induced DNA damage and this induced a subsequent increase in RR activity to perform DNA repair.¹⁶ When this IR-induced increase in RR activity was shortly followed by the exposure to HU, which is an RR inhibitor, the IR-induced repairable DNA lesions were converted to irreparable DNA lesions with a significant increase in radiosensitization.¹⁶ Similar results were reported by Ward and associates, who found that HU treatment immediately after IR directly inhibited the IR-induced DNA repair in HeLa cancer cervix cell lines.¹⁷

Thus we report the first case of a patient with recurrent anaplastic meningioma to have a near complete/partial

Table 1 Summary of current studies on the efficacy of hydroxyurea in anaplastic (WHO grade III) meningioma

Study	Age, sex	No. of patients	NOS	Prior RT (mo pre-HU)	Prior ChemoRx (mo pre-HU)	Best response	Follow-up	Toxicity of grade 3 or higher
Schrell et al ⁸	56, M	1	6	Yes, RT (60)	No	SD	24 mo	No
Mason et al ⁹	57, F	1	3	Yes, RT + SRT (17)	No	PR	24 wk	No
Hahn et al ³	54–72, M and F	2	1, 2	Concurrent	N/A	SD, PR	4–34 mo	No
Reardon et al ¹⁰	Median 50; M 43%, F 57%	4	NA	33% (NA)	Yes (10% of patients)	SD	24 mo	Yes
Chamberlain ⁷	NS	13	NA	Yes, RT + SRT (> 3 mo)	No	SD	12 mo	Yes

Abbreviations: ChemoRx, chemotherapy; mo pre-HU, therapy completed x months before hydroxyurea administration; NA, not applicable; NOS, number of surgeries; NS, not specified; PR, progression; RT, radiotherapy; SD, stable disease.

radiologic regression after 5 months of 25 mg/kg of HU once daily, given within 1 month after stereotactic fractionated reirradiation. Although this is only a report of one patient, a plausible mechanism may be that HU sensitized the tumor to the previously administered ionizing radiation leading to tumor shrinkage and cavitation. Clearly, more research is needed to further explore this novel finding and further elucidate the potential of HU in treating anaplastic meningioma.

References

- 1 Modha A, Gutin PH. Diagnosis and treatment of atypical and anaplastic meningiomas: a review. *Neurosurgery* 2005;57(3): 538–550; discussion 538–550
- 2 Chamberlain MC. The role of chemotherapy and targeted therapy in the treatment of intracranial meningioma. *Curr Opin Oncol* 2012;24(6):666–671
- 3 Hahn BM, Schrell UM, Sauer R, Fahlbusch R, Ganslandt O, Grabenbauer GG. Prolonged oral hydroxyurea and concurrent 3D-conformal radiation in patients with progressive or recurrent meningioma: results of a pilot study. *J Neurooncol* 2005;74(2): 157–165
- 4 Newton HB. Hydroxyurea chemotherapy in the treatment of meningiomas. *Neurosurg Focus* 2007;23(4):E11
- 5 Brem SS, Bierman PJ, Brem H, et al; National Comprehensive Cancer Network. Central nervous system cancers. *J Natl Compr Canc Netw* 2011;9(4):352–400
- 6 Schrell UM, Rittig MG, Anders M, et al. Hydroxyurea for treatment of unresectable and recurrent meningiomas. I. Inhibition of primary human meningioma cells in culture and in meningioma transplants by induction of the apoptotic pathway. *J Neurosurg* 1997;86(5):845–852

- 7 Chamberlain MC. Hydroxyurea for recurrent surgery and radiation refractory high-grade meningioma. *J Neurooncol* 2012;107(2): 315–321
- 8 Schrell UM, Rittig MG, Anders M, et al. Hydroxyurea for treatment of unresectable and recurrent meningiomas. II. Decrease in the size of meningiomas in patients treated with hydroxyurea. *J Neurosurg* 1997;86(5):840–844
- 9 Mason WP, Gentili F, Macdonald DR, Hariharan S, Cruz CR, Abrey LE. Stabilization of disease progression by hydroxyurea in patients with recurrent or unresectable meningioma. *J Neurosurg* 2002; 97(2):341–346
- 10 Reardon DA, Norden AD, Desjardins A, et al. Phase II study of Gleevec® plus hydroxyurea (HU) in adults with progressive or recurrent meningioma. *J Neurooncol* 2012;106(2):409–415
- 11 Kubo O, Chernov M, Izawa M, et al. Malignant progression of benign brain tumors after gamma knife radiosurgery: is it really caused by irradiation? *Minim Invasive Neurosurg* 2005;48(6):334–339
- 12 Kunert P, Matyja E, Janowski M, Marchel A. Rapid growth of small, asymptomatic meningioma following radiosurgery. *Br J Neurosurg* 2009;23(2):206–208
- 13 Kuroda H, Kashimura H, Ogasawara K, et al. Malignant intracranial meningioma with spinal metastasis—case report. *Neurol Med Chir (Tokyo)* 2009;49(6):258–261
- 14 Malik I, Rowe JG, Walton L, Radatz MW, Kemeny AA. The use of stereotactic radiosurgery in the management of meningiomas. *Br J Neurosurg* 2005;19(1):13–20
- 15 Kuo ML, Kunugi KA, Lindstrom MJ, Kinsella TJ. The interaction of hydroxyurea and ionizing radiation in human cervical carcinoma cells. *Cancer J Sci Am* 1997;3(3):163–173
- 16 Kuo ML, Kinsella TJ. Expression of ribonucleotide reductase after ionizing radiation in human cervical carcinoma cells. *Cancer Res* 1998;58(10):2245–2252
- 17 Ward JF, Joner EI, Blakely WF. Effects of inhibitors of DNA strand break repair on HeLa cell radiosensitivity. *Cancer Res* 1984;44(1): 59–63