

A Case of Malignant Peripheral Nerve Sheath Tumor of the Hypoglossal Nerve after Stereotactic Radiosurgery Treatment

Tong Yang¹ Gordana Juric-Sekhar² Donald Born² Laligam N. Sekhar¹

¹Department of Neurosurgery, University of Washington, School of Medicine, Seattle, Washington, United States

²Department of Pathology, University of Washington, School of Medicine, Seattle, Washington, United States

Address for correspondence Laligam N. Sekhar, MD, Department of Neurosurgery, 325 Ninth Avenue, Box 359924, Seattle, WA, 98104-2499, United States (e-mail: lsekhar@u.washington.edu).

J Neurol Surg Rep 2014;75:e42–e46.

Abstract

Keywords

- ▶ malignant peripheral nerve sheath tumor
- ▶ nonvestibular schwannoma
- ▶ radiation associated malignancy
- ▶ stereotactic radiosurgery

Objectives Hypoglossal schwannomas are rare. Surgical resection has been the standard treatment modality. Radiosurgery has been increasingly used for treatment. Radiation-associated secondary malignancy/malignant transformation has not been documented in the literature for the treatment of nonvestibular schwannomas.

Setting The patient was a 52-year-old man with an enlarging high cervical/skull base lesion 8.5 years after CyberKnife treatment of a presumed vagal schwannoma. A decision was made for surgical resection, and the tumor was found to originate from the hypoglossal nerve intraoperatively. Final pathology diagnosis was malignant peripheral nerve sheath tumor.

Results Patient had a gross total resection. Three months after resection, he received fractionated radiation of 50 Gy in 25 fractions and a boost gamma knife radiosurgery of 10 Gy to the 50% isodose surface. He remained tumor free on repeat magnetic resonance imaging 9 months after the resection.

Conclusion Although extremely rare, radiation treatment of nonvestibular schwannomas can potentially cause malignant transformation.

Introduction

Schwannomas originate from the Schwann cells surrounding the peripheral nerves, including cranial nerves III to XII. More than 40% of nonsyndromic benign solitary schwannomas are located in the head and neck region.¹ The most frequently involved cranial nerve is the eighth nerve, and vestibular schwannomas account for 8% of intracranial tumors.² Nonvestibular schwannomas are rare and constitute < 0.5% of all intracranial tumors.³ Most of the skull base schwannomas arise from the sensory nerves; purely motor nerve-associated schwannomas are very rare and often associated with von Recklinghausen disease (neurofibromatosis [NF]1).⁴

Surgical resection has been considered the standard treatment for the management of nonvestibular schwannomas.^{2,5}

Similar to the evolution of treatment modalities for vestibular schwannomas, radiosurgery has become an alternative treatment modality in recent years for the management of nonvestibular schwannomas.^{3,6–8} Radiation-associated secondary malignancy or malignant transformation for the treatment of vestibular schwannomas is a rare but potentially deadly phenomenon.^{9,10}

Case Report

Clinical Presentation

The patient was a 52-year-old man who underwent right suboccipital craniectomy for resection of a vestibular schwannoma in 1992 at an outside hospital (20 years prior to current presentation). He was also found to have a T1-enhancing

received
August 10, 2013
accepted
September 8, 2013
published online
May 2, 2014

DOI <http://dx.doi.org/10.1055/s-0033-1358797>.
ISSN 2193-6358.

© 2014 Georg Thieme Verlag KG
Stuttgart · New York

License terms



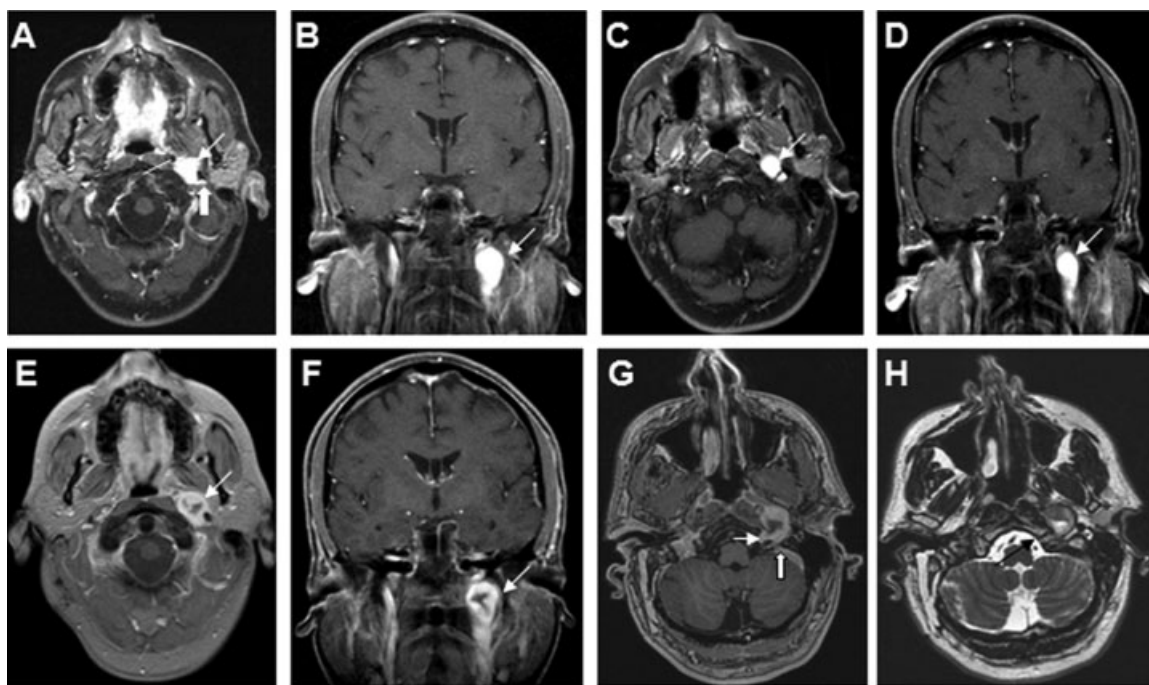


Fig. 1 Magnetic resonance imaging scans of the patient, 4 months (2004) after CyberKnife treatment. (A) T1-weighted postcontrast axial view showing a left cervical/skull base lesion (thin arrow) located between the external carotid artery (line) and the internal carotid artery (thick arrow). (B) T1-weighted postcontrast coronal view showing the tumor (arrow) 5.5 years (2009) after CyberKnife treatment. (C) T1-weighted postcontrast axial view showing the lesion (arrow) with a slight decrease in size. (D) T1-weighted postcontrast coronal view showing the lesion 8.5 years (2012) after CyberKnife treatment. (E) T1-weighted postcontrast axial view showing the lesion (arrow) with increased size and hypointensity in the center, consistent with necrosis. (F) T1-weighted postcontrast coronal view showing the lesion (arrow). (G) Fine-cut T1-weighted postcontrast axial view showing the lesion with a tail extending through the hypoglossal canal (thin arrow) and abutting the jugular foramen (thick arrow). (H) Fine-cut T2-weighted axial view again showing the lesion with a tail extending through the hypoglossal canal (arrow).

mass in the left high cervical/skull base area located in between the external and internal carotid arteries. It was assumed to be a vagal schwannoma. The patient had a complete loss of hearing and transient facial weakness on the right after the surgery in 1992.

He had not had regular follow-up for the left lesion since 1992. In 2003, he presented with choking and difficulty with swallowing. His symptoms were attributed to the lesion on the left, measured at $1.8 \times 1.6 \times 1.9$ cm on magnetic resonance imaging (MRI). He was found to have left vocal cord paralysis. He underwent CyberKnife radiosurgery of the left high cervical/skull base lesion at an outside hospital in November 2003 without a biopsy. The targeted volume was 5.7 cm^3 with minimum doses of 13 Gy and maximum doses of 15 Gy targeted to the tumor. A dose of 13.6 Gy was conformed to the 85% isodose line. The patient was subsequently followed with serial MRI scans, and there was radiographic evidence of slight tumor shrinkage up to 2009 (dimension $1.5 \times 1.6 \times 1.7$ cm). His symptoms improved but with residual hoarseness of his voice. The left lesion was considered as treated with the CyberKnife because no growth of the lesion was noted for 6 years. He had no further follow-up until 9 weeks prior to the current presentation (June 2012) when he presented with increasing hoarseness, coughing, nausea, and headaches. Repeat imaging showed enlargement of his left neck/skull base lesion with decreased central contrast enhancement (dimension $3.9 \times 2.1 \times 2.0$ cm). Computed

tomography (CT) of the chest did not show evidence of metastasis. He was referred to the senior author (LNS) for a second opinion and management (**Fig. 1**).

Physical examination at the time of current presentation showed a right hearing loss; other cranial nerve functions were intact with no focal neurologic findings. He had one brown spot on the skin of his back. He also had several subcutaneous fibromas. Reportedly, several of his relatives also have subcutaneous fibromas. However, there is no definitive family history of NF. The patient had not had any testing to prove a diagnosis of NF.

Surgical Treatment

The patient underwent left upper cervical and preauricular transfacial exposure in conjunction with an otolaryngology surgeon. The tumor was completely resected using microsurgical techniques and under the guidance of neuronavigation. Intraoperatively, the tumor was found to originate from the hypoglossal nerve inferiorly and extending superiorly to the jugular foramen. The tumor was encapsulated, with whitish color and very firm consistency. The splayed nerve fascicles of the hypoglossal nerve showed only a very weak response to intraoperative direct stimulation of 1 ampere. After the tumor was removed in a gross-total fashion, no signal was detected on direct stimulation of the hypoglossal nerve. Good stimulation of the spinal accessory nerve was present. Postoperative imaging was consistent with gross-total resection (**Fig. 2**).

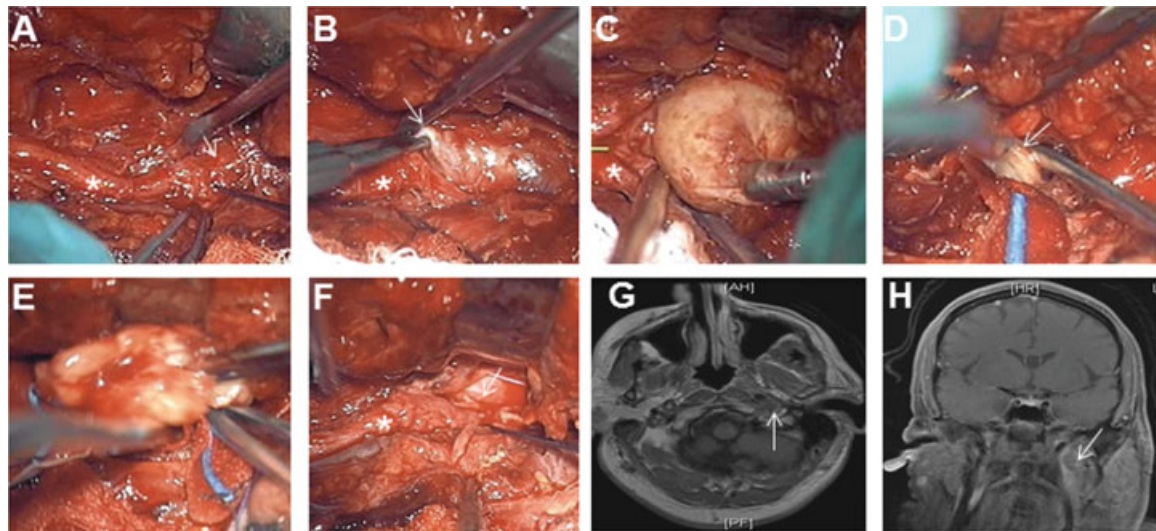


Fig. 2 Intraoperative microscopic views of the tumor resection. (A) The inferior border of the tumor (arrow) is in continuity with the hypoglossal nerve (asterisk). (B) The inferior border of the tumor (arrow) is being dissected away from the hypoglossal nerve (asterisk). (C) The whitish firm tumor is being lifted from the hypoglossal nerve (asterisk). (D) The superior border of the tumor (arrow) is being dissected away from the area of the jugular foramen. (E) The tumor is being removed in total from the resection cavity. (F) The intraoperative view after the removal of the tumor showing the hypoglossal nerve (asterisk) and the resection cavity from which the tumor was removed (arrow). (G) Postoperative magnetic resonance imaging scan T1-weighted postcontrast axial view showing the cavity from which the previously enhancing lesion was removed (arrow). (H) Coronal view again showing the removal of the lesion (arrow).

Pathologic Examination

Hematoxylin and eosin–stained sections of the tumor specimen showed pleomorphic spindle cell neoplastic proliferation with atypical nuclei arranged in intersecting fascicles and

separated by varying amounts of collagenous stroma (→**Fig. 3A, B**). Dense connective tissue was attached to the tumor containing invested myelinated nerves and scattered inflammatory cells. Occasional bizarre multinucleated

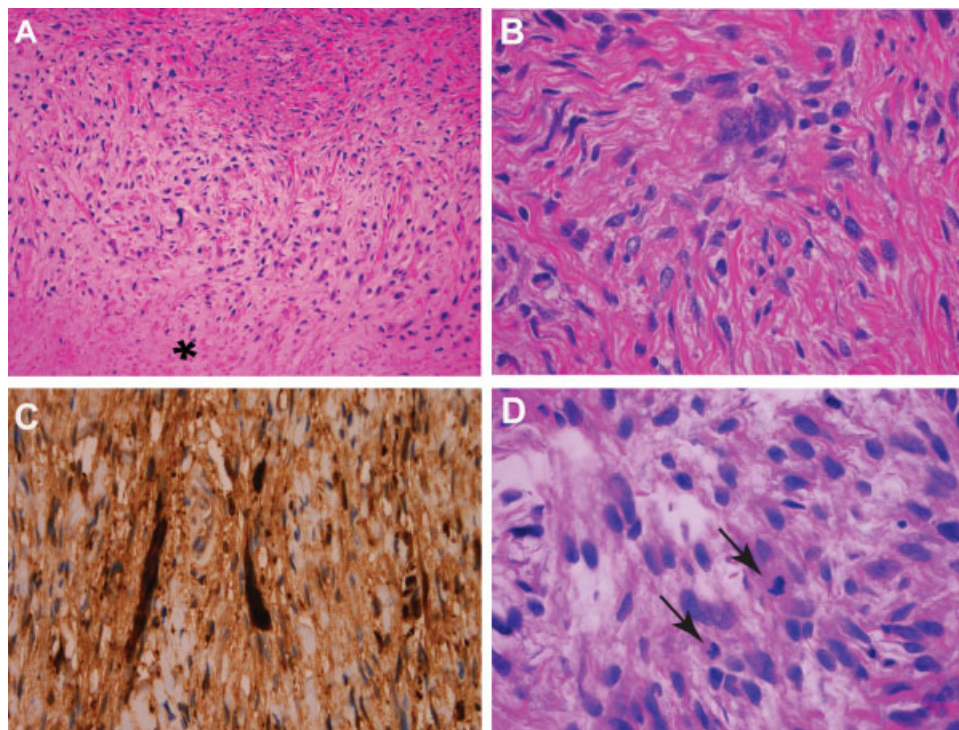


Fig. 3 Histopathologic analysis of the tumor. (A, B) Microphotograph of the hematoxylin and eosin (H&E)-stained resected tumor tissue exhibits neoplastic spindle cells with marked pleomorphism and fasciculated architecture of alternating cellularity. Necrosis is also present (asterisk in A); (C) Immunohistochemical stain for S-100 shows strong positive staining in the neoplastic cells. (D) H&E-stained tissue shows increased mitotic activity (arrows). Magnifications: (A) $\times 200$; (B–D) $\times 400$.

neoplastic cells, multiple mitoses (5/10 high-power fields), and extensive central necrosis were present (→ Fig. 3A, B, D). Immunohistochemical study of the neoplasm showed diffuse immunopositivity for S-100 protein (→ Fig. 3C) and p53 upregulation in < 25% of the neoplastic cells. There was no cytokeratin 7, HMB45, Melan-A, or microphthalmia transcription factor (markers for melanocyte differentiation) expression. The final diagnosis was malignant peripheral nerve sheath tumor (MPNST). The case was also sent to an expert pathologist in another institution for review, and he concurred with our pathologic diagnosis.

Hospital Course

Immediately after surgery, the patient displayed transient mild tongue deviation, but his tongue returned to midline position on protrusion 24 hours after surgery. His left vocal cord remained paralyzed but with a paramedian position. He was able to tolerate a dysphagic diet without evidence of aspiration.

He was referred to a soft tissue oncologist as well as a radiation oncologist for further management. He was also referred to a medical geneticist for screening for NF gene mutations.

Adjuvant Therapy

About 3 months after his surgery, the patient received 25 fractions of daily conventional radiation to his neck around the surgical site for a total of 50 Gy. He also underwent one session of boost gamma knife radiosurgery of 10 Gy to the 50% isodose line.

Follow-up

The patient remained at his neurologic baseline 9 months after his resection. A repeat MRI showed no evidence of tumor recurrence.

Based on his clinical history, family history, and his physical examination, our medical geneticist deemed the patient not meeting the diagnostic criteria for either NF1 or 2, or for schwannomatosis. He was considered potentially to be a mosaic for NF2 mutation, and sequencing his tumor tissue could be potentially informative. The patient declined the sequencing offer.

Discussion

Nonvestibular schwannomas are rare, and schwannomas originating from pure motor cranial nerve such as the hypoglossal nerve are even more scarce.^{3,4,11} Traditionally, surgical resection using microsurgical techniques and modern skull base approaches has been the standard treatment modality. Only a few current case series with more than three cases of hypoglossal schwannomas exist in the literature,¹²⁻¹⁴ and the authors report 50 to 100% gross-total resection rate, no disability to 33.3% of new cranial nerve deficits, and 8.3% tumor recurrence (1 of 12) to 100% tumor control with the longest reported follow-up period of 14 years. There is no case of a MPNST tumor of the hypoglossal nerve reported in the surgical series just cited.

Radiosurgery has been increasingly used in the treatment of nonvestibular schwannomas, either as an adjuvant therapy, a salvage therapy at time of recurrence after surgical treatment, or as the primary treatment after a diagnosis based on radiographic features.^{3,6-8,15-18} Cumulative experiences have shown that radiosurgery can be an effective and safe alternative to treat nonvestibular schwannomas, especially for relatively small tumors without a significant mass effect on the brainstem. The longest reported follow-up period is 210 months (no stratified data on hypoglossal schwannomas alone)⁸ among the series on radiosurgery, and no case of secondary malignancy or malignant transformation has been reported, although a theoretical risk of 0.005 to 0.1% was mentioned.¹⁵

MPNST of the head and neck is reported in 8% of all the cases of a published cohort of MPNST.¹⁹ It is estimated that half of MPNSTs are associated with NF1.²⁰ Singh and Shaha²¹ reported a case of cervical malignant nerve sheath tumor of the hypoglossal nerve in a patient without known NF and identified three other cases in the literature. Their review of the literature involving malignant nerve sheath tumors of the cranial nerves showed that the association to NF1 is less compared with those MPNST tumors located elsewhere. The significance of this finding is unclear. Scheithauer et al²² reported the largest series of cranial nerve MPNSTs (no case of hypoglossal-derived tumor). Of the cases not associated with NF1 or 2, one patient had radiation for Hodgkin disease, one for pilocytic astrocytoma, and both patients were exposed to the radiation > 20 years prior. Two patients had spontaneous malignant transformation (vestibular schwannoma) over a rather short period (< 1 year) without known prior radiation exposure. One patient had a low-grade MPNST and had radiation 13 years and 15 years after the initial presentation.

Our patient does not meet the diagnostic criteria for NF1 or 2. The patient received radiosurgery to his left neck lesion without a prior surgical biopsy for pathologic diagnosis. Although we do not know whether there was any malignant feature in his original tumor, the fact that the lesion did not grow significantly 11 years after the original discovery prior to the radiosurgical treatment, and until 8.5 years after the CyberKnife treatment argues against a very aggressive lesion prior to the radiation treatment.

Radiation-associated secondary malignancies or malignant transformations after the treatment of vestibular schwannomas are very rare but well documented in the literature.^{9,10,23} We cannot compare the current tumor pathology with the original lesion prior to radiation due to no biopsy. Other characteristics of this case including history of radiation, tumor progression within the radiation field, and a latency of 8.5 years from the time of radiation highly suggest a potential malignant transformation associated with the radiation treatment for a nonvestibular schwannoma. Although we cannot completely rule out the possibility of a spontaneous malignant degeneration, the likelihood is very low, especially in a non-NF background. We expect that as the number of cases of nonvestibular schwannomas treated with radiation continues to grow, we may see more reports of

secondary malignancy or malignant transformation cases, even though they are very rare occurrences overall.

Conclusions

MPNST may occur after radiation treatment of hypoglossal schwannoma.

Acknowledgment

We would like to thank Dr. Arie Perry at the University of California, San Francisco, for kindly agreeing to review our pathology specimen.

Financial Disclosure

The authors have no conflicts of interest to disclose.

References

- Das Gupta TK, Brasfield RD, Strong EW, Hajdu SI. Benign solitary Schwannomas (neurilemmomas). *Cancer* 1969;24(2):355–366
- Moukarbel RV, Sabri AN. Current management of head and neck schwannomas. *Curr Opin Otolaryngol Head Neck Surg* 2005;13(2):117–122
- Pollock BE, Foote RL, Stafford SL. Stereotactic radiosurgery: the preferred management for patients with nonvestibular schwannomas? *Int J Radiat Oncol Biol Phys* 2002;52(4):1002–1007
- Berger MS, Edwards MS, Bingham WG. Hypoglossal neurilemmoma: case report and review of the literature. *Neurosurgery* 1982;10(5):617–620
- Malone JP, Lee W-J, Levin RJ. Clinical characteristics and treatment outcome for nonvestibular schwannomas of the head and neck. *Am J Otolaryngol* 2005;26(2):108–112
- Choi CYH, Soltys SG, Gibbs IC, et al. Stereotactic radiosurgery of cranial nonvestibular schwannomas: results of single- and multi-session radiosurgery. *Neurosurgery* 2011;68(5):1200–1208; discussion 1208
- Elsharkawy M, Xu Z, Schlesinger D, Sheehan JP. Gamma Knife surgery for nonvestibular schwannomas: radiological and clinical outcomes. *J Neurosurg* 2012;116(1):66–72
- Kimball MM, Foote KD, Bova FJ, Chi Y-Y, Friedman WA. Linear accelerator radiosurgery for nonvestibular schwannomas. *Neurosurgery* 2011;68(4):974–984; discussion 984
- Yang T, Rockhill J, Born DE, Sekhar LN. A case of high-grade undifferentiated sarcoma after surgical resection and stereotactic radiosurgery of a vestibular schwannoma. *Skull Base* 2010;20(3):179–183
- Puataweepong P, Janwityanujit T, Larbcharoensub N, Dhanachai M. Radiation-induced peripheral malignant nerve sheath tumor arising from vestibular schwannoma after Linac-based stereotactic radiation therapy: a case report and review of literature. *Case Rep Med* 2012;2012:648191
- Odake G. Intracranial hypoglossal neurinoma with extracranial extension: review and case report. *Neurosurgery* 1989;24(4):583–587
- Cavalcanti DD, Martirosyan NL, Verma K, et al. Surgical management and outcome of schwannomas in the craniocervical region. *J Neurosurg* 2011;114(5):1257–1267
- Nonaka Y, Grossi PM, Bulsara KR, Taniguchi RM, Friedman AH, Fukushima T. Microsurgical management of hypoglossal schwannomas over 3 decades: a modified grading scale to guide surgical approach. *Neurosurgery* 2011;69(2, Suppl Operative):ons121–ons140; discussion ons140
- Sarma S, Sekhar LN, Schessel DA. Nonvestibular schwannomas of the brain: a 7-year experience. *Neurosurgery* 2002;50(3):437–448; discussion 438–439
- Kano H, Niranjana A, Kondziolka D, Flickinger JC, Dade Lunsford L. Stereotactic radiosurgery for trigeminal schwannoma: tumor control and functional preservation. *Clinical article. J Neurosurg* 2009;110(3):553–558
- Martin JJ, Kondziolka D, Flickinger JC, Mathieu D, Niranjana A, Lunsford LD. Cranial nerve preservation and outcomes after stereotactic radiosurgery for jugular foramen schwannomas. *Neurosurgery* 2007;61(1):76–81; discussion 81
- Pan L, Wang EM, Zhang N, et al. Long-term results of Leksell gamma knife surgery for trigeminal schwannomas. *J Neurosurg* 2005;102(Suppl):220–224
- Safavi-Abbasi S, Bambakidis NC, Zabramski JM, et al. Nonvestibular schwannomas: an evaluation of functional outcome after radiosurgical and microsurgical management. *Acta Neurochir (Wien)* 2010;152(1):35–46
- Das Gupta TK, Brasfield RD. Solitary malignant schwannoma. *Ann Surg* 1970;171(3):419–428
- Mrugala MM, Batchelor TT, Plotkin SR. Peripheral and cranial nerve sheath tumors. *Curr Opin Neurol* 2005;18(5):604–610
- Singh B, Shaha AR. Solitary malignant schwannoma invading the hypoglossal nerve. *Ear Nose Throat J* 1994;73(11):842–844, 847–849
- Scheithauer BW, Erdogan S, Rodriguez FJ, et al. Malignant peripheral nerve sheath tumors of cranial nerves and intracranial contents: a clinicopathologic study of 17 cases. *Am J Surg Pathol* 2009;33(3):325–338
- Shin M, Ueki K, Kurita H, Kirino T. Malignant transformation of a vestibular schwannoma after gamma knife radiosurgery. *Lancet* 2002;360(9329):309–310