

# Early Endoscopic Dilation and Mitomycin Application in the Treatment of Acquired Tracheal Stenosis

Ruben Ortiz<sup>1</sup> Eva Dominguez<sup>1</sup> Carlos De La Torre<sup>1</sup> Francisco Hernandez<sup>1</sup> Jose Luis Encinas<sup>1</sup>  
Sergio Lopez-Fernandez<sup>1</sup> Luis Castro<sup>2</sup> Juan Jose Menendez<sup>3</sup> Olga De la Serna<sup>4</sup> Juan Vazquez<sup>1</sup>  
Manuel Lopez Santamaria<sup>1</sup> Juan Antonio Tovar<sup>1</sup>

<sup>1</sup> Department of Pediatric Surgery, Hospital Universitario La Paz, Madrid, Spain

<sup>2</sup> Division of Pediatric Anesthesia and Resuscitation, Hospital Universitario La Paz, Madrid, Spain

<sup>3</sup> Division of Pediatric Intensive Care, Hospital Universitario La Paz, Madrid, Spain

<sup>4</sup> Division of Pediatric Pulmonology, Hospital Universitario La Paz, Madrid, Spain

**Address for correspondence** Ruben Ortiz, Department of Pediatric Surgery, Hospital Universitario La Paz, Paseo de la Castellana 261, Madrid 28046, Spain (e-mail: rubenortizrodriguez@hotmail.com).

Eur J Pediatr Surg 2014;24:39–45.

## Abstract

**Introduction** Acquired airway stenosis is a common complication in children after periods of tracheal intubation. We reviewed our experience in the endoscopic treatment of these lesions.

**Patients and Methods** We performed a retrospective review of patients who presented acquired tracheal-subglottic stenosis (SGS) treated at our center from 2005 to 2012. We reviewed the etiology, age, clinical presentation, methods of diagnosis, number of bronchoscopies, angioplasty balloon dilations performed, and long-term results.

**Results** A total of 18 patients (13 M, 5 F) were treated at our institution between 2005 and 2012. Median age at treatment was 3.5 months (range, 1–96 months). Of the 18 children, 16 children had SGS (all cases were postintubation), and 2 children presented tracheal stenosis (1 postintubation, 1 after tracheal surgery). Median intubation time was 30 days (range, 3–120 days). Extubation failure and stridor were the main clinical features. SGS were diagnosed as grade I in three patients, grade II in nine patients, and grade III in six patients. Bronchoscopy allowed diagnostic in all cases, and was followed by angioplasty balloon dilation, with a median of 2.5 (range, 1–5) sessions. In SGS grade I, the relation patient/number of dilations was 1; in SGS grade II 2.6, and in SGS grade III 3.5. Mitomycin was applied in 15 patients. No patients presented intraoperative complications or required reoperation. Median follow-up time was 36 months (range, 5–72 months) and no recurrence was noticed.

**Conclusions** Early endoscopic dilation with balloon shows as an effective and safe treatment in acquired tracheal and SGS.

## Keywords

- ▶ subglottic stenosis
- ▶ balloon dilation
- ▶ endoscopic
- ▶ laryngotracheal reconstruction
- ▶ pediatric

received  
May 15, 2013  
accepted after revision  
August 28, 2013  
published online  
January 17, 2014

© 2014 Georg Thieme Verlag KG  
Stuttgart · New York

DOI <http://dx.doi.org/10.1055/s-0033-1357754>.  
ISSN 0939-7248.

## Introduction

Subglottic and tracheal stenoses represent one of the main causes of chronic obstruction of the airway in children. The important development of neonatology and mechanical ventilation techniques in the last decades have achieved better survival rates of preterm infants by variable tracheal intubation periods. Widespread use of these procedures, converted acquired subglottic and tracheal stenoses in the most common disorder of the upper airway in children, and in the most frequent indication for tracheostomy during the first year of life.

Open surgery has been the traditional management of subglottic stenosis (SGS) including different approaches such as cricoid division, laryngotracheal reconstruction (LTR), and cricotracheal resection (CTR) with anastomosis, with good results in 80 to 90%. For this reason, these approaches still remain the first option of treatment.<sup>1</sup> However, they have important disadvantages as the frequent need for several interventions, with periods of protracted endotracheal intubation in critical care units, and the risks associated with tracheostomy.<sup>2,3</sup>

Significant improvements in airway endoscopy in the last years allowed the development of new endoscopic techniques for the treatment of subglottic and tracheal stenoses. Hebra et al<sup>4</sup> published the first experience with tracheal angioplasty balloon dilation in children. Recently, satisfactory results have been reported in the treatment of acquired SGS with balloon dilation,<sup>5,6</sup> including stenoses appearing after LTR surgery, avoiding reoperations and permanent tracheostomy.<sup>6-9</sup>

Nevertheless, management and surgical treatment of subglottic and tracheal stenoses in children remains unclear because there is still no agreement on the indications.

The aim of this study is to report our experience in the early endoscopic treatment of acquired subglottic and acquired tracheal stenoses with angioplasty balloon dilation and topical mitomycin application.

## Patients and Methods

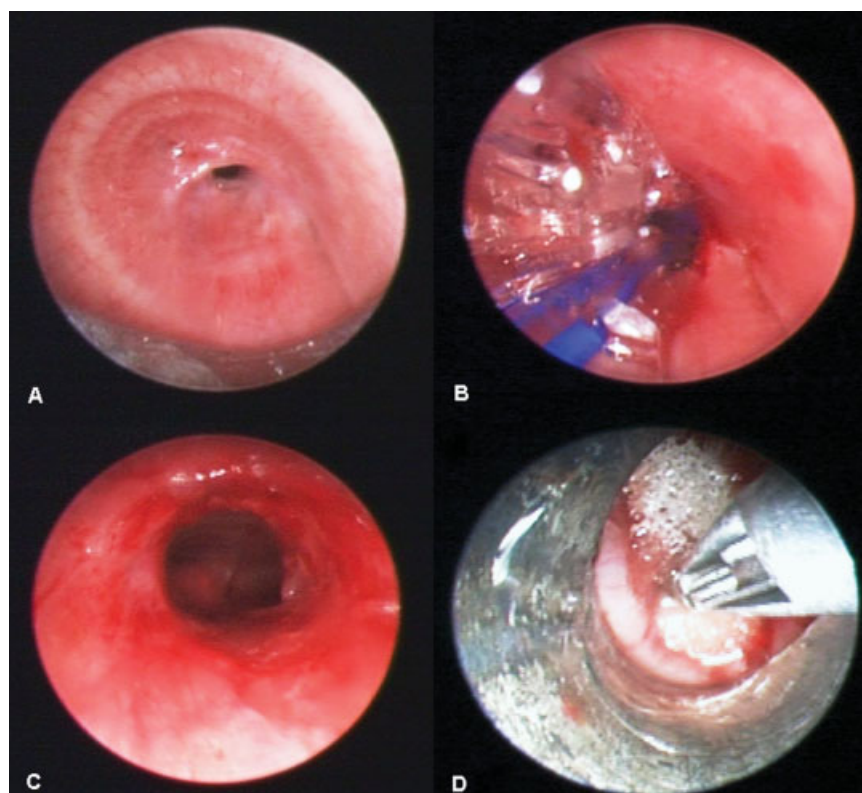
Patients with acquired tracheal-subglottic stenoses treated at our center from 2005 to 2012 were retrospectively reviewed. Both postintubation and postlaryngotracheal surgery stenoses were included. Congenital SGS were excluded. All patients were diagnosed by bronchoscopy.

We reviewed the etiology, age, clinical presentation, methods of diagnosis, number of bronchoscopies and angioplasty balloon dilations performed, and long-term results.

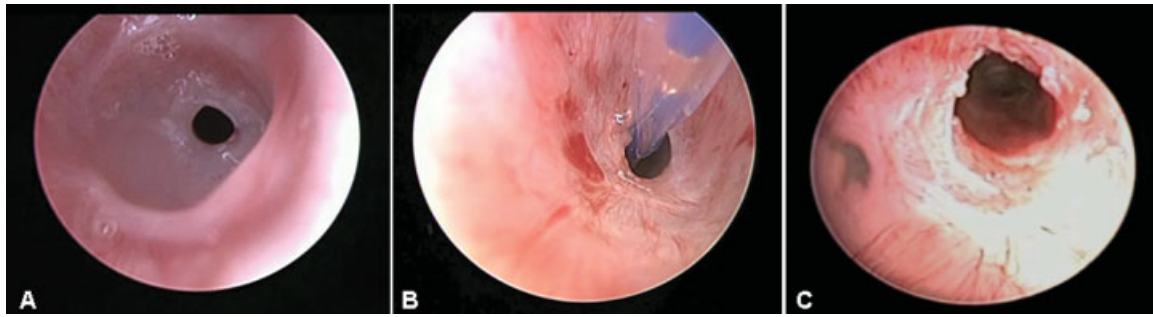
## Procedure

The patient was placed in the operating room under general anesthesia, maintaining spontaneous ventilation and nasopharyngeal ventilatory assistance with age-sized nasopharyngeal tube.

With the patient in cervical hyperextension helped by a roller positioned under the shoulders, indirect laryngoscopy was performed with instillation of 1% nebulized lidocaine in vocal cords and supraglottic area (1–2 mL depending on patient's weight). After that, direct laryngoscopy was done



**Fig. 1** (A) Subglottic stenosis grade III diagnosed with rigid bronchoscopy. (B) Endoscopic balloon dilation using angioplasty balloon catheter at the time of diagnosis. (C) Subglottic dilated area. (D) Topical application of pledgets soaked with mitomycin (1 mg/mL) in the dilated area.



**Fig. 2** (A) Subglottic stenosis grade II at diagnosis. (B) Endoscopic balloon dilation. (C) Dilated area after two episodes of balloon dilation.

using a 3-mm and 0 degree rigid endoscope (Karl Storz 10324AA, Tuttlingen, Germany) to establish the level and severity of stenosis attending to the Myer-Cotton scale<sup>10</sup>:

- Grade I: obstruction of 0 to 50%.
- Grade II: obstruction of 51 to 70%.
- Grade III: obstruction of 71 to 99%.
- Grade IV: punctiform obstruction without detectable light.

At the time of diagnosis, balloon dilation was performed using angioplasty balloon catheters 4 to 8 mm in diameter and 20 mm in length (EverCross USA [EV3 Inc., Plymouth, Minnesota, United States], dilatation catheter), depending on the theoretical diameter for child's age.

Under direct vision with the rigid scope, the angioplasty balloon was introduced into the stenotic area and filled with saline by an inflation/deflation hand pump connected to a pressure gauge that monitored pressure within the balloon. This dilation procedure was maintained for 1 minute, being interrupted if the patient's oxygen saturation dropped below 90% or in case of deterioration of vital signs. Two or three dilations were performed in the same session changing to a larger diameter balloon if necessary. The dilations were followed by topical application of mitomycin solution (1 mg/mL) in the dilated area for 1 minute. This local application was performed under direct endoscopic vision, with a cotton pledget grabbed by a forceps through the rigid bronchoscope (→ Figs. 1 and 2).

Once the procedure was completed, the patient remained during the first 24 hours in the postanesthetic care unit, and was intubated only if necessary. An intravenous bolus of

methylprednisolone (1 mg/kg) was administrated at the time of the procedure and repeated 8 hours later, followed by oral tapering doses during the first week, and aerosol inhaled Budesonide (200 µg, 2 times daily) until the first postoperative check 2 weeks later.

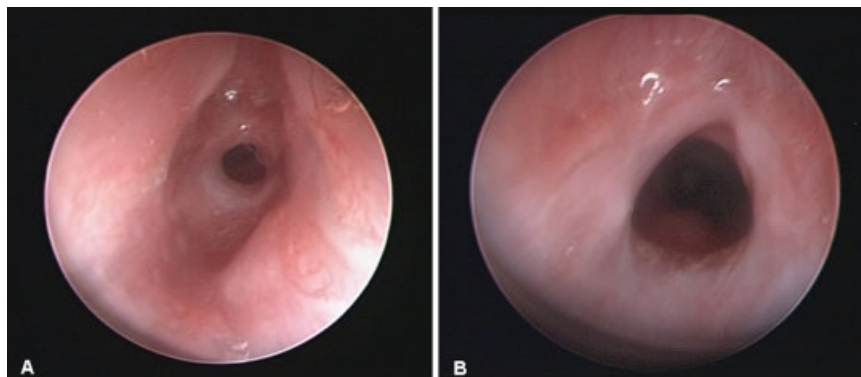
Revisions were done in the operating room and in the same manner as outlined above. Except in cases with clinical deterioration, the first one was done routinely 10 to 15 days after the initial dilation. If more dilations were not needed, another endoscopic check was done 1 month later, and 3 months after the last one. After that, the patient was followed-up every 6 months in the outpatient clinic (→ Fig. 3).

The procedure described above was performed in the operating room whenever the patient's condition allowed it. If the patient was hemodynamically unstable or had noticeable respiratory distress, the procedure was performed in the pediatric intensive care unit using the flexible fiber optic bronchoscope.

Mitomycin was used whenever it was available because the dilution should be previously prepared by the cytostatic unit; therefore, it could not be applied in all cases, especially in emergency procedures. In addition, mitomycin was only used in the first dilation session.

## Results

We treated 18 patients (13 male, 5 female) for acquired subglottic or tracheal stenoses between the years 2005 and



**Fig. 3** (A) Subglottic stenosis (SGS) grade II at diagnosis. (B) Same patient at first revision 2 weeks later showing asymptomatic SGS grade I.

2012. Median age at treatment was 3.5 months (range, 1–96). A total of 16 children had SGS (all of them after intubation periods), and 2 children presented tracheal stenosis (1 post-intubation, and the other one after reconstructive tracheal surgery because of a long congenital tracheal stenosis). Median intubation time before diagnosis was 30 days (range, 3–120 days), and the causes for intubation were: respiratory distress in 10 cases, cardiac surgery in 5 cases, neonatal abdominal surgery in 1 cases, and polytrauma after traffic accident in 1 cases (►Table 1).

The main clinical features were stridor with respiratory distress after a variable period of intubation, and failure to extubate. Upon bronchoscopy, performed early as soon as the symptoms appeared, SGS were grade I in three patients, grade II in nine patients, and grade III in six patients. Bronchoscopy was followed by angioplasty balloon dilation, with a median of 2.5 sessions (range, 1–5 sessions). The median of procedures in each group were: 1 in SGS grade I, 2 (range, 2–5) in SGS grade II, and 4 (range, 1–5) in SGS grade III; with a relation patient/number of dilations of 1 in SGS grade I; 2.6 in SGS grade II and 3.5 in SGS grade III.

Mitomycin was applied during the first dilation session in 15 of 18 patients. All patients were treated successfully with this procedure and no one presented intraoperative complications or required open surgery. The patient with the posttracheal surgery stenosis did not need reoperation. Median follow-up time was 36 months (range, 5–72 months) and no recurrences or side effects have been noticed.

## Discussion

Congenital and acquired subglottic and tracheal stenoses remain a challenge for pediatric surgeons because there is no consensus on their management and surgical treatment. In our hands, early and vigorous dilation of acquired SGS was effective and safe, and the number of sessions was proportional to the grade of stenosis. The success of this procedure was less dramatic in patients with long-standing SGS or tracheostomy because of intense fibrosis. Before the angioplasty balloon dilation was introduced or in a few occasions when they were not available, dilation was performed with rigid bronchoscopes or with the endotracheal tube itself, but the results were definitely worse with poor control over the dilated area. In congenital stenosis, we avoid dilatation because of the risk of tracheal wall rupture and we prefer open surgery procedures, such as LTR with costal cartilage grafting, CTR, or slide tracheoplasty in longer stenoses.

Several surgical procedures have been used for the treatment of subglottic and tracheal stenosis. In the late 1980s, the gold standard was the reconstructive surgery (LTR), including cricoid division with subsequent reconstruction using autograft cartilage and endotracheal stents.<sup>11</sup> The laryngotracheoplasty in a single surgical procedure was introduced in the late 1990s, replacing postoperative tracheostomy for endotracheal intubation, with a success rate approaching 80%.<sup>1</sup> At the same time, Monnier et al introduced the partial CTR for severe SGS and anastomosis with successful results.<sup>12</sup>

In the past years, important advances of minimally invasive airway endoscopic surgery have been developed, particularly, laser resection and laryngotracheal dilation. These less risky procedures achieved shorter periods of intubation and reduced postoperative stay.<sup>13,14</sup> Endoscopic laryngotracheal dilation could be done both with rigid dilators and with inflatable balloons. A descriptive study of 64 patients with acquired SGS grade I–III dilated early and repeatedly with Chevalier–Jackson rigid dilators, had a 100% success. Patients with more severe grades of stenosis required more sessions.<sup>15</sup>

Despite the demonstrated efficacy of balloon dilation in angioplasty and in esophageal stenosis, there is reluctance for using it in the infant airway being the main argument the absence of clinical trials or prospective studies comparing open surgery with endoscopic dilations.<sup>7</sup> The pneumatic balloon dilations hypothetically offer several advantages over rigid ones, such as exerting radial force instead of longitudinal shearing wall forces, and the ability to control the diameter and the pressure of the balloon, that is able to limit the trauma on the tracheal wall.<sup>4,16</sup>

Recent studies reported satisfactory outcomes in the endoscopic balloon laryngotracheoplasty of acquired and congenital SGS.<sup>5–8</sup> Hautefort et al<sup>6</sup> published good results using balloon dilation in the treatment of 44 patients with acquired SGS, congenital SGS and posttracheal surgery stenoses, showing a successful treatment in 70% of acquired SGS, 50% in congenital SGS, and 81% in stenosis after open laryngotracheal surgery. Authors concluded that tracheal balloon dilation has become for them the first therapeutic option in the acquired SGS of all grades, stenosis secondary to prior reconstructive surgery and in selected cases of congenital SGS, reducing the need for open approach in 70 to 80% of the cases. Whigham et al<sup>8</sup> established that balloon dilation plays an important role in the management of pediatric SGS, being concomitant airway lesions associated with treatment failure. Mirabile et al<sup>16</sup> recently communicated their favorable experience with 83% of success in both acquired and congenital SGS with endoscopic anterior cricoid split and balloon dilation, suggesting a better outcome in congenital SGS with the anterior cricoid division.

Other groups have also reported satisfactory results in the endoscopic management of the SGS using various techniques (balloon dilation, rigid dilation, and laser resection), as well as different adjuvant topical treatments with mitomycin, steroids, and/or antibiotics; therefore, results cannot be attributed to any particular technique.<sup>9,14</sup>

On contrary, open techniques (LTR and CTR) continue to be widely used in both acquired and congenital subglottic-tracheal stenosis with good results, but with a significant percentage of reoperations and decannulation failures. White et al<sup>2</sup> presented 94% successful decannulation rate in 93 patients who undergone CTR, but an operation-specific success rate of 71% (27 patients required additional open airway procedures for decannulation after CTR). The group of Great Ormond Street Hospital in London, United Kingdom, recently published their experience with LTR and CTR in 199 patients from 2000 to 2010, showing 88% improvement in patient's symptoms, but 16.5% children who underwent single-stage

**Table 1** Clinical data and results

Patient n°	Age (mo)	SGS/TS	Etiology	Intubation time	Grade	N° dilations	Mitomycin	Success	Follow-up (mo)
1	1	SGS	Postintubation. Neonatal abdominal surgery	3 d	III	3	Yes	Yes	32
2	3	SGS	Postintubation. Respiratory distress	2 mo	I	1	Yes	Yes	50
3	5	SGS	Postintubation. Cardiac surgery	1 mo	II	3	Yes	Yes	48
4	2	SGS	Postintubation. Respiratory distress	2 mo	II	2	Yes	Yes	18
5	4	SGS	Postintubation. Respiratory distress	3 mo	III	4	Yes	Yes	36
6	6	SGS	Postintubation. Cardiac transplant	25 d	II	2	Yes	Yes	44
7	4	SGS	Postintubation. Respiratory distress	3 mo	III	4	Yes	Yes	24
8	6	SGS	Postintubation. Cardiac surgery	13 d	I	1	No	Yes	72
9	4	SGS	Postintubation. Respiratory distress	4 mo	II	3	Yes	Yes	52
10	3	SGS	Postintubation. Respiratory distress	3 mo	II	3	Yes	Yes	66
11	2	SGS	Postintubation. Respiratory distress	1 mo	III	5	Yes	Yes	48
12	9	SGS	Postintubation. Cardiac surgery	20 d	I	1	Yes	No	44
13	3	SGS	Postintubation. Respiratory distress	3 mo	II	2	Yes	Yes	32
14	1	TS	Post laringotracheoplasty in congenital TS	1 mo	II	5	Yes	Yes	30
15	96	TS	Postintubation and tracheostomy after traffic accident.	1 mo	III	1	Yes	Yes	36
16	1	SGS	Postintubation. Respiratory distress	5 d	III	4	Yes	Yes	15
17	13	SGS	Postintubation. Cardiac surgery, CHARGE.	11 d	II	2	No	Yes	7
18	3	SGS	Postintubation. Respiratory distress	13 d	II	2	No	Yes	5

Abbreviations: N° dilations, number of dilations; Patient n°: patient number; SGS, subglottic stenosis; TS, tracheal stenosis.



procedures had a tracheostomy reinserted. Furthermore, two-stage LTR/CTR procedures were performed in 57.7% of the patients with prolonged stenting periods.<sup>17</sup> Therefore, even if they are effective techniques, the risk of reintervention or decannulate failure make endoscopic procedures more attractive and increasingly used.

Mitomycin-C is an antibiotic produced by *Streptomyces caespitosus* that has antiproliferative and antineoplastic properties.<sup>18,19</sup> Its antineoplastic activity is similar to that of the alkylating agents, causing single-band breakage and cross-linking of DNA at the adenosine and guanine molecules, inhibiting DNA synthesis by blocking DNA-dependent RNA synthesis and therefore inhibiting RNA and protein formation.<sup>19,20</sup> Recent experiments have shown that the mechanism of action is probably more profound. It has been suggested that mitomycin-C would bind at the promoter sites of the inducible genes involved in wound healing, therefore inhibiting expression of those genes.<sup>21</sup> So as an antiproliferative agent, mitomycin can inhibit fibroblast proliferation and decrease scar formation, having gained wide relevance as a preventive scar formation treatment in different fields such as ophthalmology and in the respiratory and digestive tracts. It has shown encouraging results in the treatment of pediatric refractory esophageal strictures<sup>18,19</sup> and in the prevention and treatment of laryngeal and tracheal stenosis.<sup>9,20,22,23</sup>

We employed a mitomycin solution at a concentration of 1 mg/mL, which is the dosage used for other authors,<sup>9,18</sup> and no side effects appeared during follow-up. However, lower dosage of mitomycin (concentration between 0.1 and 1 mg/mL) has also been shown to be effective.<sup>18</sup>

Nevertheless, it is difficult to know what is the real effect of mitomycin application is in these patients. There are no prospective studies comparing both procedures (endoscopic dilation with mitomycin vs. without mitomycin).

Patients with acquired or congenital SGS present different clinical features (age, location, severity and length of the stenosis, and associated comorbidities) that are closely related to the prognosis and final outcome. These conditions are variable in each patient, so comparative studies between traditional open surgery and endoscopic techniques are difficult to perform. Therefore, descriptive case series are important to know the management and surgical indications in this pathology.

## Conclusion

Early endoscopic balloon dilation after the appearance of symptoms was an effective and safe treatment in acquired tracheal and subglottic stenoses.

In our experience, all patients were treated successfully with this procedure, avoiding open laryngotracheal interventions and reoperation in case of previous surgery. For this reason, we elected endoscopic balloon dilation as the first treatment option in all grades of acquired tracheal and SGS, reserving open laryngotracheal surgery for congenital SGS and for those high-grade, acquired stenoses unsuccessfully treated after several endoscopic procedures.

We are aware that we cannot exactly size the contribution of mitomycin application in our patients. Comparative prospective studies are needed to know the real benefit of its use, its optimal dosage, time, and type of application before setting recommendations about its use.

## Conflict of Interest

None.

## References

- 1 Cotton RT. Management of subglottic stenosis. *Otolaryngol Clin North Am* 2000;33(1):111-130
- 2 White DR, Cotton RT, Bean JA, Rutter MJ. Pediatric cricotracheal resection: surgical outcomes and risk factor analysis. *Arch Otolaryngol Head Neck Surg* 2005;131(10):896-899
- 3 Matute JA, Villafuella MA, Delgado MD, Berchi FJ, Vazquez J. Surgery of subglottic stenosis in neonates and children. *Eur J Pediatr Surg* 2000;10(5):286-290
- 4 Hebra A, Powell DD, Smith CD, Othersen HB Jr. Balloon tracheoplasty in children: results of a 15-year experience. *J Pediatr Surg* 1991;26(8):957-961
- 5 Durden F, Sobol SE. Balloon laryngoplasty as a primary treatment for subglottic stenosis. *Arch Otolaryngol Head Neck Surg* 2007;133(8):772-775
- 6 Hautefort C, Teissier N, Viala P, Van Den Abbeele T. Balloon dilation laryngoplasty for subglottic stenosis in children: eight years' experience. *Arch Otolaryngol Head Neck Surg* 2012;138(3):235-240
- 7 Bent JP, Shah MB, Nord R, Parikh SR. Balloon dilation for recurrent stenosis after pediatric laryngotracheoplasty. *Ann Otol Rhinol Laryngol* 2010;119(9):619-627
- 8 Whigham AS, Howell R, Choi S, Peña M, Zalzal G, Preciado D. Outcomes of balloon dilation in pediatric subglottic stenosis. *Ann Otol Rhinol Laryngol* 2012;121(7):442-448
- 9 Quesnel AM, Lee GS, Nuss RC, Volk MS, Jones DT, Rahbar R. Minimally invasive endoscopic management of subglottic stenosis in children: Success and failure. *Int J Pediatr Otorhinolaryngol* 2011;75(5):652-656
- 10 Myer CM III, O'Connor DM, Cotton RT. Proposed grading system for subglottic stenosis based on endotracheal tube sizes. *Ann Otol Rhinol Laryngol* 1994;103(4 Pt 1):319-323
- 11 Koempel JA, Cotton RT. History of pediatric laryngotracheal reconstruction. *Otolaryngol Clin North Am* 2008;41(5):825-835, vii
- 12 Monnier P, Lang F, Savary M. Partial cricotracheal resection for severe pediatric subglottic stenosis: update of the Lausanne experience. *Ann Otol Rhinol Laryngol* 1998;107(11 Pt 1):961-968
- 13 Monnier P, George M, Monod ML, Lang F. The role of the CO2 laser in the management of laryngotracheal stenosis: a survey of 100 cases. *Eur Arch Otorhinolaryngol* 2005;262(8):602-608
- 14 Bakthavachalam S, McClay JE. Endoscopic management of subglottic stenosis. *Otolaryngol Head Neck Surg* 2008;139(4):551-559
- 15 Maksoud-Filho JG, Gonçalves ME, Cardoso SR, Tannuri U. Early diagnostic and endoscopic dilatation for the treatment of acquired upper airway stenosis after intubation in children. *J Pediatr Surg* 2008;43(7):1254-1258
- 16 Mirabile L, Serio PP, Baggi RR, Couloigner VV. Endoscopic anterior cricoid split and balloon dilation in pediatric subglottic stenosis. *Int J Pediatr Otorhinolaryngol* 2010;74(12):1409-1414
- 17 Bajaj Y, Cochrane LA, Jephson CG, et al. Laryngotracheal reconstruction and cricotracheal resection in children: recent experience at Great Ormond Street Hospital. *Int J Pediatr Otorhinolaryngol* 2012;76(4):507-511

- 18 Berger M, Ure B, Lacher M. Mitomycin C in the therapy of recurrent esophageal strictures: hype or hope? *Eur J Pediatr Surg* 2012; 22(2):109–116
- 19 Rosseneu S, Afzal N, Yerushalmi B, et al. Topical application of mitomycin-C in oesophageal strictures. *J Pediatr Gastroenterol Nutr* 2007;44(3):336–341
- 20 Rahbar R, Jones DT, Nuss RC, et al. The role of mitomycin in the prevention and treatment of scar formation in the pediatric aerodigestive tract: friend or foe? *Arch Otolaryngol Head Neck Surg* 2002;128(4):401–406
- 21 Gray SD, Tittle N, Li W. The effect of mitomycin on extracellular matrix proteins in a rat wound model. *Laryngoscope* 2003;113(2): 237–242
- 22 Warner D, Brietzke SE. Mitomycin C and airway surgery: how well does it work? *Otolaryngol Head Neck Surg* 2008;138(6): 700–709
- 23 Smith ME, Elstad M. Mitomycin C and the endoscopic treatment of laryngotracheal stenosis: are two applications better than one? *Laryngoscope* 2009;119(2):272–283