

# Gelfoam for Closure of Large Percutaneous Transhepatic and Transsplenic Puncture Tracts in Pediatric Patients

## Gelfoamapplikation zum Verschluss großlumiger perkutaner transhepatischer und transsplenischer Zugangswege bei pädiatrischen Patienten

### Authors

W. Uller<sup>1</sup>, R. Müller-Wille<sup>1</sup>, D. Grothues<sup>2</sup>, J. Schelling<sup>2</sup>, N. Zausig<sup>1</sup>, M. Loss<sup>3</sup>, C. Stroszczyński<sup>1</sup>, W. A. Wohlgemuth<sup>1</sup>

### Affiliations

<sup>1</sup> Department of Radiology, University Medical Center Regensburg

<sup>2</sup> KUNO University Children's Hospital, University Medical Center Regensburg

<sup>3</sup> Department of Surgery, University Medical Center Regensburg

### Key words

- ◉ abdomen
- ◉ embolization
- ◉ transplantation
- ◉ needle tract
- ◉ intrahepatic
- ◉ intrasplenic

received 24.7.2013

accepted 1.10.2013

### Bibliography

DOI <http://dx.doi.org/10.1055/s-0033-1355905>  
 Published online: 23.1.2014  
 Fortschr Röntgenstr 2014; 186: 693–697 © Georg Thieme Verlag KG Stuttgart · New York · ISSN 1438-9029

### Correspondence

**Dr. Wibke Uller**  
 Institut für Röntgendiagnostik,  
 Universitätsklinikum  
 Regensburg  
 Franz-Josef Strauß-Allee 11  
 93053 Regensburg  
 Germany  
 Tel.: ++49/0941/94474 31  
 Fax: ++49/0941/94474 81  
 wibke.uller@ukr.de

### Zusammenfassung



**Ziel:** Evaluation von Effizienz und Sicherheit der Anwendung von Gelfoam zum Verschluss großlumiger transhepatischer und transsplenischer Zugangswege bei Kindern.

**Material und Methode:** Zwischen Januar 2012 und Mai 2013 wurden 8 perkutane transhepatische und 3 perkutane transsplenische Zugangswege bei pädiatrischen Patienten mittels Gelfoam verschlossen. Um die Effektivität und Sicherheit dieses Vorgehens zu bestimmen wurden technischer Erfolg, definiert als erfolgreicher Verschluss des Punktionstrakts ohne Zeichen einer Blutung, Komplikationen und Überleben der Patienten als primäre Studienendziele festgelegt. Als sekundäre Studienendpunkte wurde das Auftreten von lokalen und systemischen Entzündungsreaktionen festgelegt.

**Ergebnisse:** Die gesamte Überlebensrate betrug 100% über einen medianen follow-up von 256 Tage. Das Vorgehen war in 10 von 11 Fällen technisch erfolgreich. Bei einem Patienten kam es zu einer Nachblutung die erfolgreich mit einer Bluttransfusion behandelt werden konnte. Es kam zu keinen weiteren Nachblutungen. Es traten keine Gelfoam-assoziierten lokalen oder systemischen Entzündungsreaktionen auf.

**Schlussfolgerung:** Die perkutane Applikation von Gelfoam ist eine effektive und sichere Methode um transhepatische oder transsplenische Punktionswege bei pädiatrischen Patienten zu verschließen.

**Kernaussage:** Um Blutungen und Nachblutungen zu verhindern sollten größere transhepatische oder transsplenische parenchymale Zugänge bei Kindern nach interventionellen Eingriffen embolisiert werden. Gelfoam verursacht keine Artefakte in der Magnetresonanztomografie und führt im Vergleich zu permanentem Fremdmaterial nicht zu einem erhöhten lokalen oder systemi-

### Abstract



**Purpose:** Evaluation of the efficacy and safety of Gelfoam for the closure of transhepatic or transsplenic parenchymal puncture tracts with large-bore sheaths in pediatric patients.

**Materials and Methods:** Between January 2012 and May 2013, 8 percutaneous transhepatic accesses and 3 percutaneous transsplenic accesses were closed using percutaneous Gelfoam in pediatric patients. The primary study endpoints to determine treatment efficacy and safety were patient survival, technical success defined as successful closure of the puncture tract without signs of bleeding, and complication rates. The secondary study endpoints were the occurrence of local and systemic inflammation.

**Results:** Overall survival was 100% with a median follow-up of 256 days. The procedure was technically successful in 10 of 11 procedures. One patient suffered from bleeding, which was successfully managed by a single blood transfusion. No re-bleeding was detected during follow-up and no surgical interventions were necessary. No signs of local or systemic infections related to the Gelfoam application occurred.

**Conclusion:** Percutaneous Gelfoam application is an effective and safe technique for the closure of transhepatic or transsplenic accesses in pediatric patients.

**Key points:** Interventional closure of large transhepatic and transsplenic parenchymal accesses in children after interventional treatment is recommended to avoid bleeding. Gelfoam application does not cause artifacts in magnetic resonance imaging and does not increase the risk of local or systemic inflammation in comparison to permanent embolic agents. Thus, especially children under immunosuppressive therapy can benefit from the application of Gelfoam.

schen Entzündungsrisiko. Von diesen Eigenschaften profitieren insbesondere Kinder die eine immunsuppressive Therapie benötigen.

## Introduction

Pediatric interventional radiology has gained a key role in the management of vascular complications after liver transplantation and in the treatment of abdominal shunt stenoses [1]. Transhepatic access to the portal vein is considered to be the primary method, but occasionally an additional transsplenic access is needed. Especially in relation to the child's size, the diameter of the access might be large which always carries the risk of postinterventional bleeding through the puncture tract. Therefore, closure of the parenchymal access is recommended and to date mostly performed by placing permanent materials like coils [2].

Gelfoam is a hemostatic absorbable gelatin sponge prepared from purified pork skin gelatin capable of absorbing up to 45 times its weight in blood [3]. Its effect appears to be more physical than the result of primary inducing of the coagulation mechanism: bleeding is arrested by the formation of an artificial clot and by providing a structural support that facilitates and hastens clotting [4, 5]. The gelatin sponge becomes liquefied within a week and is absorbed completely within four to six weeks. It has been used in different clinical indications like traumatic bleeding, gastrointestinal bleeding and preoperative tumor embolization [3]. The purpose of this study was to retrospectively evaluate the efficacy and safety of Gelfoam application for the closure of large transhepatic and transsplenic parenchymal puncture tracts in pediatric patients.

## Patients and Methods

### Patients

Patients were obtained from a prospective clinical database and reviewed for pediatric patients who underwent closure of the transhepatic or transsplenic puncture tract with Gelfoam between January 2012 and May 2013. Informed consent was obtained from the parents.

### Interventional procedures

The procedures were performed during general anesthesia. Perioperative antibiotic prophylaxis was routinely provided. Transhepatic or transsplenic puncture of a peripheral portal vein segment or peripheral splenic vein branch was performed with a 21-gauge needle (CHIBA, Boston Scientific, Natick, MA, USA) under ultrasound guidance. A cope wire (Cook, Bjæverskov, Denmark) was lanced to a central portal or splenic branch and subsequent 4-F up to 6-F sheaths were placed. After full endovenous heparinization (70–100 IU per kilogram body weight), angulated 4-F of 5-F catheters and microcatheters (Progreat, Terumo) were used to transverse the vascular stenoses. After diagnostic portography, balloon or stent angioplasty, closure of the parenchymal access was performed using a special technique: a sheet of Gelfoam (20 mm × 60 mm × 7 mm, Pfizer, New York, USA) was first cut on its long axis (two times) and

### Citation Format:

- ▶ Uller W, Müller-Wille R, Grothues D et al. Gelfoam for Closure of Large Percutaneous Transhepatic and Transsplenic Puncture Tracts in Pediatric Patients. *Fortschr Röntgenstr* 2014; 186: 693–697

then again on its short axis, resulting in cubic particles of about 7 mm × 7 mm × 7 mm in size. The Gelfoam pieces were placed in the back of a 3 ml syringe and the plunger was replaced. A second syringe was filled with 3 ml of a pure contrast media solution. Concentrated Gelfoam slurry was mixed by using a two-way stopcock and by filling and emptying these two syringes multiple times.

The vascular sheaths were drawn back and simultaneously contrast medium was applied under fluoroscopy in order to determine the exact puncture site of the portal or splenic vein (entrance point of sheath) and to detect eventual fistulas to the hepatic vein or other portal vein segments. A 4-F catheter completely filled with Gelfoam slurry was advanced into the sheath when the tip of the sheath was located in the liver or spleen parenchyma distal to the puncture site and to possible fistulae. The tip of the Gelfoam-filled 4-F catheter was aligned with the tip of the sheath in order to minimize the size of dead space. Concentrated Gelfoam slurry was then applied under fluoroscopy while simultaneously pulling back both the sheath and the Gelfoam-filled catheter until the skin was reached (◉ Fig. 1). The puncture tract was inspected for potential external bleeding and manual compression of the puncture tract was applied for 2 minutes.

After intervention, all patients who underwent balloon or stent angioplasty received subcutaneous low molecular weight heparin (Enoxaparin) in a prophylactic dosage; in three patients acetylsalicylic acid was additionally applied (patient # 8, #10, #11). Procedure-related minor and major complications were categorized according to the Society of Interventional Radiology (SIR) classification system [6].

### Follow-up

All patients were monitored by ultrasound examination of the abdomen within 24 hours after interventional procedure. Ultrasound was carried out to check for any localized or diffuse fluid accumulation and parenchymal hematoma. Clinical follow-up examinations assessed the overall condition of the patient, signs of abdominal pain and local or systemic infection. Diagnosis of systemic infection was further based on body temperature, CRP and leukocyte levels. Laboratory follow-up evaluation analyzed hemoglobin, blood counts, CRP and leukocyte levels. Ultrasound and clinical follow-up was performed at least every 3 months after patient discharge in the first postprocedural year and thereafter every 6 to 12 months.

### Study endpoints

The primary study endpoints to determine efficacy and safety were survival, technical success, defined as successful closure of the transhepatic or transsplenic puncture tract and complication rates. Secondary study endpoints were the occurrence of local (cutaneous or hepatic) inflammation and systemic inflammation or the occurrence of bleeding during follow-up.

## Results



### Patients

During the study period a total of 8 percutaneous transhepatic and 3 percutaneous transsplenic puncture tracts in children were closed using Gelfoam. The study population included 6 girls and 4 boys with a median age at the time of intervention of 769 days (range; 9 months to 11 years). The body weight at the time of intervention ranged from 6.5 kg to 33 kg (median body weight 11.5 kg).

All children except patient #8 received immunosuppressive therapy related to liver transplantation. Prior to intervention, one patient (patient #6) received no anticoagulant. 7 of 10 children received acetylsalicylic acid ( $3 \times 25$  mg/week – 50 mg/day), one child received heparin (100 IE/kg/day; patient #5) and another low molecular weight heparin ( $2 \times 20$  mg Enoxaparin/day; patient #8).

The median thrombocyte values were 164/nl (range; 71/nl – 284/nl), the median activated partial thromboplastin time measured 33.2 seconds (range; 27.7–42.3) and the median Quick values were 87% (range 77–100%) directly before interventional procedures.

### Interventional Procedure

Patient #8 suffered from stenosis of a venous mesenterico-portal shunt, which was treated by stent angioplasty. The other 9 children underwent pediatric liver transplantation and suffered from stenoses of the portal vein, which required diagnostic portography combined with pressure gradient measurement ( $n = 1$ , patient #6), balloon angioplasty ( $n = 1$ , patient #3) and stent angioplasty ( $n = 7$ ) of the portal vein. Via the transhepatic access, a 4-F catheter was used in one patient, 4-F sheaths were used in 2 patients, 5-F sheaths in 2 patients and 6-F sheaths in 3 patients. Via the transsplenic access, a 4-F sheath was used in one patient and 6-F sheaths were used in 2 patients. **Table 1** lists the

patients' age, weight and length, the type of vascular access and the treatment procedures.

### Clinical Course and Complications

All patients were alive at the end of the observation period (June 2013, median follow-up 256 days, range 37–490 days). Ultrasound performed within 24 hours after intervention revealed no subcapsular hematoma of the liver or spleen or free fluid around these organs. No segmental or total occlusion of a portal or liver vein branch was detected. External bleeding from the puncture site did not occur in any patients.

Patients #2 and #4 presented with low hemoglobin values prior to intervention. Therefore, patient #2 received 300 ml of an erythrocyte concentrate during the radiological intervention unrelated to the puncture. After intervention, the hemoglobin levels did not change in this patient.

In patient #4 the hemoglobin value decreased from 7.7 g/dl to a minimum of 5.3 g/dl after intervention. In this child, ultrasound examination performed directly after intervention showed diffuse fluid accumulation, which did not increase during the post-procedural period but was deemed to be puncture tract-related. After application of 250 ml of an erythrocyte concentrate, the hemoglobin values increased and were stable during follow-up (9.1 g/dl). This patient was monitored in the intensive care unit for one day.

Median hemoglobin values of all patients decreased from 9.9 g/dl (range: 7.7–11.4 g/dl) to 8.9 g/dl (range: 5.3–10.7 g/dl), except in patient #2, who was not included because of erythrocyte concentrate application during intervention. The procedure-related major complication rate was 9% ( $n = 1$ ; 250 ml of an erythrocyte concentrate; SIR type C: requires therapy, minor hospitalization <48 h). Technical success was achieved in 10 of 11 closures of the hepatic or splenic parenchymal access. No procedure-related minor complications were observed.

patient [#]	sex	age [days]	weight [kg]	length [cm]	vascular access	treatment procedure	follow-up
1	F	727	10.8	81	transsplenic 6-F	stent angioplasty portal vein	
2	F	577	9.1	78.5	transhepatic 4-F transsplenic 4-F	stent angioplasty portal vein	
3	M	810	12.1	87	transsplenic 6-F	balloon angioplasty portal vein	
4	F	899	13.3	90	transhepatic 6-F	stent angioplasty portal vein	bleeding (250 ml erythrocyte concentrate)
5	F	1740	19.6	103	transhepatic 5-F	stent angioplasty portal vein	
6	M	4062	33	144	transhepatic 4-F	diagnostic (portography and pressure measurement)	
7	M	294	7.4	68	transhepatic 6-F	stent angioplasty portal vein	
8	M	1491	14.2	96.5	transhepatic 5-F	stent angioplasty mesentericportal shunt	
9	F	278	7.8	65	transhepatic 6-F	stent angioplasty portal vein	
10	F	344	6.5	73	transhepatic 4-F	stent angioplasty portal vein	

**Table 1** Patient data, F = female; M = male; kg = kilogram; cm = centimeters.

**Tab. 1** Patientendaten *F* = weiblich; *M* = männlich; *kg* = Kilogramm; *cm* = Zentimeter.

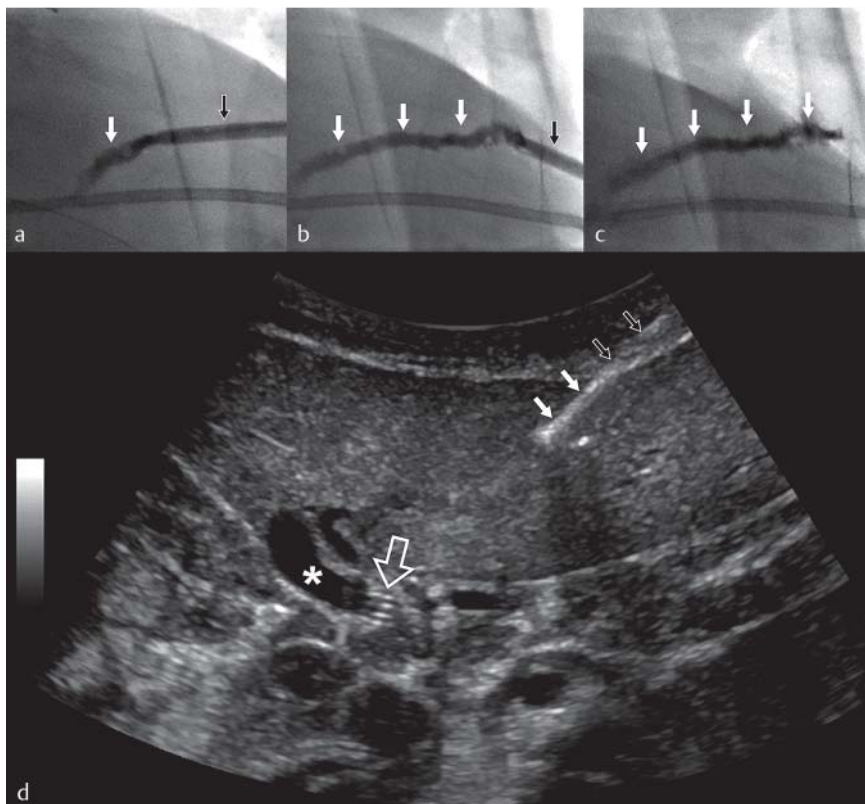
No signs of local inflammation were observed, and none of the patients suffered from systemic inflammation caused by Gelfoam. No re-bleeding was detected during follow-up.

## Discussion

Interventional radiological techniques are a less invasive alternative to surgery for treating portal vein stenoses after pediatric liver transplantation or abdominal shunt stenoses. These techniques have proven to be effective and long-lasting [1]. Balloon angioplasty is the treatment of choice for those types of stenoses, but frequent recurrence of portal vein stenoses after balloon dilation represents a major problem in pediatric patients [7, 8]. If balloon angioplasties fail, stent placement can serve as an alternative but should be restricted to special cases with regard to graft and patient growth. In consideration of the future growth of the organ, a self-expandable stent with a large diameter (40% oversizing) should be selected to permit repeated dilations of the stent [1]. This necessitates large access sizes in relation to the size of the children. Frequent complications are hemorrhage from the puncture site and intraparenchymal hematoma. Anticoagulation, which is required prior to, during and after intervention additionally increases this risk. Furthermore, Ueda and coworkers observed low platelet counts in all patients suffering from late-onset portal vein stenoses (PVS) after pediatric living donor liver transplantation [9]. Radiological re-intervention is rarely feasible and surgical management is often needed if bleeding from the transhepatic puncture tract appears and conservative treatment fails. To reduce the risk of transhepatic bleeding, some authors routinely perform coil embolization of transhepatic puncture tracts [2]. Carnevale et al. performed autologous clot tract embolization by filling the sheath with the patient's blood,

pulling it back to the parenchymal tract and leaving it in place for at least 10–15 minutes for hemostasis. Compression was additionally performed for 15 minutes [10]. Reports concerning transsplenic accesses of more than 5-F in children are anecdotal and coils were used for closure of these puncture tracts [11]. Although coil application for closure of percutaneous transhepatic and transsplenic accesses is considered safe and effective even in pediatric patients after liver transplantation, there are several disadvantages concerning these patients: (1) coils cause MR artifacts; and (2) coils are permanent and carry the risk of local or systemic infection under immunosuppression. Since biliary strictures are a common problem after PLT with a reported incidence of 10–35% [12], development of cholestasis and cholangitis may trigger (chronic) infection of the durable material. Especially in infants it remains unclear to date if permanent material causes problems in case of patient growth, liver growth or liver torsion. Non-permanent agents like Gelfoam have the theoretical advantage that they represent only a transient problem if misplaced (e. g. in branches of the portal vein, the liver/splenic vein or branches of the hepatic/splenic artery). Even accidental placement outside of the organ capsule only poses a temporary problem. Hence, temporary agents for the embolization of the parenchymal tract represent a good alternative and should be considered superior to permanent materials or agents. Froud and coworkers combined a single Gelfoam plug with injection of D-Stat, a temporary collagen/thrombin paste for successful closure of the liver tracts after percutaneous transhepatic islet transplantation in 5 adults [13]. To the best of our knowledge, transhepatic application of D-Stat in children has not yet been described.

In this study Gelfoam, an absorbable gelatin sponge, was used for closure of the percutaneous transhepatic and transsplenic accesses in very young children (median age of 769 days). One previously anemic child received transfusion of blood products pre-



**Fig. 1** Gelfoam for closure of a 6-F percutaneous transhepatic puncture tract in a 9-month-old girl after stent angioplasty of the portal vein (patient #9). **a–c** Fluoroscopy shows the Gelfoam slurry (white arrows), which was applied during simultaneous pull back of the 6-F sheath (black arrows) and the Gelfoam-filled catheter. **d** Control sonography detects echogenic intrahepatic (small white arrows) and extrahepatic (small black arrows) Gelfoam after stent angioplasty of the portal vein (asterisk: portal vein; large white framed arrow: stent).

**Abb. 1** Verschluss eines 6-F messenden perkutanen transhepatischen Zugangs mittels Gelfoam bei einem 9 Monate alten Mädchen nach Stent-Angioplastie der Pfortader (Patient #9). **a–c** Die Fluoroskopie zeigt Gelfoam (weiße Pfeile), das während kontinuierlichem gleichzeitigem Rückzug der Schleuse (schwarze Pfeile) und des mit Gelfoamgefüllten Katheters appliziert wurde. **d** Die Kontroll-Sonografie zeigt das echoreiche intrahepatische (kleine weiße Pfeile) und extrahepatische (kleine schwarze Pfeile) Gelfoam nach Stent-Angioplastie der Pfortader (Stern: Pfortader; großer weiß umrandeter Pfeil: Stent).



sumably because of transhepatic parenchymal puncture tract bleeding. Technical success was achieved in 91% of the cases. Since the available literature concerning transhepatic and transsplenic intervention of the portal vein does not focus on the complication and success rate of closure of the puncture tracts, the success and complication rate of this series is rarely comparable. Gelfoam slurry preparation and application is easy and safe to use by application through a small-bore catheter as described in detail above. Riddle et al. described the migration of Gelfoam in the gallbladder after liver biopsy in a 7-year-old child [14]. Nevertheless, the risk of Gelfoam displacement into the biliary system or in the hepatic vein or artery can be reduced by contrast medium application through the sheath while pulling it back in the parenchymal tract under fluoroscopy to detect unexpected fistulae. In contrast to permanent embolic agents, an accidental migration of Gelfoam would be a temporary problem. We applied Gelfoam only within the peripheral puncture tract, distal to detected fistulae to the biliary or vascular system. Since Gelfoam was mixed with pure contrast media, the application can further be easily visualized by fluoroscopy. In addition, Gelfoam slurry can be detected by ultrasonography as echogenic material in the parenchymal tract.

Choi et al. reported a Histoacryl-Lipiodol mixture plugging as an efficacious method to control postsplenic biopsy bleeding in dogs, but the detection of multiple Histoacryl-Lipiodol mixture emboli in the splenic and portal veins on follow-up computed tomography calls the application of Histoacryl-Lipiodol into question [15].

To summarize, Gelfoam application is safe and effective for closure of parenchymal transhepatic and transsplenic accesses in pediatric patients when applied as described. Due to its temporary characteristics, it is expected to be superior to permanent closure material concerning the onset of inflammation in immunosuppressive patients, artifacts in follow-up examinations and patient growth.

### Clinical relevance of the study



Closure of transhepatic and transsplenic parenchymal puncture tracts with Gelfoam

- ▶ is technically feasible
- ▶ is easy to perform

- ▶ is a safe alternative to permanent liquid or solid agents
- ▶ is superior to permanent agents and materials in pediatric patients

### References

- 1 Uller W, Knoppke B, Schreyer AG et al. Interventional Radiological Treatment of Perihepatic Vascular Stenosis or Occlusion in Pediatric Patients After Liver Transplantation. *Cardiovasc Intervent Radiol* 2013, (Epub ahead of print)
- 2 Miraglia R, Maruzzelli L, Caruso S et al. Interventional radiology procedures in pediatric patients with complications after liver transplantation. *Radiographics* 2009; 29: 567–584
- 3 Abada HT, Golzarian J. Gelatine sponge particles: handling characteristics for endovascular use. *Tech Vasc Interv Radiol* 2007; 10: 257–260
- 4 Guralnick WC, Berg L. Gelfoam in oral surgery; a report of 250 cases. *Oral Surg Oral Med Oral Pathol* 1948; 1: 632–639
- 5 Jenkins HP, Janda R, Clarke J. Clinical and experimental observations on the use of gelatin sponge or foam. *Surgery* 1946; 20: 124–132
- 6 Leoni CJ, Potter JE, Rosen MP et al. Classifying complications of interventional procedures: a survey of practicing radiologists. *J Vasc Interv Radiol* 2001; 12: 55–59
- 7 Funaki B, Rosenblum JD, Leef JA et al. Angioplasty treatment of portal vein stenosis in children with segmental liver transplants: mid-term results. *Am J Roentgenol Am J Roentgenol* 1997; 169: 551–554
- 8 Shibata T, Itoh K, Kubo T et al. Percutaneous transhepatic balloon dilation of portal venous stenosis in patients with living donor liver transplantation. *Radiology* 2005; 235: 1078–1083
- 9 Ueda M, Egawa H, Ogawa K et al. Portal vein complications in the long-term course after pediatric living donor liver transplantation. *Transplant Proc* 2005; 37: 1138–1140
- 10 Carnevale FC, de Tarso MA, Moreira AM et al. Long-term results of the percutaneous transhepatic venoplasty of portal vein stenoses after pediatric liver transplantation. *Pediatr Transplant* 2011; 15: 476–481
- 11 Bertram H, Pfister ED, Becker T et al. Transsplenic endovascular therapy of portal vein stenosis and subsequent complete portal vein thrombosis in a 2-year-old child. *J Vasc Interv Radiol* 2010; 21: 1760–1764
- 12 Lallier M, St-Vil D, Luks FI et al. Biliary tract complications in pediatric orthotopic liver transplantation. *J Pediatr Surg* 1993; 28: 1102–1105
- 13 Froud T, Yrizarry JM, Alejandro R et al. Use of D-STAT to prevent bleeding following percutaneous transhepatic intraportal islet transplantation. *Cell Transplant* 2004; 13: 55–59
- 14 Riddle C, Ahmed B, Doyle J et al. Migration of Gelfoam to the gallbladder after liver biopsy. *Pediatr Radiol* 2008; 38: 806–809
- 15 Choi SH, Lee JM, Lee KH et al. Postbiopsy splenic bleeding in a dog model: comparison of cauterization, embolization, and plugging of the needle tract. *Am J Roentgenol Am J Roentgenol* 2005; 185: 878–884