

Magnetic Resonance Imaging-Guided Prostate Biopsy: Institutional Analysis and Systematic Review

Magnetresonanz gezielte Biopsie der Prostata: Institutionelle Analyse und systematischer Review

Authors

S. H. Polanec¹, T. H. Helbich¹, M. Margreiter², H. C. Klingler², K. Kubin¹, M. Susani³, K. Pinker-Domenig¹, P. Brader¹

Affiliations

¹ Department of Biomedical Imaging and Image-guided Therapy, Division of Molecular and Gender Imaging, Medical University of Vienna

² Department of Urology, Medical University of Vienna

³ Department of Pathology, Medical University of Vienna

Key words

- prostate
- biopsy
- interventional MR

received 8.4.2013
accepted 23.8.2013

Bibliography

DOI <http://dx.doi.org/10.1055/s-0033-1355546>
Published online: 4.2.2014
Fortschr Röntgenstr 2014; 186: 501–507 © Georg Thieme Verlag KG Stuttgart · New York · ISSN 1438-9029

Correspondence

Prof. Thomas H. Helbich
Department of Biomedical Imaging and Image-guided Therapy, Division of Molecular and Gender Imaging, Medical University of Vienna
Währinger Gürtel 18–20
1090 Wien
Austria
Tel.: ++ 43/1 40/4 00 48 20
Fax: ++ 43/1 40/4 00 48 98
Thomas.Helbich@akhwien.at

Zusammenfassung



Ziel: Evaluierung der Detektionsrate von Prostatakarzinomen nach MR-gezielter Biopsie (MRGB); Beobachtung des Patientenkollektives mit einem negativen MRGB-Ergebnis, sowie ein Vergleich der Resultate mit der aktuellen Literatur.

Material und Methoden: Insgesamt wurden 41 Patienten mit einer kombinierten MRT und MRGB, in die von der Ethikkommission geprüfte Studie eingeschlossen. Die MRGB wurde an einem 1.5 T System durchgeführt und die Biopsienadel wurde transrektal eingeführt. Die Verlaufskontrolle der Patienten betrug zwischen 12 und 62 Monaten. Um unsere Ergebnisse mit der rezenten Literatur zu vergleichen, wurde eine systematische Literatursuche durchgeführt. Es wurden 17 Publikationen evaluiert.

Ergebnisse: Die tumorsuspekte Läsion wurde in allen Fällen erfolgreich biopsiert. Ein klinisch signifikantes PCa wurde in 11 Patienten (26,9%) diagnostiziert. Bei den übrigen 30 Patienten zeigte sich ein gutartiges Biopsieergebnis. In der Verlaufskontrolle der Patienten mit gutartigem histologischen Befund (durchschnittlich 3,1 Jahre) wurde kein neues PCa entdeckt.

Schlussfolgerung: Die MRGB ist eine effiziente Methode zum Nachweis von klinisch signifikanten PCa und dies geht einher mit der rezenten Literatur. In der Verlaufskontrolle der Patienten mit benigner Histologie wurde kein neues PCa entdeckt. Auch wenn die Wahrscheinlichkeit eines PCa nach einer MRGB gering ist, ist die aktive Überwachung nicht außer Acht zu lassen.

Abstract



Objectives: To evaluate the detection rate of prostate cancer (PCa) after magnetic resonance-guided biopsy (MRGB); to monitor the patient cohort with negative MRGB results and to compare our own results with other reports in the current literature.

Materials and Methods: A group of 41 patients was included in this IRB-approved study and subjected to combined MRI and MRGB. MRGB was performed in a closed 1.5 T MR unit and the needle was inserted rectally. The follow-up period ranged between 12 and 62 months (mean 3.1 years). To compare the results with the literature, a systematic literature search was performed. Eighteen publications were evaluated.

Results: The cancer-suspicious regions were punctured successfully in all cases. PCa was detected in eleven patients (26.9%) who were all clinically significant. MRGB showed a benign histology in the remaining 30 patients. In the follow-up (mean 3.1 years) of patients with benign histology, no new PCa was diagnosed. The missed cancer rate during follow-up was 0.0% in our study.

Conclusion: MRGB is effective for the detection of clinically significant cancer, and this is in accordance with the recent literature. In the follow-up of patients with benign histology, no new PCa was discovered. Although the probability of developing PCa after negative MRGB is very low, active surveillance is reasonable.

Key points:

- ▶ MRGB is a reliable and safe method for the detection of PCa.
- ▶ In the follow-up of patients with benign biopsy-results, no new PCa was detected.
- ▶ Probability of detecting a cancer after negative MRGB is low.

Introduction

As many as one in six men in Europe is estimated to be diagnosed during their lifetime with prostate cancer (PCa) [1]. As in other cancers, early diagnosis of PCa is very important with regard to outcome and survival. The current diagnostic tools are digital rectal examination (DRE) with a sensitivity of about 37% for cancer detection [2]; serum prostate specific antigen (PSA) measurements; and transrectal ultrasound-guided biopsy (TRUS). This latter technique of prostate examination has limitations due to sampling errors, which result in the inability to detect more than 20% of cancers in the first session [3]. Specific regions, such as the anterior part of the prostate, where more than 25% of carcinomas occur, are insufficiently sampled by TRUS due to limitations in range with this method [4]. Another problem linked with TRUS is the over- or underestimation of the Gleason score, because of unreliable information about the volume, extent, and aggressiveness of prostate cancer [5]. Inaccurate Gleason scoring with TRUS results from sampling errors and is not due to the identification of the most clinically visible lesions with the biopsy needle [6].

In recent years, magnetic resonance imaging (MRI) has been increasingly used for the diagnosis of PCa. The use of MRI allows an exact delineation of the zonal anatomy of the prostate and its surrounding structures, and thus improves the detection of lesions suspected of being cancerous. MRI has also increased the opportunities for image-guided techniques like magnetic resonance imaging-guided biopsy (MRGB), the cancer detection rates of which are noticeably higher than TRUS, ranging from 38% to 59% [7–13]. The literature focuses more on the detection rate of PCa with MRGB than on the outcomes of patients whose biopsy results showed a benign growth histology [14–16].

The purpose of our study was: a) to evaluate the detection rate of clinically significant PCa after MRGB; b) to monitor the patient cohort with a negative MRGB; and c) to compare our own results with the current literature.

Materials and Methods

Patients

Our institutional review board waived the informed consent requirement and approved this retrospective study. Data were collected from our institutional database and from 41 consecutive patients with a median age of 65 years (range 44–75) who had 44 MRGBs (3/41 patients had a second biopsy during follow-up) and also underwent MRI examination before biopsy of the prostate between June 2007 and July 2012. There was an inter-patient variation in the number and protocol of previous negative TRUS sessions in our study. Eighteen patients had just one prior biopsy, eleven had two, seven had three, and two had four negative TRUS biopsies. Only three patients had no prior biopsy. Exclusion criteria were the contraindications for MRI (e.g., cardiac pacemaker, metallic implants, and claustrophobia).

Citation Format:

- ▶ Polanec SH, Helbich TH, Margreiter M et al. Magnetic Resonance Imaging-Guided Prostate Biopsy: Institutional Analysis and Systematic Review. *Fortschr Röntgenstr* 2014; 186: 501–507

Multiparametric Magnetic Resonance Imaging

The MRI examinations from 2007 through 2009 (30 patients) were performed on a clinical 1.5T scanner (Avanto; Siemens Medical Solutions, Erlangen, Germany) with the use of an endorectal coil (eCoil™, Medrad, Pittsburgh/PA, USA) as described earlier [8, 17–19]. From 2010 to 2012, all MRI scans were performed on a 3.0T scanner (Tim Trio; Siemens Healthcare, Erlangen, Germany) using an endorectal coil. In six patients no endorectal coil was used. In patients in whom no coil was used, the rectum was filled with ultrasonic gel to avoid artifacts. The MRI protocol consists of a high-resolution T2w sequence in all three dimensions, axial diffusion-weighted imaging (DWI) with b-values of 0, 100, 400, and 800 sec/mm², a contrast-enhanced 3D-T1-weighted sequence before and after the application of a standard dose of Gd-DOTA (Dotarem®, Guerbet, France) (dynamic contrast-enhanced imaging – DCE-MRI), and MR spectroscopy [5, 11, 16]. Two radiologists (T.H.H, P.B.) with 12 years and 6 years of prostate MRI experience, respectively, evaluated the MRI examinations. During MRI reading, the clinical data were available for both readers. Cancer-suspicious regions were defined using T2WI in combination with DWI, DCE-MRI, and MR spectroscopy as described by Hambrock et al. [12]. A lesion was defined as suspicious in the case of: low signal intensity areas in the peripheral zone, within the transition zone, a homogeneous low T2 signal intensity area with ill-defined margins or a lenticular shape. After identification of tumor-suspicious areas on T2w images, the ADC maps and mp pharmacokinetic DCE-MRI-derived K^{trans} color maps were evaluated for corresponding suspicious findings. The above-mentioned imaging results were classified according to PI-RADS [20, 21].

Magnetic Resonance Imaging-Guided Biopsy

Four different radiologists performed MRGB. Two-thirds of all MRGBs were performed by the same radiologist, and the remaining MRGBs were performed under his supervision. MRGB of the prostate was performed on average 38.5 days after the initial MRI. For oral antibiotic prophylaxis, all patients received antibiotic therapy with ciprofloxacin, 500 mg (Ciproxin, Bayer, Leverkusen, Germany) for five days starting two days before the procedure. All patients were placed in the prone position in a closed 1.5T MR unit (Magnetom Vision, Siemens Healthcare, Erlangen, Germany) and the needle guide was inserted rectally using a 3D manipulating, MR-compatible biopsy device (Invivo Corp., Gainesville, FL, USA). MRGB was performed on the previously determined cancer-suspicious regions using a 18G MRI-compatible needle. The biopsy kit consists of a base plant, a clamp stand and a sterile, single-use and disposable needle slave. The needle guide can be mechanically angled by hand in all three directions and then fed, under MR guidance, to the lesion to be punctured. A high-resolution T2w sequence was acquired as a baseline image for targeting (TR=5400 ms, TE=112 ms, flip angle=150°, matrix=120×100, slice thickness=3 mm, field of view=250×250 mm). Before obtaining the specimens from the prostate, a control scan was performed, leaving the MRI-compatible needle in the tumor-suspicious area, to display the correct position. The median duration time from patient positioning to intervention

completion was 50 min (45–55 min). Biopsy tissue cores were fixed in formalin and stained with hematoxylin-eosin. In each patient a minimum of five cores (range five to ten) from the suspicious area was obtained. The number of biopsy cores taken was dependent on the size of the cancer-suspicious lesion. A urogenital histopathologist with more than 20 years of experience performed the histopathological evaluation. For cores containing cancer, a Gleason grade was determined using the 2005 International Society of Urogenital Pathology (ISUP) criteria [22]. The primary, secondary, and tertiary Gleason grades were determined and the highest Gleason grade was identified. In patients undergoing radical prostatectomy, PCa was considered clinically significant if any of the following criteria were present: total tumor volume, 0.5 cc or more; Gleason grade, 4 or more; extra-prostatic extension; seminal vesicle invasion; lymph node metastasis (of PCa); or positive surgical margins [23].

Data analysis and follow-up

In all patients, the MRGB histopathological results were correlated with the MRI findings and discussed at a multidisciplinary meeting, which was attended by the radiologist, the urologist, the pathologist and the radiotherapist to determine either treatment planning or the next appropriate procedure.

In patients with malignant biopsy results, radical prostatectomy or radiotherapy was performed. In case of surgery, the findings from the MRI and the MRGB were verified with the histopathological, whole-mount step-section preparation.

Patients with benign biopsy results were subjected to active surveillance with continuous urological examinations and continuous PSA measurements for at least 12 months. Three patients were excluded because the follow-up time was inadequate. In patients with rising PSA levels, MRI and MRGB were performed again.

The data for follow-up were obtained from our institutional database. All relevant parameters, clinical history, complications, histology, Gleason score, PSA values, and mode of therapy were collected.

Review of the literature

A systematic literature search was performed using the medical databases Pubmed and Embase. The goal was to compare our data from MRGB prostate intervention with the recent literature. The key words “MRI-guided prostate biopsy” and “MR-guided prostate biopsy” were used as search terms. The search was limited to a period starting in January 2002 and ending in February 2013, because techniques and equipment have changed since then. Only original investigations published in English and German were included in the comparison. There were 527 results identified by the two databases. Two reviewers (P.B., S.H.P.) independently reviewed all abstracts for relevance with respect to the predefined search question. The results included 17 publications. Almost more than 500 of the publications had to be excluded because they did not report MRGB results or were not original reports. These publications were all evaluated with respect to the number of patients, the detection rate of clinically significant cancers, patient age, the examination time and unit, whether the biopsy was performed with an open or closed system, the needle size, the position of the patient in the MR device, the biopsy access path, and the reported complications and follow-up of patients with negative biopsies, if available.

Statistical analysis

Medians and ranges were used to present the continuous patient data (age and PSA) and categorical data were presented as absolute and relative frequencies. Statistical analysis was performed using the MS office 2008 Excel statistical package (Microsoft).

Results

The PSA level ranged from 0.99 to 30.3 ng/ml (median 9.89 ng/ml). The median number of previous TRUS-guided biopsies was one (range 0–4). Three patients had no prior biopsy, eighteen had just one, eleven had two, seven had three, and two had four negative TRUS biopsies. In total, 44 MRGBs were performed in 41 patients. Three of these patients had a second biopsy because new suspicious lesions were detected on MRI. The cancer-suspicious regions were technically successfully biopsied in all cases, as determined by imaging (◉ Fig. 1). The median duration time for the whole procedure was 50 min (45–55 min). No major complications warranting hospitalization occurred. All patients tolerated the biopsies and no peri- or post-interventional complications were reported (◉ Fig. 2).

The results of the histopathological examination of the MRGBs are summarized in ◉ Table 1. In eleven patients (26.9%) the specimen obtained using MRGB turned out to be cancerous. Nine of these eleven patients with a detectable PCa underwent radical prostatectomy and two underwent external beam radiation. The median Gleason score was 7 (range 6–9). PCa was seen in nine cases in the peripheral zone (82%), one case in the transition zone (9%), and one case in the central zone (9%).

Histopathology revealed benign results in the 33 biopsies in 30 patients (3 patients had a second biopsy). In 17 of these biopsies (51.5%), histopathology revealed prostatitis. Benign hyperplasia was detected in five biopsies (15.2%), and eleven (33.3%) histopathological biopsy results were normal parenchyma. These 30 patients with benign histology results were monitored actively. Three patients were excluded because of a follow-up period of less than 12 months. The mean follow-up period for the remaining 27 patients was 3.1 years (range 12–62 months). During follow-up, PSA measurements were obtained from every patient, and the median level was 6.1 ng/ml (range 0.2–10.2 ng/ml; and one outlier 57.0 ng/ml). Five patients underwent further MR imaging, and three patients were biopsied twice and again with a benign histology result, and with no change during active surveillance. Following 62 months, no PCa was detected in the patient group of 27 men with a prior negative MRGB.

An overview of the literature including our own results appraising MRGB is summarized in ◉ Table 2. Overall a total number of 908 MRGBs in 898 patients were performed and 403 cases of PCa were detected. The detection rate for clinically significant cancer (CSC) ranged from 80.8–100%. The intervention time for MRGB was between 19–120 min (median 50 min). Almost all MRGBs were performed on a closed 1.5 or 3.0 T unit with a 16- or 18-gauge (G) needle. In only one study the biopsy was performed in an open low-field 0.2 T system. In 14 studies, the transrectal approach was used, whereas in three studies, the transgluteal approach was used with a 15 G needle and in one the transperineal approach was described. The patients' position was prone, supine or lateral in closed systems and, in the open system, the position used for biopsy was lateral decubitus. Four studies described a follow-up between 0.4–3.1 years of the pa-

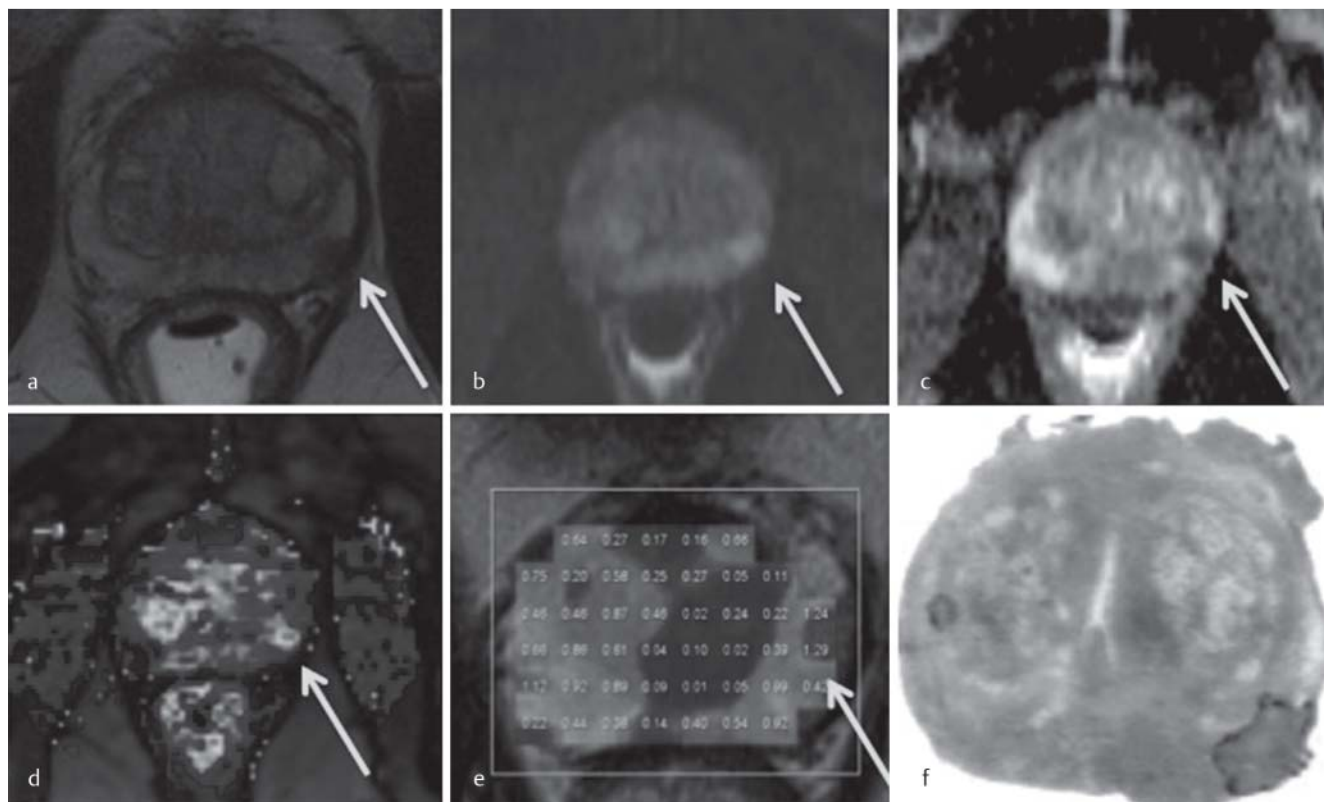


Fig. 1 MRI of the prostate from a 71-year-old patient with a PSA level of 6.4 ng/ml and one prior negative TRUS biopsy. **a** Axial T2-weighted image shows a cancer-suspicious region on the left side with low signal intensity of the peripheral zone (arrow). **b** Consecutive axial diffusion-weighted MR. **c** Apparent diffusion coefficient map shows restricted diffusion (arrow). **d** Axial dynamic contrast-enhanced MR image with a color-coded overlay shows intense early enhancement of the lesion (arrow). **e** MRSI map shows elevated choline/citrate ratio in the suspicious region (arrow). **f** Histopathological evaluation after radical prostatectomy.

Abb. 1 MRT der Prostata eines 71-jährigen Patienten mit einem PSA-Wert von 6.4 ng/ml und vorangegangener negativer TRUS- Biopsie. **a** Axiales T2-gewichtetes Bild mit einem tumorverdächtigem Areal mit erniedrigte Signalintensität in der peripheren Zone links (Pfeil). **b** Korrelierende diffusionsgewichtete Sequenz (DWI): Fokales hyperintenses Areal (Pfeil), **c** mit reduzierten apparenten Diffusionskoeffizienten (ADC) (Pfeil) **d** In der dynamischen kontrastmittelverstärkten Sequenz (DCE) zeigt sich eine fokale Mehrdurchblutung (Pfeil) **e** sowie in der 1H-Spektroskopie ein erhöhtes Verhältnis Cho>> Citrat. **f** Histologisches Präparat nach radikaler Prostatektomie.

tients under active surveillance. The detection rates for cancer during follow-up ranged between 0.0% and 10.8%.

Discussion

The results of the present study demonstrate that MRGB is a reliable, safe, and accurate method for the detection of clinically significant cancer and for ruling out cancer in patients with a negative biopsy, since no new PCa was diagnosed during surveillance. In addition our results are in accordance with the results reported in the literature including more than 908 biopsies of the prostate.

One of the main interventional methods for the diagnosis of PCa is TRUS-guided biopsy. A sensitivity of 39–52% and a specificity of 81–82% are reported when TRUS is applied as a sextant biopsy [24]. However, about 20% of cases of PCa are not detected at the first biopsy session. The cancer detection rate for TRUS-guided biopsy in the second session is reportedly 22% [25].

MRI as a diagnostic tool for PCa has been established in the recent years. It allows an exact delineation of the zonal anatomy of the prostate and also an improved detection rate of cancer-suspicious regions. The use of MRI has increased the opportunities for image-guided techniques like MRGB, cancer detection rates of

which are noticeably higher than the detection rates of TRUS, ranging from 38% to 59%. TRUS biopsy has limitations due to sampling errors, which result in the inability to detect more than 20% of cancers in the first session [3]. Specific regions, such as the anterior part of the prostate, where more than 25% of carcinomas occur, are insufficiently sampled by TRUS due to limitations in range with this method [4]. Another problem linked with TRUS is the over- or underestimation of the Gleason score, because of unreliable information about the volume, extent, and aggressiveness of prostate cancer [5]. Inaccurate Gleason scoring with TRUS results from sampling errors and is not due to the identification of the most clinically visible lesions with the biopsy needle [6].

In our study group of 41 consecutive patients, PCa was detected in 27% of the cases. This is slightly lower compared to other MRGB studies reporting a diagnostic accuracy ranging between 38–59% [5, 7–11, 13–16, 18, 19, 26–30]. This could have been due to the fact that we included consecutive patients in our study and not solely patients with a high risk profile for PCa [18]. In our study patients with a low risk profile for PCa had solely a suspicious finding on diagnostic MRI and low PSA and the majority had no or just one TRUS.

It is evident that performing MRGB is more expensive than TRUS. However, an increase in diagnostic accuracy resulting in an opti-

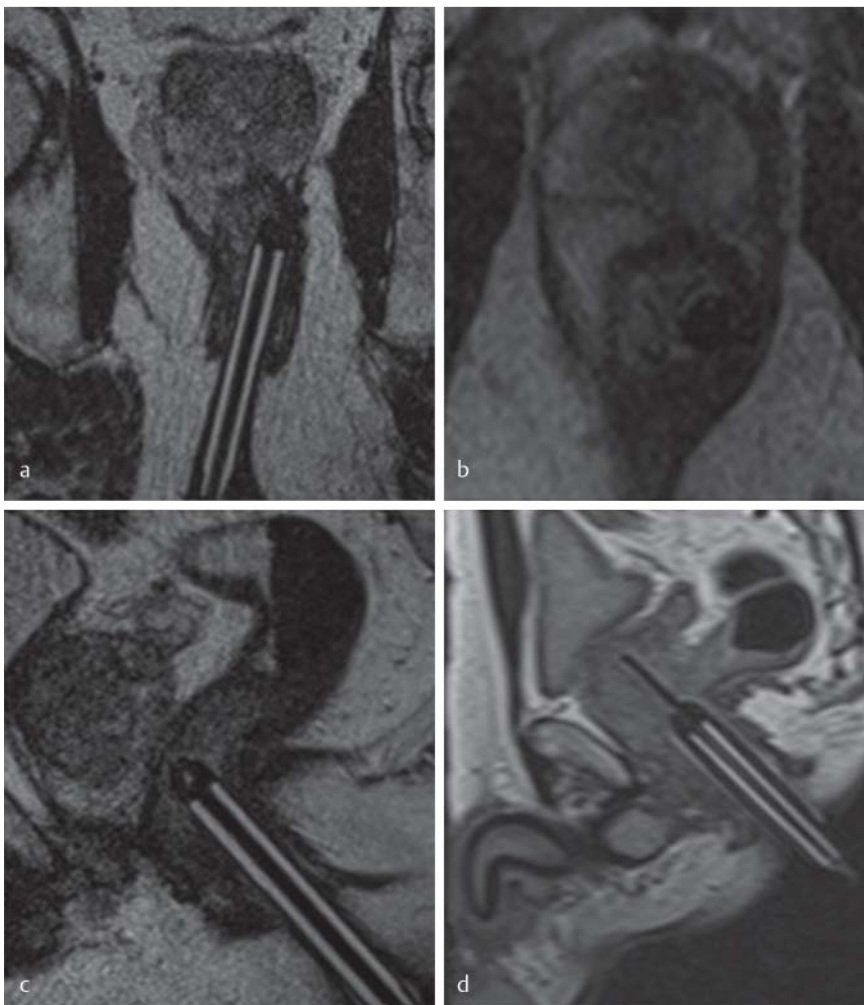


Fig. 2 MRGB of the prostate from the patient shown in **Fig. 1**. **a** Coronal, **b** axial and **c** sagittal T2-weighted images after insertion of the needle guide in the rectum. Pathology confirmed a PCa with a Gleason score of 7 (4 + 3) in the lesion in the peripheral zone. **d** Kontrollscan with the MRI compatible biopsy needle.

Abb. 2 MRGB der Prostata des zuvor gezeigten Patienten (**Abb. 1**). **a** Coronale, **b** axiale und **c** sagittale T2-gewichtete Bilder nach Positionierung der Nadelführung im Rektum. Die Histologie bestätigte ein PCa in der peripheren Zone mit einem Gleason Score von 7 (4 + 3). Kontrollscan mit MRT-kompatibler Biopsienadel.

Table 1 MRGB histopathology results (n = 44).

Benign Histology	33 (74.4%)
Prostatitis	17
Benign Prostate Hyperplasia	4
Benign, not otherwise specified	12
Prostate cancer	11 (25.6%)
– Gleason score 6 (3 + 3)	5
– Gleason score 7 (4 + 3)	4
– Gleason score 8 (4 + 4)	1
– Gleason score 9 (5 + 4)	1

mal treatment decision is beneficial with regards to the cost-utility ratio. [32].

In agreement with the literature, a large proportion of the benign findings in our study was prostatitis which is the most prevalent histopathological diagnosis in patients with negative biopsy specimens. To overcome this limitation, we are currently performing MR imaging scans at 3.0T, taking full advantage of high-resolution and multimodality imaging [31].

Hence, the detection rate for clinically significant cancer in our study is 100%. This is in accordance with and even higher than observed in the review of the literature [12, 14, 15, 18, 19, 29]. This emphasizes the capability of MRGB to diagnose clinically significant cancer in patients after negative TRUS.

Another issue is the patient group with negative MRGB results and benign histology. The most prevalent benign histology in negative biopsy specimens was prostatitis. In fact, the detection rate with MRI is mainly limited by the differentiation of malignant lesions and inflammation. However, it is important to evaluate the cases in which PCa was not detected. Hence, 27 of the patients with benign histology were followed for a median time of 3.1 years, and no new PCa was found during this period. Lane and collaborators reported that cancer was detected in 24% of patients during repeated TRUS for persistent clinical signs of PCa [33]. The rate of missed cancer in MRGB studies is reported at 6% in a paper published by Hoeks et al., with a mean follow-up of only five months [15]. These data are comparable to the results of Engehausen et al. [14]. In the latter study, 10.4% of cancers were missed using MRGB, assuming that these carcinomas were already present at the time of MRI intervention and were not de novo neoplasias [14]. The follow-up period was three years in our study. These results demonstrate that after a negative MRGB, patients have a lower probability of a carcinoma developing during this time interval.

Intervention time is a major concern with MRGB, since the clinical use of this technique is limited by the rather long procedure times involved. The duration of MRGB in a closed system with a transrectal examination at our institution (45 – 55 min) is similar to the duration published in the literature (29 – 76 min) [7, 8, 10, 12, 14 – 16, 28, 29, 34]. Only Zangos et al., 2005, reported a 19-minute procedure in an open low-field system with a transglu-

Table 2 Details of MR-guided biopsy from all included studies (systematic review of the literature and own results).

author	patients	age	PCa	PSA (ng/ml)	examination time	biopsy MR unit	MR imaging unit	way	needle	position	follow-up	rate for PCa detection after MRGB
Bodelle et al. 2013	25	65.7	9	8.3	31 min	1.5 T	3.0 T	Tg	15G	lateral	n/a	0.0 %
Wolter et al. 2013	1	73	1	12.9	n/a	3.0 T	3.0 T	Tp	18G	prone	n/a	0.0 %
Schwab et al. 2012	50	66	25	8.57	n/a	1.5 T and 3.0 T	1.5 T and 3.0 T	Tr	18G	supine	n/a	n/a
Hoeks et al. 2012	265	66.0	108	11.4	44 min	3.0 T	3.0 T	Tr	18G	prone	0.4y	6.0 %
Schouten et al. 2012	13	n/a	3	14.5	76 min	3.0 T	3.0 T	Tr	18G	prone	n/a	n/a
Engelhausen et al. 2012	96	66.2	39	9.4	40 – 60 min	1.0 and 1.5 T	3.0 T	Tr	16G	supine	3.1y	10.4 %
Roetke et al. 2011	100	64.9	52	11.7	n/a	1.5 T	1.5 T	Tr	18G	prone	n/a	n/a
Zangos et al. 2011	20	65.1	3	>4.0	39 min	1.5 T	1.5 T	Tg	15G	prone	n/a	n/a
Franiel et al. 2011	54	68.0	21	12.1	55 min	1.5 T	1.5 T	Tr	18G	prone	n/a	n/a
Hambroek et al. 2011	34	66.0	34	12.0	29 min	3.0 T	3.0 T	Tr	18G	prone	n/a	n/a
Yakar et al. 2011	9	69.0	5	19.5	76.5 min	3.0 T	3.0 T	Tr	18G	prone	n/a	n/a
Hambroek et al. 2010	68	68	40	13.0	30 min	3.0 T	3.0 T	Tr	18G	prone	n/a	n/a
Hambroek et al. 2008	21	62	8	15.0	35 min	1.5 T	1.5 T	Tr	18G	prone	n/a	n/a
Engelhard et al. 2006	37	66.0	14	10.8	120 min	1.5 T	1.5 T	Tr	16G	supine	n/a	n/a
Anastasiadis et al. 2006	27	66.0	15	10.2	n/a	1.5 T	1.5 T	Tr	18G	prone	n/a	n/a
Beyersdorf et al. 2005	12	64	5	10.0	55 min	1.5 T	1.5 T	Tr	16G	prone	n/a	n/a
Zangos et al. 2005	25	61.9	10	11.8	19 min	0.2 T open system	0.2 T open system	Tg	15G	lateral decubi- tus	0.8y	8.0 %
Own results	41	64.7	11	8.3	45 – 55 min	1.5 Tesla	1.5 and 3.0 T	Tr	18G	prone	3.1y	0.0 %

Tr: Transrectal; Tg: Transgluteal; Tp: Transperineal; CSC: Clinically Significant Cancer; PCa: Prostate Cancer; T: Tesla; G: Gauge; y: Years;

teal examination. Applying this latter approach in a closed system, the procedure time required by Zangos and co-workers from the time of patient entry to the biopsy unit until completion was also 39 min, which is comparable to the results of our present study as well as those of previously chronicled examinations [19, 28], albeit a reduction in intervention time has been observed in other studies due to acquired skill and improved efficiency [28]. In addition, needle-guided tracking systems and implementation of robotics may improve these limitations. Comparing the intervention time of MRGB (~45 min) and TRUS (~25), it should be noted that due to the limitation of the longer intervention time, MRGB cannot be recommended as a first-line biopsy method.

As mentioned above, the combination of MRI-guided and robotic-assisted prostate biopsy will be an important and promising technique in the future. The advantage of a robotic device is that the patient does not have to be moved in and out of the MRI scanner during the biopsy session, which decreases the procedure time, enhances patient comfort, and improves needle positioning [26]. The examination methods used for robotic-assisted biopsies

are transgluteal and transrectal, and the intervention time for these methods ranges between 39 min and 76 min [16, 28, 34].

A limitation of our study that should be reported is the inconsistent imaging protocol for the MRI examinations prior to biopsy. The MRI scans were performed on two different imaging devices, i. e., 1.5 T and 3.0 T units, and the examinations were carried out with and without an endorectal coil. However, our principle investigation was to evaluate MRGB and the follow-up of the patient cohort with benign histopathology results and not to accurately stage prostate cancer with multiparametric MRI. Another limitation is that our follow-up protocol was not consistent for each patient. We are aware of these limitations, learned from these retrospective analyses and changed our follow-up protocol accordingly.

In conclusion, our study demonstrates that MRGB is a promising alternative diagnostic tool for clinically significant PCa, which is in accordance with recent literature. More importantly, in the follow-up of our patients with benign biopsy results, no new PCa was detected. Although the probability of developing a PCa after negative MRGB is very low, active surveillance is reasonable.

References

- 1 Siegel R, Naishadham D, Jemal A. Cancer statistics, 2012. *CA Cancer J Clin* 2012; 62: 10–29
- 2 Schroder FH, van der Maas P, Beemsterboer P et al. Evaluation of the digital rectal examination as a screening test for prostate cancer. Rotterdam section of the European Randomized Study of Screening for Prostate Cancer. *J Natl Cancer Inst* 1998; 90: 1817–1823
- 3 Djavan B, Ravery V, Zlotta A et al. Prospective evaluation of prostate cancer detected on biopsies 1, 2, 3 and 4: when should we stop? *J Urol* 2001; 166: 1679–1683
- 4 Lawrentschuk N, Haider MA, Daljeet N et al. „Prostatic evasive anterior tumours“: the role of magnetic resonance imaging. *BJU Int* 2010; 105: 1231–1236
- 5 Yakar D, Hambrock T, Hoeks C et al. Magnetic resonance-guided biopsy of the prostate: feasibility, technique, and clinical applications. *Top Magn Reson Imaging* 2008; 19: 291–295
- 6 Yacoub JH, Verma S, Moulton JS et al. Imaging-guided prostate biopsy: conventional and emerging techniques. *Radiographics* 2012; 32: 819–837
- 7 Anastasiadis AG, Lichy MP, Nagele U et al. MRI-guided biopsy of the prostate increases diagnostic performance in men with elevated or increasing PSA levels after previous negative TRUS biopsies. *Eur Urol* 2006; 50: 738–748 discussion 748–739
- 8 Beyersdorff D, Winkel A, Hamm B et al. MR imaging-guided prostate biopsy with a closed MR unit at 1.5 T: initial results. *Radiology* 2005; 234: 576–581
- 9 Engelhard K, Hollenbach HP, Kiefer B et al. Prostate biopsy in the supine position in a standard 1.5-T scanner under real time MR-imaging control using a MR-compatible endorectal biopsy device. *Eur Radiol* 2006; 16: 1237–1243
- 10 Franiel T, Stephan C, Erbersdobler A et al. Areas suspicious for prostate cancer: MR-guided biopsy in patients with at least one transrectal US-guided biopsy with a negative finding—multiparametric MR imaging for detection and biopsy planning. *Radiology* 2011; 259: 162–172
- 11 Hambrock T, Futterer JJ, Huisman HJ et al. Thirty-two-channel coil 3T magnetic resonance-guided biopsies of prostate tumor suspicious regions identified on multimodality 3T magnetic resonance imaging: technique and feasibility. *Invest Radiol* 2008; 43: 686–694
- 12 Hambrock T, Somford DM, Hoeks C et al. Magnetic resonance imaging guided prostate biopsy in men with repeat negative biopsies and increased prostate specific antigen. *J Urol* 2010; 183: 520–527
- 13 Schwab SA, Kuefner MA, Adamietz B et al. MRI-guided core biopsy of the prostate in the supine position—introduction of a simplified technique using large-bore magnet systems. *European radiology* 2012
- 14 Engehausen DG, Engelhard K, Schwab SA et al. Magnetic resonance image-guided biopsies with a high detection rate of prostate cancer. *ScientificWorldJournal* 2012; 2012: 975971
- 15 Hoeks CM, Schouten MG, Bomers JG et al. Three-Tesla Magnetic Resonance-Guided Prostate Biopsy in Men With Increased Prostate-Specific Antigen and Repeated, Negative, Random, Systematic, Transrectal Ultrasound Biopsies: Detection of Clinically Significant Prostate Cancers. *Eur Urol* 2012
- 16 Schouten MG, Bomers JG, Yakar D et al. Evaluation of a robotic technique for transrectal MRI-guided prostate biopsies. *European radiology* 2012; 22: 476–483
- 17 Bloch BN, Furman-Haran E, Helbich TH et al. Prostate cancer: accurate determination of extracapsular extension with high-spatial-resolution dynamic contrast-enhanced and T2-weighted MR imaging—initial results. *Radiology* 2007; 245: 176–185
- 18 Roethke M, Anastasiadis AG, Lichy M et al. MRI-guided prostate biopsy detects clinically significant cancer: analysis of a cohort of 100 patients after previous negative TRUS biopsy. *World J Urol* 2012; 30: 213–218
- 19 Zangos S, Eichler K, Engelmann K et al. MR-guided transgluteal biopsies with an open low-field system in patients with clinically suspected prostate cancer: technique and preliminary results. *European radiology* 2005; 15: 174–182
- 20 Barentsz JO, Richenberg J, Clements R et al. ESUR prostate MR guidelines 2012. *European radiology* 2012; 22: 746–757
- 21 Rothke M, Blondin D, Schlemmer HP et al. PI-RADS Classification: Structured Reporting for MRI of the Prostate. *Fortschr Röntgenstr* 2013; 185: 253–261
- 22 Epstein JI, Allsbrook WC Jr, Amin MB et al. The 2005 International Society of Urological Pathology (ISUP) Consensus Conference on Gleason Grading of Prostatic Carcinoma. *Am J Surg Pathol* 2005; 29: 1228–1242
- 23 Mazzucchelli R, Barbisan F, Scarpelli M et al. Is incidentally detected prostate cancer in patients undergoing radical cystoprostatectomy clinically significant? *Am J Clin Pathol* 2009; 131: 279–283
- 24 Heijmink SW, van Moerkerk H, Kiemeny LA et al. A comparison of the diagnostic performance of systematic versus ultrasound-guided biopsies of prostate cancer. *European radiology* 2006; 16: 927–938
- 25 Futterer JJ, Verma S, Hambrock T et al. High-risk prostate cancer: value of multi-modality 3T MRI-guided biopsies after previous negative biopsies. *Abdom Imaging* 2012, Oct; 37: 892–896
- 26 Futterer JJ, Barentsz JO. MRI-guided and robotic-assisted prostate biopsy. *Curr Opin Urol* 2012; 22: 316–319
- 27 Hambrock T, Hoeks C, Hulsbergen-van de Kaa C et al. Prospective assessment of prostate cancer aggressiveness using 3-T diffusion-weighted magnetic resonance imaging-guided biopsies versus a systematic 10-core transrectal ultrasound prostate biopsy cohort. *Eur Urol* 2012; 61: 177–184
- 28 Zangos S, Melzer A, Eichler K et al. MR-compatible assistance system for biopsy in a high-field-strength system: initial results in patients with suspicious prostate lesions. *Radiology* 2011; 259: 903–910
- 29 Bodelle B, Naguib NN, Schulz B et al. 1.5-T Magnetic Resonance-Guided Transgluteal Biopsies of the Prostate in Patients With Clinically Suspected Prostate Cancer: Technique and Feasibility. *Invest Radiol* 2013; 48: 458–463
- 30 Wolter K, Decker G, Willinek WA. Transperineal MR-Guided Stereotactic Prostate Biopsy Utilizing a Commercially Available Anorectal Biopsy Device. *Fortschr Röntgenstr* 2013; 185: 116–120
- 31 Schlemmer HP. Multiparametric MRI of the prostate: method for early detection of prostate cancer? *Fortschr Röntgenstr* 2010; 182: 1067–1075
- 32 Stadlbauer A, Bernt R, Salomonowitz E et al. Health-economic evaluation of magnetic resonance imaging before biopsy for diagnosis of prostate cancer. *Fortschr Röntgenstr* 2011; 183: 925–932
- 33 Lane BR, Zippe CD, Abouassaly R et al. Saturation technique does not decrease cancer detection during followup after initial prostate biopsy. *J Urol* 2008; 179: 1746–1750 discussion 1750
- 34 Yakar D, Schouten MG, Bosboom DG et al. Feasibility of a pneumatically actuated MR-compatible robot for transrectal prostate biopsy guidance. *Radiology* 2011; 260: 241–247