

Technique: Osteochondral Grafting of Capitate Chondrosis in PRC

Peter Tang, MD, MPH¹ Joseph E. Imbriglia, MD^{2,3}

¹ Allegheny Health Network, Pittsburgh, Pennsylvania

² Department of Orthopaedic Surgery, University of Pittsburgh School of Medicine, Pittsburgh, Pennsylvania

³ Western Pennsylvania Hand and UpperEx Center, Wexford, Pennsylvania

Address for correspondence Peter Tang, MD, MPH, Hand, Upper Extremity, and Microvascular Fellowship, Allegheny Health Network, 1307 Federal St., 2nd Floor, Pittsburgh, PA 15212 (e-mail: ptang@wpahs.org).

J Wrist Surg 2013;2:206–211.

Abstract

Background Proximal row carpectomy (PRC) is a useful treatment option for wrist arthritis, but the operation is contraindicated when there is arthritis of the capitate head. We describe a technique that involves resurfacing of a capitate that has focal chondrosis, using an osteochondral graft harvested from the resected carpal bones.

Materials and Methods PRC patients who had a focal area of capitate chondrosis underwent osteochondral grafting of the capitate. Pre- and postoperative pain level, employment status, motion, grip strength, and Modified Mayo Wrist Scores (MMWS) were assessed. Postoperative Disability of the Arm, Shoulder, and Hand (DASH) scores were also calculated.

Description of Technique The articular surface of the capitate is assessed for need for grafting. The proximal row is resected with the lunate removed intact. The arthritic area is prepared. The graft is taken from the lunate and placed in the prepared site of the capitate.

Results Eight patients (average age of 53 years) were followed for 18 months. Pain: Preoperatively, moderate to severe in 7 patients; postoperatively, mild to no pain in 7 patients. Motion: Preoperative, 84° (74% of the contralateral side); postoperative 75° (66%). Grip Strength: Preoperative, 29 kg (62%); postoperative, 34 kg (71%). Mayo Wrist Score: Preoperative, 51 (poor); postoperative, 68 (fair). Average postoperative DASH score was 19.5. Follow-up radiographs showed that 75% of patients had mild to no degeneration.

Conclusions Osteochondral grafting in PRC offers satisfactory results in terms of pain relief, return to work, motion, and grip strength.

Level of Evidence Therapeutic IV, Case series

Keywords

- ▶ osteochondral graft
- ▶ proximal row carpectomy

Proximal row carpectomy (PRC) has been shown in multiple studies to be an effective motion-preserving procedure for wrist arthritis. The operation consists of resection of the scaphoid, lunate, and triquetrum.¹ The proximal capitate and lunate fossa of the radius form the new wrist articulation, which makes the ideal patient free of degenerative changes at those articular surfaces.^{2–8} Various authors, as well as the senior author, have maintained that when there is mild

degeneration of these articular surfaces, PRC can still provide good to excellent results.^{2–6,9}

However, as wrist arthritis progresses, as in stage III scapholunate advanced collapse (SLAC) wrist or stage II/III scaphoid nonunion advanced collapse (SNAC) wrist, the proximal capitate becomes arthritic. With advanced degeneration, alternative surgical procedures include scaphoid excision, four-bone fusion, and wrist fusion. However, there

may be reasons to favor a PRC despite capitate arthritis, including a shorter surgical time (poor patient health status), shorter immobilization time (patient with baseline difficulties with activities of daily living), increased wrist motion (vocational or sport need), and lack of need to achieve bony union (patient may have risk factors for nonunion such as smoking). Imbriglia et al documented that a significant remodeling of the radiocapitate interface occurs following the standard PRC, which produces a “hinge-and-roll” rather than a ball-and-socket motion.⁴ In an effort to provide a broader interface to distribute radiocarpal compressive forces more evenly, Salomon and Eaton recommended resecting the proximal capitate regardless of arthritis or pristine cartilage, with or without placement of a capsular interposition.¹⁰ Their approach obviated any regard for the status of the capitate cartilage. Our approach respects cartilage and seeks to improve the status of the capitate cartilage if there is a focal defect.

There are few reports in the literature of this type of approach. Salon and Hémon described using an osteochondral graft from resected carpal bones in two cases of Kienböck disease; these grafts were used to resurface areas of chondral damage over the capitate and the lunate fossa of the radius.¹¹ Langer et al described an osteochondral transfer of a scaphoid segment into the lunate fossa in PRC in two patients with stage IV of Kienböck disease.¹²

Our technique expands the indications for a PRC. In this paper we describe the technique and review the outcomes we have previously published.¹³

Patients and Methods

Between 2004 and 2005, the articular surface of the capitate was evaluated in all patients having a PRC. Prior to surgery, informed consent was obtained for each patient to include possible osteochondral grafting. The status of the capitate articular cartilage was graded using a modified Outerbridge classification: grade I: softening of the articular cartilage; II: fibrillation or superficial fissures of the cartilage; III: deep fissuring of the cartilage without exposed bone; IV: exposed bone. Patients with grade II to IV chondrosis that was less than 10 mm in diameter were enrolled in the study and underwent capitate resurfacing with osteochondral grafts. The location, grade of chondrosis, and size in both the volardorsal direction and the radioulnar direction were recorded, and the location of the graft harvest was noted.

We recorded the age, sex, dominance, operative side, and previous surgeries. Preoperative pain level (none, mild, moderate, severe), work status (regular employment, restricted, able to work but unemployed, unable), motion, and grip strength (using a Jamar dynamometer set at III and adjusted for dominance assuming the dominant extremity is 10% stronger than the nondominant extremity)¹⁴ were obtained from clinic notes and patient interviews. Postoperative data including pain level, work status, motion, grip strength, and Disability of the Arm, Shoulder and Hand scores (DASH; 100 being the worst and 0 being the best possible score)¹⁵ were obtained at postoperative office visits or physical therapy

visits. With the available data, pre- and postoperative Modified Mayo Wrist Scores (MMWS) were calculated (excellent, 90–100 points; good, 80–90; fair, 65–80, and poor, less than 65).¹⁶ A Student's *t*-test was used to compare the pre- and postoperative pain level, work status, motion, grip strength, and MMWS. Pre- and postoperative radiographs were evaluated for degenerative changes of the lunate fossa using the classification proposed by Culp.⁵ Degenerative joint disease was rated mild if there was only a decreased joint space, moderate if there was a decreased joint space with adjacent subchondral sclerosis, and severe if there was collapse and cyst formation. The radiographic degeneration and functional outcome was compared using analysis of variance with η^2 to evaluate the relationship between the radiographic findings and continuous variables of function (i.e., wrist motion, grip strength, MMWS). For categorical variables (i.e., pain level and work status), Cramér's V correlation coefficient was used.

Eight patients (seven male, one female) with an average age of 53 years (range: 39–67 years) were enrolled in the study. The average follow-up was 18 months (range: 8–25 months). The dominant extremity was involved in six patients. Half the patients were diagnosed with SLAC wrist (two with stage II and two with stage III), and the rest had the diagnosis of SNAC wrist (three with stage III and one with stage IV). Five patients were laborers (a roofer, a welder, a power company lineman, a maintenance supervisor, and a body shop manager), while the others included an administrator, a business owner, and a retired secretary.

Three of the six patients with SNAC wrist had a prior open reduction and internal fixation (ORIF). One of these three patients had two other surgeries prior to the PRC procedure. These included a carpal tunnel release, a radial styloidectomy, and a concomitant first dorsal compartment release for de Quervain syndrome. During our index procedure, one patient had a carpal tunnel release and another had a dorsal wrist ganglion excision.

Surgical Technique

A longitudinal incision is made just ulnar to the Lister tubercle. The interval between the third and fourth compartments is opened and the tendons retracted. A longitudinal incision is made in the joint capsule, and the capsule is elevated radially and ulnarly, exposing the proximal and distal carpal rows. The articular surfaces of the proximal capitate and lunate fossa of the radius are inspected for degenerative changes. If the area of chondrosis of the capitate is grade II to IV and the size is less than 10 mm, osteochondral grafting can be considered (► **Fig. 1**). As a general guideline we prefer to resurface with a single graft that is less than 10 mm in diameter for concerns of fracture of the capitate if the grafting is more than 10 mm.

If grafting is to be performed, the next step is a proximal row resection. Because the scaphoid is generally the most arthritic, and therefore a poor source of an osteochondral graft, the scaphoid is mobilized, osteotomized into smaller pieces, and excised. Care is taken to preserve the radio-scaphocapitate and radiolunotriquetral volar ligaments. The lunate is usually the least affected in terms of degeneration

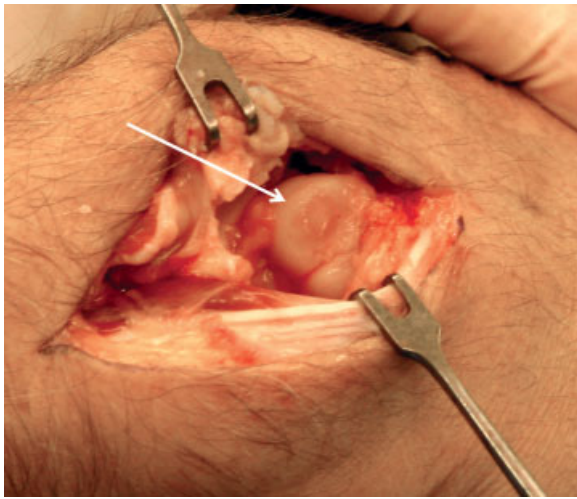


Fig. 1 Chondrosis (arrow) found on capitate after PRC.

and will most likely serve as the osteochondral graft source. Thus, this bone is removed intact. The triquetrum is also removed intact, in case the graft needs to be harvested from it. After the carpal bone resection, the wrist motion is checked to rule out impingement with radial deviation. If necessary, a radial styloidectomy is performed.

At this point, the site of capitate chondrosis is prepared. A sizer from the Osteochondral Autograft Transfer System (OATS[®] Arthrex, Inc, Naples, Florida) is used to determine the size of the graft that will be needed. A 2.4-mm guide pin is drilled into the center of the site of chondrosis, perpendicular to the articular surface. Then, the appropriately sized cannulated headed reamer is drilled over the top of the guide pin to the depth of 10.0 mm (►Fig. 2). An alignment rod is used to tap the bed of the recipient site and can be used as a guide to the direction of graft placement. The resected carpal bones are evaluated for the most pristine articular cartilage, where an appropriately sized graft can be harvested. Using a donor harvester, the graft is obtained from the stabilized carpal bone on a sterile back table. The harvester is tapped with a

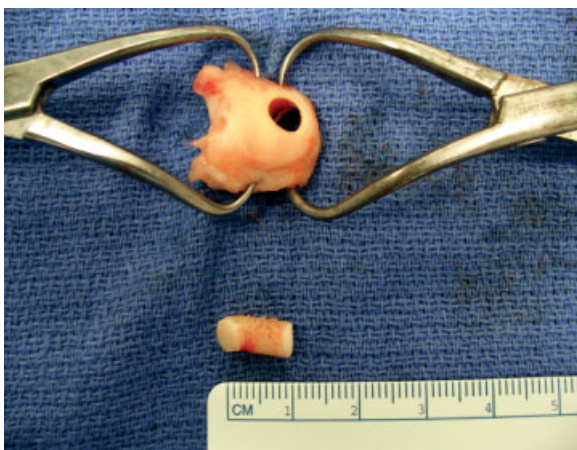


Fig. 3 Osteochondral graft pictured next to lunate from which it was removed.

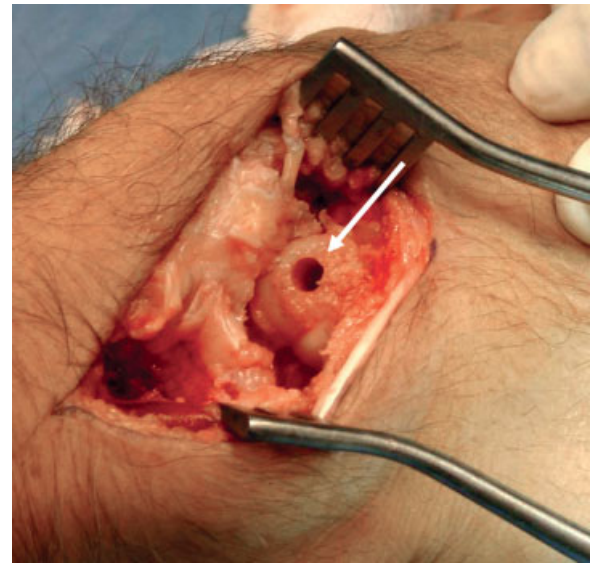


Fig. 2 Prepared capitate. Arrow pointing to area of resected chondrosis.

mallet through the whole carpal bone. Then, using the push pin puncher, the graft is backed out of the harvester so that 10.0 mm of graft remains in the harvester. The excess is rongeuired to an even edge (►Fig. 3). The graft is then inserted into the capitate using the alignment rod as a guide to direction. Gentle taps, to prevent chondrocyte damage, are used to place the articular surface of the graft flush with the surrounding cartilage (►Fig. 4).

A capsular closure is performed with interrupted 3-0 nonabsorbable sutures. The retinaculum is closed, followed by skin closure and application of a wrist splint. The sutures are removed at 2 weeks postoperative, and occupational therapy is started. Patients are told before surgery that it will take 4 to 6 months before there is pain-free range of motion.

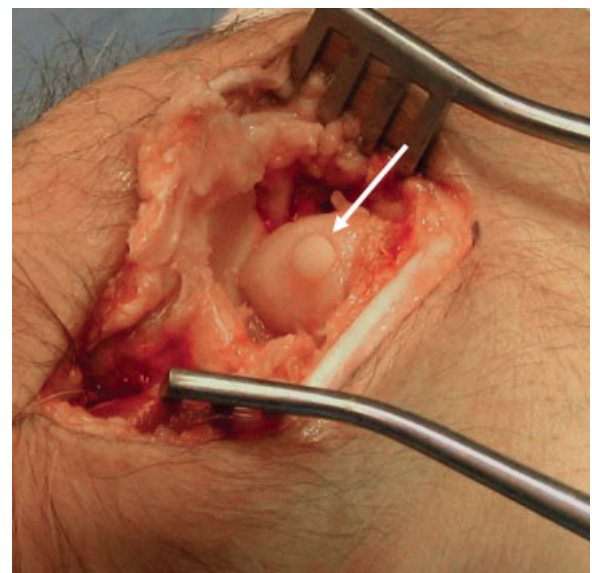


Fig. 4 Capitate after osteochondral graft (arrow) placement.

Results

Surgical Findings

On intraoperative examination, two patients had grade II chondrosis (fibrillation), four patients had grade III (deep fissuring without exposed bone), and two had grade IV (exposed bone). All defects measured 5.0×5.0 mm, except in two patients whose defects measured 10.0 (radioulnar direction) \times 6.0 (volar/dorsal) mm and 5.0×6.0 mm. All grafts in the study were 10 mm long and 6 mm in diameter, even in the two patients with the largest defects. Because of the irregular nature (not perfectly oval or circular) of the chondrosis and the fact that the measurements were of the maximum diameter of the chondrosis and did not necessarily represent the average size of the lesion, the operating surgeon believed that a 5 mm diameter graft best resurfaced these areas. Seven of the eight osteochondral grafts were harvested from the lunate, except for one case in which the graft was harvested from the triquetrum.

Pain Level

Preoperatively, one patient responded that the pain was mild, two patients responded moderate, and five responded severe. Postoperatively, four patients reported no pain, three reported mild pain, and one reported moderate pain.

Employment Status

Preoperatively, one patient reported inability to work, two reported restricted employment, and five reported regular employment. Postoperatively, two patients reported restricted employment and six reported regular employment.

Range of Motion

Preoperatively, the total arc of motion of the wrist was 84° (74% of the contralateral side) with an average extension of 34° , and an average flexion of 50° . Postoperatively, the total arc of motion was 75° (66% of the contralateral side) with an average extension of 37° , and average flexion of 38° .

Grip Strength

Preoperatively, the average grip strength was 29 kg, or 62% of the contralateral extremity adjusted for dominance. Postoperatively, the grip strength increased to 34 kg, or 71% (73% when not adjusted for dominance) of the contralateral side, which was not a significant change ($p > 0.05$).

Modified Mayo Wrist Score and DASH Score

The preoperative MMWS was 51, which corresponds to a poor score, while postoperatively the score significantly increased to 68, which is rated as fair. Three patients improved from poor to fair, and one improved from poor to good. Two fair patients were unchanged. Only postoperative DASH scores were available, and the patients scored an average of 19.5 (range, 0.8–46.7).

Radiographic and Imaging Evaluation

The radiographs were evaluated pre- and postoperatively. On follow-up evaluation, two patients had no arthritis of the

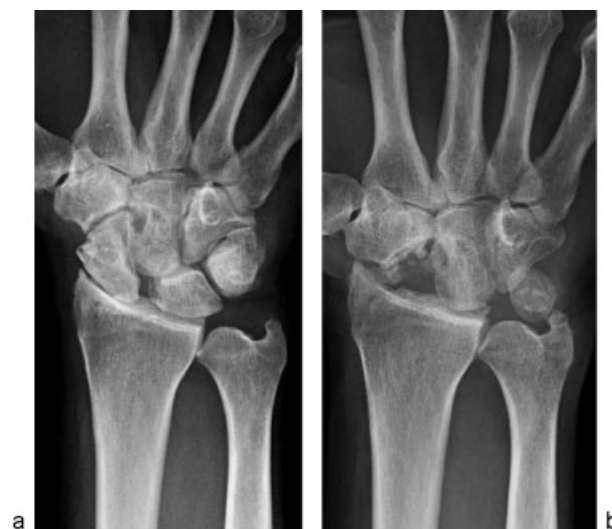

Fig. 5 (a) Posteroanterior (PA) preoperative X-ray of a patient with SLAC wrist. (b) PA X-ray image 23.3 months postoperative after osteochondral grafting in PRC of the patient in **Fig. 5a**. This patient's degeneration was graded as none.

lunate fossa or proximal capitate, four had mild degeneration (decreased joint space alone), and two had severe degeneration (collapse and cyst formation) (**Figs. 5a, b; 6a, b**). Radiographic degeneration did not correlate with the pain level, work status, motion, grip strength, or wrist score. One postoperative magnetic resonance image (MRI) at 21.3 months showed bone incorporation of the graft and the presence of a viable cartilage graft (**Fig. 7a, b**).

Complications

No complications were encountered in this series of patients. No patients required further surgery.

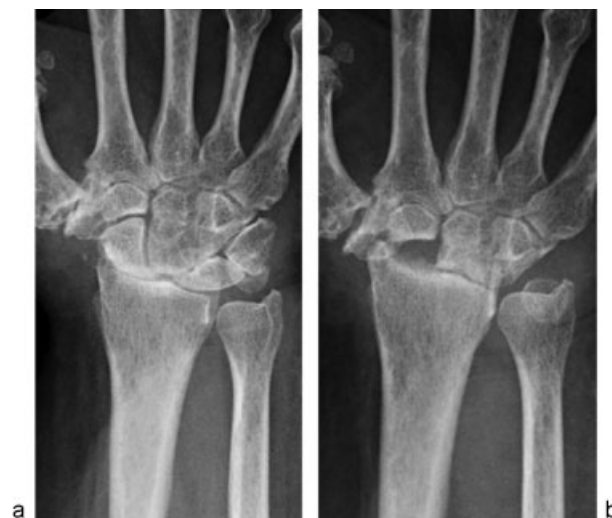

Fig. 6 (a) PA preoperative X-ray image of a patient with SLAC wrist, different from the patient in **Fig. 5a, b**. (b) PA X-ray image 11.0 months postoperative for the patient in **Fig. 6a**. This patient's degeneration was graded as severe.

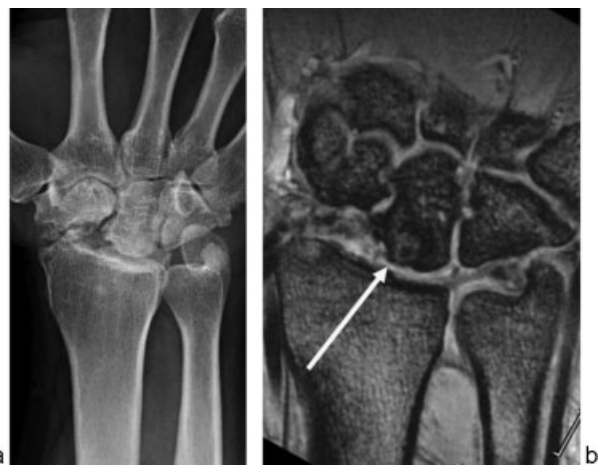

Fig. 7 (a) PA X-ray image 21.3 months postoperative. This patient's degeneration was graded as mild. (b) Postoperative MRI at 21.3 months from surgery for the patient in ▶**Fig. 7a** reveals graft incorporation. Arrow indicates graft location.

Discussion

In the past there were concerns about the success of a proximal row carpectomy,^{8,17} but multiple studies have proven it to be a dependable, motion-preserving procedure that improves pain and grip strength.^{4–7,18} Ideally, the proximal capitate should be free of degenerative changes,^{2–7} which is not the case in stage III SLAC or stage II/III SNAC wrist. The lunate fossa usually remains free of degeneration, as the lunate/lunate fossa articulation is spherical, so abnormal carpal postures (dorsal intercalated segment instability [DISI] or volar intercalated segment instability [VISI]) does not lead to increased contact pressure or decreased contact area even in the “pan-arthritis” stage IV SLAC/SNAC. In these cases, a wrist arthrodesis is an option, but there is certain disability with wrist fusion. Scaphoid excision combined with a four-bone fusion is an alternative motion-preserving treatment. However, the surgeon may have reasons to recommend a PRC: greater wrist motion,^{18–20} shorter surgical time, shorter postoperative immobilization, and lack of the need to achieve bony union.

Good to excellent results are thought to be possible following a PRC when there is mild articular degeneration of the capitate.^{2–6,9} It is unclear what the critical amount of arthritis is to preclude a good result. Tomaino said it best: “We are unable to define more precisely than others when pre-existing arthrosis represents an absolute contraindication to proximal row carpectomy. Recommendations in the literature have been anecdotal and ambiguous.”²¹

Salomon and Eaton reviewed 12 patients who had undergone PRC with partial resection of the capitate.¹⁰ Ten patients had degenerative arthritis secondary to SLAC deformity or chronic scaphoid nonunion. Seven of these patients had significant lunocapitate, and three had radiolunate, degenerative disease. An additional two patients underwent an immediate modified proximal carpectomy for acute complex radiocarpal trauma. At a follow-up evaluation of 55 months (range 19–122 months), seven patients reported no pain and four patients had only occasional pain with strenuous activi-

ty. The grip strength improved from 19 to 26 kg following surgery. The four patients having dorsal capsule interposition achieved an average extension/flexion arc of 111° (range, 95–176°), the fascial interposition patients achieved an arc of 88° (range, 55–176°) and the single patient treated with distraction achieved 90°. Three patients had partial capitate resection but no interposition or distraction and achieved an 80° of total extension/flexion arc. Because of the capitate resection, radiographic changes of degeneration could not be evaluated.

Our technique enables the surgeon to improve the status of the capitate cartilage. Osteochondral grafting has been successfully used in treating osteochondritis dissecans of the knee.²² This technique “restores architecturally appropriate, mature hyaline cartilage in acquired articular cartilage defects.”²³ In multiple studies including rabbit, ovine, and porcine models, chondrocytes and osteocytes of the osteochondral graft have been shown to survive transplantation.^{24–30}

Osteochondral grafting has also been used in the capitulum, talus, and femoral head, with graft viability proven with second-look arthroscopy, MRI, and biopsy.^{31–37} The MRI of our patient at 21 months postoperative showed bone incorporation of the graft to the capitate and the presence of graft cartilage (▶**Fig. 7b**). Weaknesses of the study include only one patient undergoing a MRI and no patients having a secondary procedure where graft viability could be assessed. Other weaknesses of this study are the lack of a control group and the short follow-up period. Although good outcomes were achieved in six patients, two patients developed severe capitulum degeneration in the relatively short follow-up period.

In the fingers and wrist, autogenous osteochondral grafts have also been harvested from the carpometacarpal (CMC) joint, toe, hamate, and ribs for multiple conditions including fracture-dislocation, trauma, and failed trapeziectomy in thumb CMC arthritis.^{38–42} Sandow advocated costo-osteochondral (rib bone/cartilage autograft) replacement for the proximal scaphoid.⁴³ Furthermore, the distal fibula has been used to reconstruct the distal radius after giant cell tumor resection.⁴⁴ Lastly, osteoarticular grafts from the proximal tibiofibular joint have been used to reconstruct the scaphoid and lunate facets in severe distal radius fractures.⁴⁵

Our technique has several advantages including the lack of donor site morbidity since the grafts are harvested from resected carpal bones. There is usually sufficient healthy cartilage to allow graft harvest since the radiolunate joint is preserved even in advanced SLAC and SNAC wrist. Furthermore, there is no risk of disease transmission or transplant rejection because autogenous tissue is used. Since the autogenous transplantation is immediate, there is no risk of chondrocyte death due to storage. Lastly, the costs are lower since the procedure was performed in a single stage.³³

Acknowledgments

We would like to thank Dr. James J. Irrgang, Director for Clinical Research in the Department of Orthopaedic Surgery at the University of Pittsburgh School of Medicine, for performing the statistical calculations in this study.

We would also like to thank Arthrex, Inc. for donating the instrumentation for this study.

Conflict of Interest

None

References

- 1 Green DP. Proximal row carpectomy. *Hand Clin* 1987;3(1):163–168
- 2 Crabbe WA. Excision of the proximal row of the carpus. *J Bone Joint Surg Br* 1964;46:708–711
- 3 Inglis AE, Jones EC. Proximal-row carpectomy for diseases of the proximal row. *J Bone Joint Surg Am* 1977;59(4):460–463
- 4 Imbriglia JE, Broudy AS, Hagberg WC, McKernan D. Proximal row carpectomy: clinical evaluation. *J Hand Surg Am* 1990;15(3):426–430
- 5 Culp RW, McGuigan FX, Turner MA, Lichtman DM, Osterman AL, McCarroll HR. Proximal row carpectomy: a multicenter study. *J Hand Surg Am* 1993;18(1):19–25
- 6 Jebson PJJ, Hayes EP, Engber WD. Proximal row carpectomy: a minimum 10-year follow-up study. *J Hand Surg Am* 2003;28(4):561–569
- 7 DiDonna ML, Kiefhaber TR, Stern PJ. Proximal row carpectomy: study with a minimum of ten years of follow-up. *J Bone Joint Surg Am* 2004;86-A(11):2359–2365
- 8 Neviaser RJ. Proximal row carpectomy for posttraumatic disorders of the carpus. *J Hand Surg Am* 1983;8(3):301–305
- 9 Neviaser RJ. On resection of the proximal carpal row. *Clin Orthop Relat Res* 1986;202(202):12–15
- 10 Salomon GD, Eaton RG. Proximal row carpectomy with partial capitate resection. *J Hand Surg Am* 1996;21(1):2–8
- 11 Salon A, Hémon C. Conservative surgery in Kienböck disease with perilunate arthrosis: articular resurfacing using resected carpal bones [in French]. *Chir Main* 2003;22(3):154–157
- 12 Langer MF, Wieskötter B, Vordemvenne T, Surke C. Osteochondral reconstruction of the lunate fossa in proximal row carpectomy for Kienböck's disease early stage IV [in German]. *Handchir Mikrochir Plast Chir* 2010;42(3):212–215
- 13 Tang P, Imbriglia JE. Osteochondral resurfacing (OCRPRC) for capitate chondrosis in proximal row carpectomy. *J Hand Surg Am* 2007;32(9):1334–1342
- 14 Thorngren KG, Werner CO. Normal grip strength. *Acta Orthop Scand* 1979;50(3):255–259
- 15 Hudak PL, Amadio PE, Bombardier C; The Upper Extremity Collaborative Group (UECG). Development of an upper extremity outcome measure: the DASH (disabilities of the arm, shoulder and hand) [corrected]. *Am J Ind Med* 1996;29(6):602–608
- 16 Cooney WP, Bussey R, Dobyns JH, Linscheid RL. Difficult wrist fractures. Perilunate fracture-dislocations of the wrist. *Clin Orthop Relat Res* 1987;214(214):136–147
- 17 Harris WH, Jones WN, Aufranc OE. Problem Cases from Fracture Grand Rounds at the Massachusetts General Hospital. St. Louis, MO: Mosby; 1965:291
- 18 Tomaino MM, Miller RJ, Cole I, Burton RI. Scapholunate advanced collapse wrist: proximal row carpectomy or limited wrist arthrodesis with scaphoid excision? *J Hand Surg Am* 1994;19(1):134–142
- 19 Cohen MS, Kozin SH. Degenerative arthritis of the wrist: proximal row carpectomy versus scaphoid excision and four-corner arthrodesis. *J Hand Surg Am* 2001;26(1):94–104
- 20 Wyrick JD, Stern PJ, Kiefhaber TR. Motion-preserving procedures in the treatment of scapholunate advanced collapse wrist: proximal row carpectomy versus four-corner arthrodesis. *J Hand Surg Am* 1995;20(6):965–970
- 21 Tomaino MM, Delsignore J, Burton RI. Long-term results following proximal row carpectomy. *J Hand Surg Am* 1994;19(4):694–703
- 22 Yamashita F, Sakakida K, Suzu F, Takai S. The transplantation of an autogeneic osteochondral fragment for osteochondritis dissecans of the knee. *Clin Orthop Relat Res* 1985;201(201):43–50
- 23 Görtz S, Bugbee WD. Allografts in articular cartilage repair. *J Bone Joint Surg Am* 2006;88(6):1374–1384
- 24 Lane JM, Brighton CT, Ottens HR, Lipton M. Joint resurfacing in the rabbit using an autologous osteochondral graft. *J Bone Joint Surg Am* 1977;59(2):218–222
- 25 Lane JG, Tontz WL Jr, Ball ST, et al. A morphologic, biochemical, and biomechanical assessment of short-term effects of osteochondral autograft plug transfer in an animal model. *Arthroscopy* 2001;17(8):856–863
- 26 Siebert CH, Miltner O, Weber M, Sopka S, Koch S, Niedhart C. Healing of osteochondral grafts in an ovine model under the influence of bFGF. *Arthroscopy* 2003;19(2):182–187
- 27 Nam EK, Makhosous M, Koh J, Bowen M, Nuber G, Zhang LQ. Biomechanical and histological evaluation of osteochondral transplantation in a rabbit model. *Am J Sports Med* 2004;32(2):308–316
- 28 Burks RT, Greis PE, Arnoczky SP, Scher C. The use of a single osteochondral autograft plug in the treatment of a large osteochondral lesion in the femoral condyle: an experimental study in sheep. *Am J Sports Med* 2006;34(2):247–255
- 29 Harman BD, Weeden SH, Lichota DK, Brindley GW. Osteochondral autograft transplantation in the porcine knee. *Am J Sports Med* 2006;34(6):913–918
- 30 Nakaji N, Fujioka H, Nagura I, et al. The structural properties of an osteochondral cylinder graft-recipient construct on autologous osteochondral transplantation. *Arthroscopy* 2006;22(4):422–427
- 31 Bradley JP, Petrie RS. Osteochondritis dissecans of the humeral capitellum. Diagnosis and treatment. *Clin Sports Med* 2001;20(3):565–590
- 32 Tsuda E, Ishibashi Y, Sato H, Yamamoto Y, Toh S. Osteochondral autograft transplantation for osteochondritis dissecans of the capitellum in nonthrowing athletes. *Arthroscopy* 2005;21(10):1270
- 33 Lee CH, Chao KH, Huang GS, Wu SS. Osteochondral autografts for osteochondritis dissecans of the talus. *Foot Ankle Int* 2003;24(11):815–822
- 34 Hangody L, Füles P. Autologous osteochondral mosaicplasty for the treatment of full-thickness defects of weight-bearing joints: ten years of experimental and clinical experience. *J Bone Joint Surg Am* 2003;85-A(Suppl 2):25–32
- 35 Alford JW, Cole BJ. Cartilage restoration, part 1: basic science, historical perspective, patient evaluation, and treatment options. *Am J Sports Med* 2005;33(2):295–306
- 36 Alford JW, Cole BJ. Cartilage restoration, part 2: techniques, outcomes, and future directions. *Am J Sports Med* 2005;33(3):443–460
- 37 Barber FA, Chow JC. Arthroscopic osteochondral transplantation: histologic results. *Arthroscopy* 2001;17(8):832–835
- 38 Ishida O, Ikuta Y, Kuroki H. Ipsilateral osteochondral grafting for finger joint repair. *J Hand Surg Am* 1994;19(3):372–377
- 39 Boulas HJ. Autograft replacement of small joint defects in the hand. *Clin Orthop Relat Res* 1996;327(327):63–71
- 40 Gaul JS Jr. Articular fractures of the proximal interphalangeal joint with missing elements: repair with partial toe joint osteochondral autografts. *J Hand Surg Am* 1999;24(1):78–85
- 41 Williams RM, Kiefhaber TR, Sommerkamp TG, Stern PJ. Treatment of unstable dorsal proximal interphalangeal fracture/dislocations using a hemi-hamate autograft. *J Hand Surg Am* 2003;28(5):856–865
- 42 Glard Y, Gay A, Valenti D, Berwald C, Guinard D, Legre R. Costochondral autograft as a salvage procedure after failed trapeziectomy in trapeziometacarpal osteoarthritis. *J Hand Surg Am* 2006;31(9):1461–1467 PubMed
- 43 Sandow MJ. Proximal scaphoid costo-osteochondral replacement arthroplasty. *J Hand Surg Br* 1998;23(2):201–208
- 44 Lackman RD, McDonald DJ, Beckenbaugh RD, Sim FH. Fibular reconstruction for giant cell tumor of the distal radius. *Clin Orthop Relat Res* 1987;218(218):232–238
- 45 Mehin R, Giachino AA, Backman D, Grabowski J, Fazekas A. Autologous osteoarticular transfer from the proximal tibiofibular joint to the scaphoid and lunate facets in the treatment of severe distal radial fractures: a report of two cases. *J Hand Surg Am* 2003;28(2):332–341 PubMed