

The Acutely Comatose Patient: Clinical Approach and Diagnosis

S. Arthur Moore, MD¹ Eelco F. Wijdicks, MD, PhD¹

¹Department of Neurology, Mayo Clinic, Rochester, Minnesota

Semin Neurol 2013;33:110–120.

Address for correspondence Eelco F. Wijdicks, MD, PhD, Department of Neurology, Mayo Clinic, Rochester, MN 55905 (e-mail: wijde@mayo.edu).

Abstract

A patient's acute and persistent unresponsiveness in the emergency department often triggers a neurology consultation. Given the many potential causes of unresponsiveness, the initial objective of the neurologist should be a comprehensive history and physical examination, which should allow localization of the lesion, if possible, and an initial narrowing of the differential diagnosis. In addition, neuroimaging review and laboratory evaluation have come to play an increasingly important role in identification of the potential causes of unresponsiveness. However, in some instances, the computed tomography or the magnetic resonance imaging scans are normal and sorting out the cause and depth of unresponsiveness requires clinical skill. The neurologist is adept at correctly moving through a differential diagnosis and this has a profound effect on management. Once appropriate treatment has been initiated, the outcome can be assessed. Recovery from coma can be prolonged, but is less likely if early involvement of the brainstem is apparent.

Keywords

- ▶ unresponsiveness
- ▶ coma
- ▶ FOUR score
- ▶ emergency neurology

A significant injury or dysfunction of the brain is needed to produce unresponsiveness. The top three causes of coma outside the hospital remain intoxication (including illicit and legal drugs), diabetic dysregulation, and traumatic head injury. The distribution of causes of unresponsiveness, however, is different in the emergency department, the critical care unit, the surgical recovery room, or the general hospital ward. In general, the management priority in any case of unresponsiveness should be to prevent a treatable cause of coma from leading to a permanent injury.

Within the emergency department, the approach to coma is to stabilize (more than airway, breathing, circulation [ABCs]), to diagnose (more than the Glasgow Coma Scale), to manage (more than intravenous glucose and antidotes), and to critically assess information one step at a time (more than an algorithm).

Defining the State of Consciousness

Consciousness is typically defined as the presence of arousal, in which one is able to interact with the environment, and awareness, with the ability to know “what is going on.”¹

Traditionally, consciousness has been divided into content and level of arousal with its disconnect “wakeful unresponsiveness.” Coma is by definition a complete loss of both awareness and arousal (similar to general anesthesia). Clinicians have long struggled with defining unconsciousness, but over the years, different categories have emerged. These categories may need redefinition as a result of functional magnetic resonance imaging (fMRI) data. What seems incontrovertibly true is that prolonged unconsciousness is very rare. Awakening may not mean registering events and a certain point of no return exists beyond which the patient will not likely awaken. A significant reduction in both awareness and arousal can be seen in a minimally conscious state. The various disorders of consciousness as well as mimickers of coma are presented in ▶ **Table 1**.

The History

In all cases of acute unresponsiveness, the process of identifying the underlying etiology begins with a comprehensive history after the patient has been stabilized. There can be major impediments to this. The history is often convoluted, family members are often not present, and if they are, they

Issue Theme Acute Coma and Disorders of Consciousness; Guest Editors, Hans A. Püttgen, MD, and Romergryko G. Geocadin, MD

Copyright © 2013 by Thieme Medical Publishers, Inc., 333 Seventh Avenue, New York, NY 10001, USA.
Tel: +1(212) 584-4662.

DOI <http://dx.doi.org/10.1055/s-0033-1348963>.
ISSN 0271-8235.

Table 1 Disorders of consciousness and mimickers

State	Arousal	Awareness	Description
Coma	Absent	Absent	No response to noxious stimuli other than reflexic, such as extensor or flexor posturing
Persistent vegetative state ^{2,3}	Preserved	Absent	Transitioning from coma to prolonged coma, eyes may be open, especially during the day; roving eye movements; no sustained, reproducible response to stimuli; stable autonomic functions
Minimally conscious state ⁴	Present, but minimal	Present, but minimal	May make eye contact or track visual stimuli; abulic, emotionless; may mouth words or fend off pain; may hold or use an object when asked
Delirium	Altered, but not absent or diminished	Altered, but not absent or diminished	Rapidly fluctuating mental status; frequent findings include disorientation, misperception of sensory stimuli including hallucinations
Akinetic mutism	Appears intact	Absent	Lack of spontaneous motor activity
Locked-in syndrome	Preserved	Preserved	Complete paralysis with the exception of vertical eye movements with normal sensation and cognition
Psychogenic unresponsiveness	Preserved, but may appear altered	Preserved, but may appear altered	Changing physical examination findings; characteristic responses to the “hand drop” test or forced eye closure

may be flustered as to what happened or “shocked.” That being said, family members as well as the responding paramedics or any other witnesses to the loss of consciousness can potentially provide valuable information. How and where was the patient found? Was there an abrupt loss of consciousness that may indicate a vascular disorder or was the loss of consciousness preceded by several days of worsening confusion, such as might be seen in a metabolic disorder or an evolving intracranial mass? Were there empty pill or alcohol bottles around the patient that may suggest intoxication? The circumstances surrounding the discovery of the patient can provide valuable clues, but they should be taken in context of the wider clinical picture.

Family members can be especially helpful in providing information about the patient’s medical history and allergies. Did the patient have a history of cardiac or vascular disease, which may increase your suspicion for an ischemic event or arrhythmia? What medications was the patient taking and were they actually taking their medications as prescribed? Was the patient taking any herbal supplements that may have interacted with their other medications? Is there a past psychiatric history, including prior suicide attempts or alcohol or drug abuse? Has the patient experienced events in the past similar to the current event?

In addition to past medical history, the recent medical history can provide important clues and can be gleaned from family members. Had the patient complained of headache or fever in the days prior to the event, which may imply an infectious etiology? Was there any confusion or difficulties with speech or language in the preceding days? Regardless of the information obtained in the history, the physical examination, including both a general and a neurologic examina-

tion, is key in refining the differential diagnosis and focusing further testing and potential treatment. Before a neurologic examination is performed, it is helpful to have a good understanding of the major causes of coma. A summary is shown in ►Table 2.

The Physical Examination

General Considerations

The examination of any unresponsive patient should begin with an assessment of vital signs. Not only does this allow for evaluation of the stability of the patient, it may also provide clues to the etiology of the patient’s unresponsiveness. For instance, while hyperthermia can be seen in midbrain or pontine hemorrhages, infection and various drug overdoses including cocaine, tricyclic antidepressants, and salicylate intoxication can also lead to elevated temperature, whereas hypothermia is seen with alcohol intoxication or an overdose of barbiturates. Similarly, hypertension can be seen secondary to increased intracranial pressure, but can also be indicative of posterior reversible encephalopathy syndrome (PRES) or amphetamine overdose. Hypotension can point toward sepsis or progression to brain death.

One commonly overlooked examination finding is the patient’s respiratory pattern. Although commonly difficult to observe because of mechanical ventilation, a spontaneous ventilator mode can be used to assess the patient’s intrinsic breathing pattern. It should be noted, however, that the value of these patterns in localizing a lesion is not firmly established. Cheyne-Stokes respirations can be seen with heart failure or in any form of reduced responsiveness and is therefore poorly localizing.^{5,6} Cluster breathing as well as

This document was downloaded for personal use only. Unauthorized distribution is strictly prohibited.

Table 2 Classification and major causes of coma⁵

Structural brain injury
Hemisphere
Unilateral (with displacement)
Intraparenchymal hematoma
Middle cerebral artery occlusion
Hemorrhagic contusion
Cerebral abscess
Brain tumor
Bilateral
Penetrating traumatic brain injury
Multiple traumatic brain injuries
Anoxic-ischemic encephalopathy
Aneurysmal subarachnoid hemorrhage
Multiple cerebral infarcts
Bilateral thalamic infarcts
Cerebral venous thrombosis
Lymphoma
Encephalitis
Gliomatosis
Acute disseminated encephalomyelitis
Cerebral edema
Multiple brain metastases
Acute hydrocephalus
Acute leukodystrophy
Brainstem
Pontine hemorrhage
Basilar artery occlusion
Central pontine myelinolysis
Brainstem hemorrhagic contusion
Cerebellum (with displacement of brainstem)
Cerebellar infarct
Cerebellar hematoma
Cerebellar abscess
Cerebellar glioma
Acute metabolic-endocrine derangement
Hypoglycemia
Hyperglycemia (nonketotic hyperosmolar)
Hyponatremia
Hypernatremia
Addison disease
Hypercalcemia
Acute hypothyroidism
Acute panhypopituitarism
Acute uremia

Table 2 (Continued)

Structural brain injury
Hyperbilirubinemia
Hypercapnia
Diffuse physiologic brain dysfunction
Generalized tonic-clonic seizures
Poisoning, illicit drug use
Hypothermia
Gas inhalation
Acute (lethal) catatonia, malignant neuroleptic syndrome
Psychogenic unresponsiveness
Hysterical
Malingering

Source: Used with permission from Wijdicks EFM. *The Practice of Emergency and Critical Care Neurology*. New York, NY: Oxford University Press; 2010.

central neurogenic hyperventilation can both indicate bihemispheric or pontine lesions.^{7,8} Neurogenic hyperventilation can also be seen with midbrain lesions. Ataxic breathing, characterized by no discernible respiratory pattern, may indicate a lesion of the dorsomedial medulla, while apneustic breathing is seen with lesions of the lateral tegmentum within the lower pons.^{9,10} See ► **Table 3** for a brief description of respiratory patterns.

The general skin appearance and any unusual odors emanating from the patient should also be noted. Are there signs of trauma, such as a Battle sign (bruising of the mastoid bone) or raccoon eyes (periorbital ecchymosis), which may each suggest skull base fractures? Dry skin can signify barbiturate intoxication (a rare intoxication these days), while diaphoresis can imply hypoglycemia or cholinergic toxicity. The classic foul breaths are also occasionally helpful and include a “dirty toilet” odor with uremia, a “fruity sweat” odor with ketoacidosis, the “fishy” odor with acute hepatic failure, an “onion” odor secondary to paraldehyde, and a “garlic” odor from organophosphates. ► **Table 4** summarizes the general examination findings and their potential implications.

The Neurologic Examination

Coma Scales

The primary goal of the neurologic examination in an unresponsive patient is to localize the lesion and thereby narrow the differential diagnosis. The examination should proceed in a stepwise fashion and be familiar to the neurologist because of constant repetition.

In the process of the comprehensive neurologic examination, the depth of coma should be determined using a coma scale. The Glasgow Coma Scale (GCS) is the most common of such scales. Originally developed for victims of traumatic head injury in 1974 and revised in 1976, it consists of three parts: eye movement, best motor response, and best verbal

Table 3 Breathing abnormalities¹¹

Breathing abnormality	Description of breathing	Localization
Cheyne-Stokes	Crescendo–decrescendo breathing pattern followed by apnea or hypopnea; persists in sleep	Bihemispheric (unilateral or bilateral) or brainstem
Cluster	Irregular clusters of breaths followed by apneic periods of variable duration	Bihemispheric or pons
Ataxic or irregular	Irregular respiratory rate, rhythm; amplitudes interrupted by apnea	Nonlocalizing or dorsomedial medulla
Apneustic	Prolonged inspiration with a 2- to 3-s pause, then expiration	Lateral tegmentum of lower pons
Central neurogenic hyperventilation	Sustained hyperventilation, respiratory rates exceeding 40 per minute	Bihemispheric, pons, midbrain

Source: Reprinted with permission from Wijdicks EFM. *The Comatose Patient*. New York, NY: Oxford University Press; 2008.

response (► **Table 5**).^{12,13} Each component is graded on a scale from 1 to 6 and the summation of the scores is used to communicate the depth of coma. Although not useful in the diagnosis of coma, the GCS has been shown to have acceptable interobserver reliability through a wide range of trained providers as well as predictive value for outcomes in tuberculous meningitis, subarachnoid hemorrhage, subdural hematoma, and survivors of cardiac arrest.^{14–26} However, the GCS does not account for the presence or absence of brainstem reflexes and may not detect subtle changes in the neurologic examination, findings that could be instrumental in determining a patient's prognosis.

To address the shortcomings of the GCS, the Full Outline of UnResponsiveness (FOUR) score was developed. This coma score includes four components—eye, motor, brainstem, and respiratory—that are each graded on a scale from 0 to 4, producing a maximum combined total score of 16 (► **Fig. 1**).^{27,28} With an equal to higher interrater reliability than the GCS, as well as validation in multiple patient populations, the FOUR score has proven to be an important tool in the evaluation of comatose patients.^{27,29–37} Perhaps because of its greater emphasis on brainstem reflexes and respiratory patterns, the FOUR score has also been shown to have greater predictive value in terms of eventual progression toward more severe injury, especially in patients with low GCS scores or the ubiquitous GCS score of 3T, which is commonly reported by paramedics following intubation in the field after sedatives and paralytics have been given.³⁸

Cranial Nerves

The formal neurologic evaluation of an unresponsive patient typically begins with the cranial nerves. Pupil size as well as position should be examined. Small or pinpoint pupils (< 2 mm) that are minimally or unreactive to light could be secondary to a pontine lesion that interrupts descending sympathetic outflow. The most commonly known cause of small pupils is prior use of opioids (on the street, heroin; while in the hospital, it is patient-controlled analgesia pumps or opioid patches). Dilated (> 8 mm) pupils are due to disruption of cranial nerve (CN) III secondary to either a mesencephalic injury or a lesion of the peripheral nerve. Drugs and other toxins such as amphetamines or lidocaine

can also result in dilated pupils and must be excluded through the patient's history and laboratory testing. Midsize, light-fixed pupils are seen in severe midbrain lesions that can be secondary to herniation and are frequently the first sign of loss of all brainstem reflexes (brain death).

In addition to pupil size and reactivity, any deviation of one or both eyes should also be noted. Spontaneous eye movements including “ping-pong” eyes or ocular dipping generally indicate bihemispheric dysfunction. Ocular bobbing, described as a rapid downward deviation of the eyes followed by a slow upward movement, typically implies a pontine lesion. Bihemispheric dysfunction can also lead to the classic “roving eye movements,” though metabolic processes and various toxicities can cause this as well. Rather than supporting a particular localization or disease process, roving eye movements indicate that the brainstem is relatively intact. See ► **Table 6** for a summary of eye movement abnormalities in coma.

Tonic deviation of the eyes, typically in the horizontal plane, may indicate an ipsilateral hemispheric lesion affecting the frontal eye fields or a contralateral pontine lesion. Differentiation between a hemispheric lesion and a pontine lesion can be difficult in comatose patients as a hemiparesis is typically not apparent. However, the oculocephalic maneuver will be able to overcome a gaze preference from a cortical lesion as the pontine and midbrain structures responsible for the reflex remain intact. Horizontal deviation can also be seen in nonconvulsive status epilepticus and may be one of the few signs to indicate the need for an emergent electroencephalogram (EEG). Skew deviation implies a brainstem injury.

A funduscopic examination should also be performed once the external examination of the eyes has been completed. Vitreous hemorrhage, often subhyaloid in location, can be indicative of subarachnoid hemorrhage, so-called Terson syndrome, or even intracranial hemorrhage.³⁹ Funduscopy may also reveal the presence of papilledema. Though often cited as a manifestation of acutely increased intracranial pressure in subarachnoid hemorrhage or acute meningitis, papilledema is more commonly seen with slowly progressive processes such as an enlarging intracranial mass.^{40–42}

Further testing of the cranial nerves is accomplished through the various reflexes including the corneal, gag, and

Table 4 Physical findings that may indicate a systemic illness or drug toxicity

Sign or symptom	Consideration
Vital signs	
Hypertension	Pheochromocytoma, eclampsia, calcineurin inhibitor toxicity, drug ingestion (amphetamines, arsenic, cocaine, phencyclidine)
Hypotension	Addison disease, sepsis, drug ingestion (β blockers, calcium channel blockers, arsenic, barbiturates, cyclic antidepressants, lithium, methanol, opioids, organophosphates, phenothiazine, sedative-hypnotics)
Hyperthermia	Infection, drug ingestion (amphetamines, cocaine, tricyclic antidepressants, phencyclidine, salicylates), malignant catatonia, neuroleptic malignant syndrome
Hypothermia	Hypothyroidism, hypoglycemia, environmental exposure, drug ingestion (barbiturates, opioids, sedative-hypnotics, phenothiazine)
Tachycardia	Infection, drug ingestion (alcohol, amphetamines, cocaine, ethylene glycol, arsenic, cyclic antidepressants, phencyclidine, phenothiazine)
Bradycardia	Uremic coma, myxedema coma, drug ingestion (β blockers, opioids)
Tachypnea	Diabetic ketoacidosis, drug ingestion (ethylene glycol, salicylates, amphetamines, methanol)
Dyspnea	Drug ingestion (alcohol, barbiturates, opioids, sedative-hypnotics)
Odor	
“Dirty restroom”	Uremia
“Fruity sweat”	Ketoacidosis
“Musty or fishy”	Acute hepatic failure
“Onion”	Paraldehyde
“Garlic”	Organophosphates, insecticides, thallium
Skin	
Diaphoresis	Thyroid storm, hypoglycemia, malignant catatonia, acute sympathetic hyperactivity, drug exposure (organophosphates, sympathomimetics, cholinergics)
Dry skin	Hypothyroidism, drug exposure (barbiturates, anticholinergics, cyclic antidepressants)
Acne	Long-term antiepileptic use
Bullae	Drug exposures (barbiturates, sedative-hypnotics)
Butterfly rash	Systemic lupus erythematosus
Dark pigmentation	Addison disease
Cold, malar flush, yellow tinge, puffy face	Myxedema coma
Edema	Acute renal failure
Purpura	Meningococcal meningitis, thrombotic thrombocytopenic purpura, vasculitis, disseminated intravascular coagulation, aspirin intoxication
Rash	Meningitis, viral encephalitis, rickettsia

Table 5 The Glasgow Coma Scale

	Best eye response	Best verbal response	Best motor response
6	—	—	Obeys commands
5	—	Oriented	Localizes pain
4	Spontaneous eye opening	Confused	Withdraws from pain
3	Eye opening to verbal command	Points	Flexion response to pain
2	Eye opening to pain	Incomprehensible sounds	Extension response to pain
1	No response	No response	No response

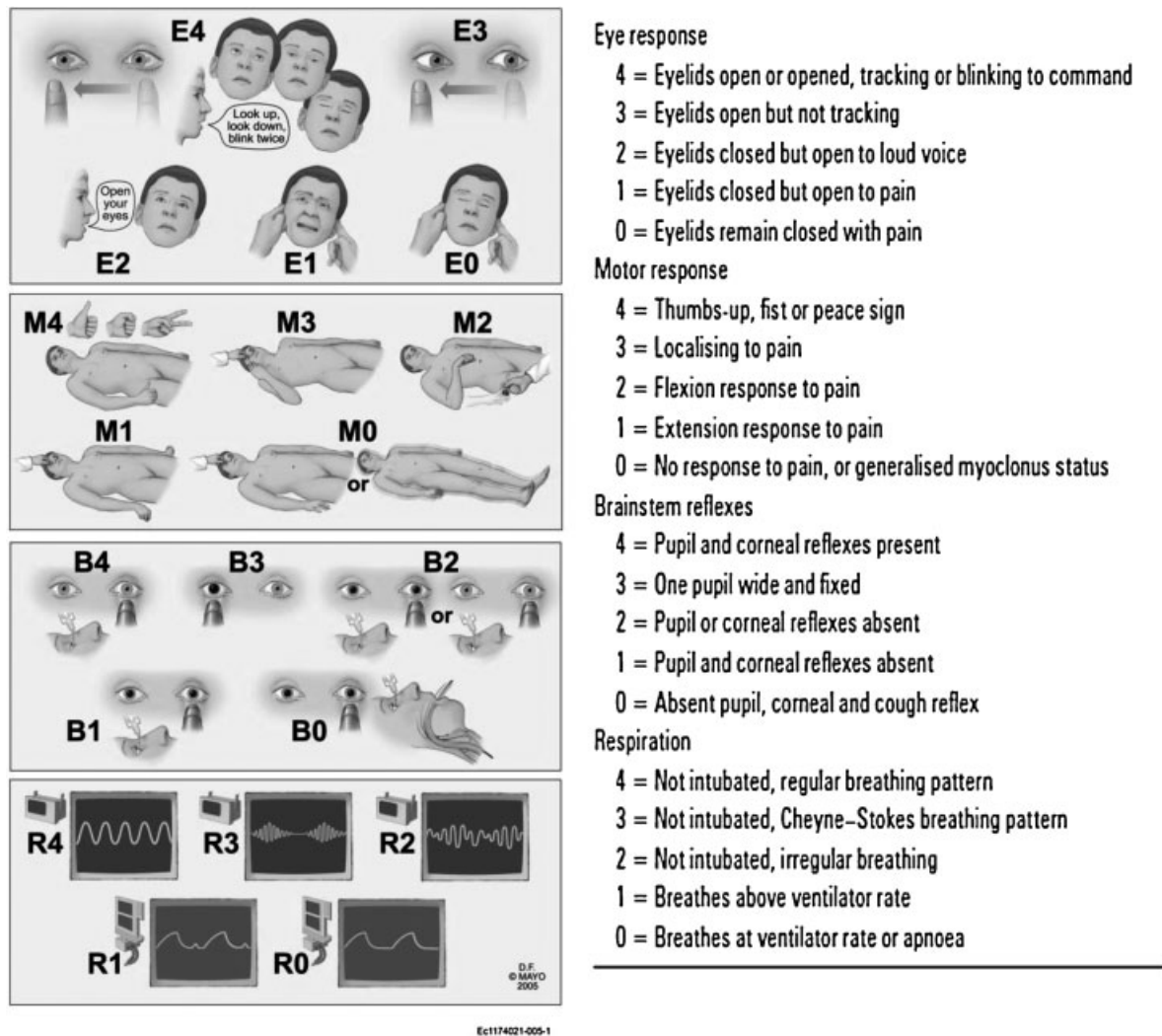


Fig. 1 The FOUR Score.⁵ (Reprinted with permission from Wijdicks EFM. The Practice of Emergency and Critical Care Neurology. New York, NY: Oxford University Press; 2010:110)

cough reflexes. Dysfunction of any of these reflexes implies a lesion involving the cranial nerves involved or the pathways connecting them. The oculocephalic reflex deserves special mention as several brainstem structures are assessed simultaneously. In a patient with a normally functioning brainstem, eyes will move in a direction opposite the head movement and appear to remain fixated on a point in space (much like a doll's eyes). If a lesion disrupts any of the

structures or pathways involved in the reflex, including CNs III, IV, and VI and the medial longitudinal fasciculus, the eyes will move along with the head, remaining in midposition with respect to the bony orbits.

Motor Responses

Testing of the motor system in an unresponsive patient typically involves applying a noxious stimulus to the

Table 6 Eye movement abnormalities in coma¹¹

Type of movement	Lesion location
Periodic alternating gaze (lateral deviation every few minutes, left and right)	Bihemispheric, midbrain, vermis
Ping-pong (lateral deviation every few seconds, left and right)	Bihemispheric, vermis
Convergence nystagmus (bilateral abduction, slow with rapid jerk back)	Mesencephalon
Retractory nystagmus (retraction orbit)	Mesencephalon
Bobbing (rapid down, slow up)	Pons
Dipping (slow down, rapid up)	Bihemispheric

Source: Reprinted with permission from Wijdicks EFM. The Comatose Patient. New York, NY: Oxford University Press; 2008.

supraorbital nerve, the nail bed, or the temporomandibular joint and assessing the patient's reaction.⁴³ Possible responses include a localizing response, in which the patient reaches toward the stimulus, reflexive responses such as decorticate or decerebrate posturing, or no response at all.

Decorticate posturing involves a slow flexion of the elbow, wrist, and fingers, whereas decerebrate posturing is defined as adduction and internal rotation of the shoulder with arm extension and wrist pronation. Although posturing reflexes have purportedly been useful in lesion localization, these responses can be seen with either focal lesions or global conditions affecting the nervous system.^{44,45} It is also not uncommon for both responses to be present in the same patient at the same time.¹¹ Given this, the presence of decerebrate or decorticate posturing has relatively little utility in prognostication until the underlying etiology is found.

In addition to movements in response to stimulation, spontaneous movements can also be seen in unresponsive patients, the classic example being generalized myoclonus. Although a predictor of an extremely poor outcome following cardiac arrest and resulting anoxic ischemic injury, generalized myoclonus can also be seen with various intoxications including lithium, cephalosporins, and pesticides.⁴⁶⁻⁴⁸

Initial Approach to the Unresponsive Patient

Neuroimaging

Unfortunately, many unresponsive or comatose patients lack true localizing features on examination; in such instances, further testing with neuroimaging and laboratory evaluation may help in determining the underlying etiology. Even in a patient whose examination allows the neurologist to localize the lesion, imaging and laboratory investigation continue to play a key role. For instance, the examination may suggest a lesion involving the midbrain, but the lesion can be a stroke or a mass.

At most institutions, the computed tomography (CT) scan is the fastest and most readily available imaging modality. In the evaluation of an unresponsive patient, CT scans are excellent at detecting hydrocephalus or intracranial hemorrhage, with a sensitivity and specificity approaching 100% in conditions such as acute (< 12 h since onset) subarachnoid hemorrhage.^{49,50} Computed tomography scans are also useful in the detection of edema, though the underlying cause of the edema may be elusive. Limitations of CT include poor visualization of the posterior fossa secondary to bone artifact, as well as reduced anatomical differentiation in comparison to magnetic resonance imaging (MRI) that may not allow precise etiological determination.

Magnetic resonance imaging scans allow greater definition of cortical and subcortical structures and may show cortical injury, laminar necrosis, or white matter disease that is not apparent on a CT scan. Magnetic resonance angiography allows for excellent visualization of the arterial system and is the preferred method for visualization of suspected acute basilar artery occlusion,^{51,52} however, this may not be possible at all institutions; in such instances, CT angiogram or

conventional angiography can allow for rapid visualization of the arterial system. The major drawbacks of MRI scans include accessibility, cost, and time necessary to complete the scan. Frequent abnormalities on brain imaging in a comatose patient are presented in ►Table 7 along with possible underlying etiologies for the findings.

Laboratory and Ancillary Investigations

Laboratory evaluation plays a prominent role in the evaluation of an acute unresponsive patient and can often lead to a relatively rapid diagnosis of any acute metabolic abnormality (►Table 8). As part of the initial workup of any unresponsive patient, the following laboratories are essential: hematocrit, full blood count with differential, platelet count, and peripheral blood smear; full electrolyte panel including calcium, magnesium, and phosphorus in addition to the conventional sodium and potassium; creatinine and blood urea nitrogen; liver function tests including aspartate aminotransferase blood test (AST), alanine aminotransferase blood test (ALT), bilirubin, and ammonia; serum and urine osmolality; arterial blood gases; thyroid function tests; and urinalysis. Further testing should be tailored to the clinical history, physical examination, and imaging. For instance, urine and blood drug screens should be obtained if any toxicity is suspected. In patients who present with fever and/or an elevated white blood cell count, blood cultures are a necessity. Troponins should be obtained if there is any suspicion of an acute cardiac pathology.

It is important to calculate the anion and osmolar gaps as these can aid in diagnosis of an acute intoxication. Anion gap = $[Na^+] - [Cl^-] - [HCO_3^-]$. A normal anion gap is between 11 and 13 mEq/l and increases in the presence of unmeasured anions, such as in methanol, ethanol, paraldehyde, and salicylate intoxications. Osmol gap = $2 \times Na^+ + [glucose]/18 + [blood\ urea\ nitrogen]/2.8$. A difference between the calculated and measured osmolality greater than 10 mosmol/l can indicate intoxication with atypical alcohols including methanol, ethylene glycol, and isopropyl glycol.

Although more invasive, a lumbar puncture (LP) should be performed in all unresponsive patients with either signs or symptoms of infection or meningeal irritation or when the CT scan is normal and no explanation exists for the decreased responsiveness. Tests that should be included on evaluation of the cerebrospinal fluid (CSF) include an opening pressure, CSF visual description, protein and glucose content, cellular evaluation including white blood cells and erythrocytes, bacterial culture, India ink stain and cryptococcal antigen, and viral titers and polymerase chain reactions. A CT or MRI scan would ideally precede an LP to exclude an epidural empyema that may cause further shift after LP.

The role of an urgent EEG in an unresponsive patient is somewhat limited with the exception of nonconvulsive status epilepticus. Nonconvulsive status epilepticus should be suspected in any patient with a history of seizures who becomes acutely unresponsive, but can also be considered in otherwise unexplained cases of acute unresponsiveness. Physical examination of a patient in nonconvulsive status epilepticus is commonly nonspecific, but may reveal altered mental status ranging from confused to comatose,

Table 7 Frequent abnormalities on brain imaging in coma⁵³

Finding	Suggested disorder
Computed tomography	
Mass lesion	Hematoma, hemorrhagic contusion, middle cerebral artery infarct
Hemorrhage in basal cisterns	Aneurysmal subarachnoid hemorrhage, cocaine abuse
Intraventricular hemorrhage	Arteriovenous malformation
Multiple hemorrhage infarcts	Cerebral venous thrombosis
Multiple cerebral infarcts	Endocarditis, coagulopathy, vasculitis, thrombotic thrombocytopenic purpura
Diffuse cerebral edema	Cardiac arrest, fulminant meningitis, acute hepatic necrosis, encephalitis
Acute hydrocephalus	Aqueduct obstruction, colloid cyst, pineal region tumor
Pontine or cerebellar hemorrhage	Hypertension, arteriovenous malformation, cavernous malformation
Shear lesions in the white matter	Traumatic brain injury
Magnetic resonance imaging	
Bilateral caudate and putaminal lesions	Carbon monoxide poisoning, methanol
Hyperdense signal along sagittal, straight, or transverse sinuses	Intracranial venous thrombosis
Lesions in corpus callosum, white matter	Severe traumatic brain injury
Diffuse confluent hyperintense lesions in white matter, basal ganglia	Acute disseminated encephalomyelitis, posterior reversible encephalopathy syndrome, immunosuppressive or chemotherapeutic agent toxicity, metabolic leukodystrophies
Pontine trident-shaped lesion	Central pontine myelinolysis
Thalamus, occipital, brainstem lesions	Acute basilar artery occlusion
Thalamus, frontal lobe lesions	Herpes simplex encephalitis

Source: Reprinted with permission from Wijdicks EFM. *Catastrophic Neurologic Disorder in the Emergency Department*. New York, NY: Oxford University Press; 2004.

subtle myoclonic movements in an extremity, or eye deviation.⁵⁴ The classic role of EEG in the diagnosis of herpes simplex encephalitis has mostly been supplanted by MRI and CSF studies, and although generalized slowing and triphasic waves can be seen on EEG with structural and metabolic causes of unresponsiveness, the etiology is generally well established prior to the EEG.

An Exercise in Diagnosis

Two cases are presented. We have used a systematic approach as shown in ►Fig. 2 to illustrate its usefulness in clinical practice.

Table 8 Laboratory values compatible with coma in patients with acute metabolic derangements^a

Derangement	Serum concentration
Hyponatremia	< 110 mmol/l
Hypernatremia	> 160 mmol/l
Hypercalcemia	> 13 mg/dl
Hypercapnia	> 65 mm Hg
Hypoglycemia	< 40 mg/dl
Hyperglycemia	> 900 mg/dl

^aSudden decline in value is necessary.

Case 1

A middle-aged man was brought into the emergency department after being found prone and unresponsive for an unknown period. Because of vomiting, tachypnea (respiratory rate of 28), with no protection of his airway, the patient was intubated in the field. No further history was available. The patient was afebrile. Blood pressure was 148/89 with a heart rate of 85.

On physical examination, the patient appeared thin. Skin exam showed rare spider telangiectasias over the chest. The patient smelled faintly sweet. Neurologic examination revealed a comatose patient (GCS 3T, FOUR Score E0M0B4R3). The examination was otherwise nonlocalizing. The emergent CT scan was normal.

With a normal CT scan, the potential etiologies include toxic, epileptic, infectious, endocrine/metabolic, and anoxic/ischemic. The emergent EEG was normal, ruling out status epilepticus. Routine laboratory investigation revealed a normal complete blood count including normal leukocyte count, which rules out infection assuming a normal immune system. Thyroid stimulating hormone and glucose were normal, ruling out the most common causes of endocrine/metabolic coma.

With all other possibilities ruled out, intoxication remains the most likely explanation for the patient's unresponsiveness. Electrolytes were normal except for slightly low calcium, mildly elevated AST and ALT with normal

This document was downloaded for personal use only. Unauthorized distribution is strictly prohibited.

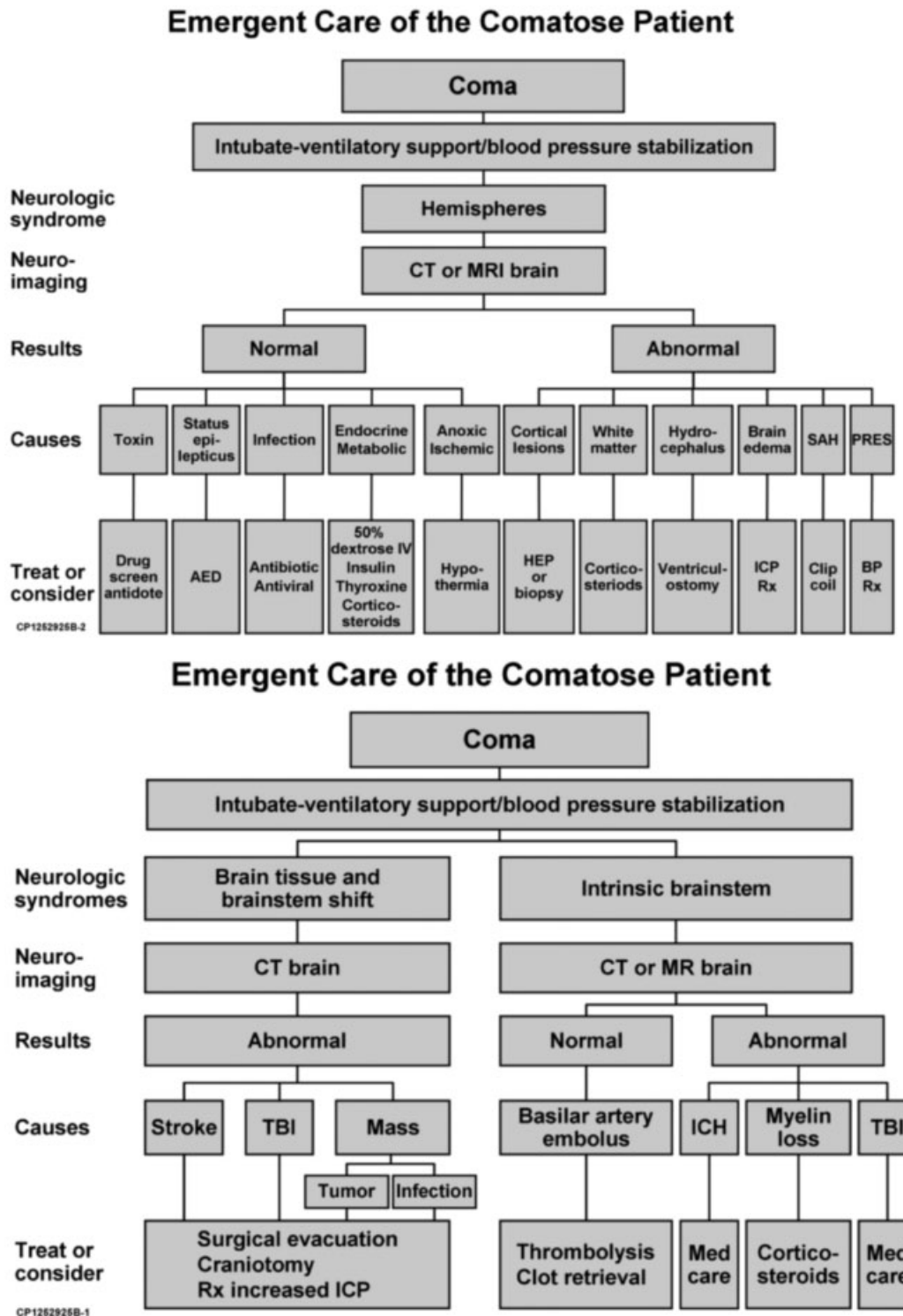


Fig. 2 Emergent diagnosis and care of the comatose patient.

ammonia and bilirubin, and slightly elevated creatinine. Osmol and anion gaps were significantly elevated at 29 and 19, respectively. The significant elevations in the anion and osmol gap indicate the presence of an unmeasured anion, particularly an atypical alcohol. In this case, ethylene glycol taken by a chronic alcoholic is the correct diagnosis.

Case 2

A middle-aged man was brought into the emergency department after being found prone and unresponsive for an unknown period. Breathing was described as erratic with periods of apnea and the patient was intubated in the field. No further history was available. The patient was afebrile. Blood pressure and heart rate were stable and required no treatment.

On physical examination, the patient was comatose (GCS 4T, FOUR Score E0M1B2R1). General examination was normal. Cranial nerve examination revealed a right pinpoint pupil that was reactive to light and a left midposition pupil that was unreactive to light. Corneal reflex was absent on the left. Cough and gag reflexes remained intact. Motor examination showed bilateral extensor posturing to painful stimuli. An emergent CT scan was normal.

Laboratory workup, including complete blood count, full electrolyte panel, liver function tests, arterial blood gases, and thyroid function test, was normal. Osmol and anion gaps were normal. Urine drug screen was negative.

Given the physical examination findings, the lesion localized to the brainstem, but was more diffuse (pontine pupil on the right and midbrain pupil on the left). With a normal CT scan and normal laboratory investigation, the lesion was likely the result of an embolus to the basilar artery. This was confirmed with a CT angiogram and resulted in urgent endovascular retrieval.

Conclusions

Following stabilization of the patient, the task of the neurologist is to interpret the information beginning with the history and physical examination and to order the appropriate tests. Important causes that should always be included in the differential of a patient who presents following sudden unresponsiveness are anoxic-ischemic injury, intoxication, central nervous infection, sudden metabolic derangement or endocrine crisis, nonconvulsive status epilepticus, embolus to the basilar artery, and, rarely, psychogenic.

Neuroimaging may help identify the underlying abnormality, just as a basic laboratory investigation that should include osmol and anion gap calculations.

Initial management of an unresponsive patient often starts before an etiology is clear, and is commonly based on clinical interpretation of the aforementioned tests. For instance, if a CT or MRI shows an acute structural lesion with mass effect, the first priority is to treat the intracranial pressure before the exact identity of the mass is known. In patients with potential infection, broad spectrum antibiotics, antivirals, and corticosteroids are started prior to identification of the infection.

References

- 1 Posner JB, Saper CB, Schiff ND, Plum F. Plum and Posner's Diagnosis of Stupor and Coma. 4th ed. New York, NY: Oxford University Press; 2007:3-37
- 2 Medical aspects of the persistent vegetative state (1). The Multi-Society Task Force on PVS. *N Engl J Med* 1994;330(21):1499-1508
- 3 Medical aspects of the persistent vegetative state (2). The Multi-Society Task Force on PVS. *N Engl J Med* 1994;330(22):1572-1579
- 4 Giacino JT, Ashwal S, Childs N, et al. The minimally conscious state: definition and diagnostic criteria. *Neurology* 2002;58(3):349-353
- 5 Wijdicks EFM. *The Practice of Emergency and Critical Care Neurology*. New York, NY: Oxford University Press; 2010:104-136
- 6 Tobin MJ, Snyder JV. Cheyne-Stokes respiration revisited: controversies and implications. *Crit Care Med* 1984;12(10):882-887
- 7 Cherniack NS, Longobardo G, Evangelista CJ. Causes of Cheyne-Stokes respiration. *Neurocrit Care* 2005;3(3):271-279
- 8 Tarulli AW, Lim C, Bui JD, Saper CB, Alexander MP. Central pathogenic hyperventilation: a case report and discussion of pathophysiology. *Arch Neurol* 2005;62(10):1632-1634
- 9 Freeman WD, Sen S, Roy TK, Wijdicks EF. Cluster breathing associated with bihemispheric infarction and sparing of the brainstem. *Arch Neurol* 2006;63(10):1487-1490
- 10 Saito Y, Hashimoto T, Iwata H, et al. Apneustic breathing in children with brainstem damage due to hypoxic-ischemic encephalopathy. *Dev Med Child Neurol* 1999;41(8):560-567
- 11 Wijdicks EFM. *The Comatose Patient*. New York, NY: Oxford University Press; 2008:64-83
- 12 Wijdicks EF. The bare essentials: coma. *Pract Neurol* 2010;10(1):51-60
- 13 Jennett B, Teasdale G, Braakman R, Minderhoud J, Knill-Jones R. Predicting outcome in individual patients after severe head injury. *Lancet* 1976;1(7968):1031-1034
- 14 Teasdale G, Jennett B. Assessment of coma and impaired consciousness. A practical scale. *Lancet* 1974;2(7872):81-84
- 15 Scheffold JC, Storm C, Krüger A, Ploner CJ, Hasper D. The Glasgow Coma Score is a predictor of good outcome in cardiac arrest patients treated with therapeutic hypothermia. *Resuscitation* 2009;80(6):658-661
- 16 Mullie A, Verstringe P, Buylaert W, et al; Cerebral Resuscitation Study Group of the Belgian Society for Intensive Care. Predictive value of Glasgow coma score for awakening after out-of-hospital cardiac arrest. *Lancet* 1988;1(8578):137-140
- 17 Geocadin RG, Buitrago MM, Torbey MT, Chandra-Strobos N, Williams MA, Kaplan PW. Neurologic prognosis and withdrawal of life support after resuscitation from cardiac arrest. *Neurology* 2006;67(1):105-108
- 18 Edgren E, Hedstrand U, Kelsey S, Sutton-Tyrrell K, Safar P; BRCT I Study Group. Assessment of neurological prognosis in comatose survivors of cardiac arrest. *Lancet* 1994;343(8905):1055-1059
- 19 Phuenpathom N, Choomuang M, Ratanalert S. Outcome and outcome prediction in acute subdural hematoma. *Surg Neurol* 1993;40(1):22-25
- 20 Chou CH, Lin GM, Ku CH, Chang FY. Comparison of the APACHE II, GCS and MRC scores in predicting outcomes in patients with tuberculous meningitis. *Int J Tuberc Lung Dis* 2010;14(1):86-92
- 21 Hirai S, Ono J, Yamaura A. Evaluation of consciousness by the Glasgow Coma Scale in aneurysmal subarachnoid hemorrhage. Appraisal using logistic regression analysis. *Clin Neurol Neurosurg* 1997;99(Suppl 1):S42-S43
- 22 Rosen DS, Macdonald RL. Subarachnoid hemorrhage grading scales: a systematic review. *Neurocrit Care* 2005;2(2):110-118
- 23 Juarez VJ, Lyons M. Interrater reliability of the Glasgow Coma Scale. *J Neurosci Nurs* 1995;27(5):283-286
- 24 Menegazzi JJ, Davis EA, Sucov AN, Paris PM. Reliability of the Glasgow Coma Scale when used by emergency physicians and paramedics. *J Trauma* 1993;34(1):46-48
- 25 Fielding K, Rowley G. Reliability of assessments by skilled observers using the Glasgow Coma Scale. *Aust J Adv Nurs* 1990;7(4):13-17
- 26 Gill MR, Reiley DG, Green SM. Interrater reliability of Glasgow Coma Scale scores in the emergency department. *Ann Emerg Med* 2004;43(2):215-223
- 27 Marion DW, Carlier PM. Problems with initial Glasgow Coma Scale assessment caused by prehospital treatment of patients with head injuries: results of a national survey. *J Trauma* 1994;36(1):89-95
- 28 Wijdicks EF, Bamlet WR, Maramattom BV, Manno EM, McClelland RL. Validation of a new coma scale: The FOUR score. *Ann Neurol* 2005;58(4):585-593
- 29 Wijdicks EF, Kokmen E, O'Brien PC. Measurement of impaired consciousness in the neurological intensive care unit: a new test. *J Neurol Neurosurg Psychiatry* 1998;64(1):117-119
- 30 Looser RR, Metzenthin P, Helfrich S, et al. Cortisol is significantly correlated with cardiovascular responses during high levels of stress in critical care personnel. *Psychosom Med* 2010;72(3):281-289

- 31 Wolf CA, Wijdicks EF, Bamlet WR, McClelland RL. Further validation of the FOUR score coma scale by intensive care nurses. *Mayo Clin Proc* 2007;82(4):435–438
- 32 Stead LG, Wijdicks EF, Bhagra A, et al. Validation of a new coma scale, the FOUR score, in the emergency department. *Neurocrit Care* 2009;10(1):50–54
- 33 Iyer VN, Mandrekar JN, Danielson RD, Zubkov AY, Elmer JL, Wijdicks EF. Validity of the FOUR score coma scale in the medical intensive care unit. *Mayo Clin Proc* 2009;84(8):694–701
- 34 Fugate JE, Rabinstein AA, Claassen DO, White RD, Wijdicks EF. The FOUR score predicts outcome in patients after cardiac arrest. *Neurocrit Care* 2010;13(2):205–210
- 35 Sadaka F, Patel D, Lakshmanan R. The FOUR score predicts outcome in patients after traumatic brain injury. *Neurocrit Care* 2012;16(1):95–101
- 36 Idrovo L, Fuentes B, Medina J, et al. Validation of the FOUR score (Spanish version) in acute stroke: an interobserver variability study. *Eur Neurol* 2010;63(6):364–369
- 37 Fischer M, Rüegg S, Czaplinski A, et al. Inter-rater reliability of the Full Outline of UnResponsiveness score and the Glasgow Coma Scale in critically ill patients: a prospective observational study. *Crit Care* 2010;14(2):R64
- 38 Wijdicks EF, Rabinstein AA, Bamlet WR, Mandrekar JN. FOUR score and Glasgow Coma Scale in predicting outcome of comatose patients: a pooled analysis. *Neurology* 2011;77(1):84–85
- 39 Hassan A, Lanzino G, Wijdicks EF, Rabinstein AA, Flemming KD. Terson's syndrome. *Neurocrit Care* 2011;15(3):554–558
- 40 Trobe JD. Papilledema: the vexing issues. *J Neuroophthalmol* 2011;31(2):175–186
- 41 van de Beek D, de Gans J, Spanjaard L, Weisfelt M, Reitsma JB, Vermeulen M. Clinical features and prognostic factors in adults with bacterial meningitis. *N Engl J Med* 2004;351(18):1849–1859
- 42 Ludwig CL, Smith MT, Godfrey AD, Armbrustmacher VW. A clinicopathological study of 323 patients with oligodendrogliomas. *Ann Neurol* 1986;19(1):15–21
- 43 Wijdicks EF. Temporomandibular joint compression in coma. *Neurology* 1996;46(6):1774
- 44 Kirk MM, Hoogwerf BJ, Stoller JK. Reversible decerebrate posturing after profound and prolonged hypoglycemia. *Cleve Clin J Med* 1991;58(4):361–363
- 45 Jabre A, Sawaya R, Arthur S. Decerebrate posturing with the syndrome of inappropriate secretion of antidiuretic hormone. *Surg Neurol* 1985;23(1):56–58
- 46 Wijdicks EF, Parisi JE, Sharbrough FW. Prognostic value of myoclonus status in comatose survivors of cardiac arrest. *Ann Neurol* 1994;35(2):239–243
- 47 Fugate JE, Wijdicks EF, Mandrekar J, et al. Predictors of neurologic outcome in hypothermia after cardiac arrest. *Ann Neurol* 2010;68(6):907–914
- 48 Caviness JN, Evidente VG. Cortical myoclonus during lithium exposure. *Arch Neurol* 2003;60(3):401–404
- 49 Sidman R, Connolly E, Lemke T. Subarachnoid hemorrhage diagnosis: lumbar puncture is still needed when the computed tomography scan is normal. *Acad Emerg Med* 1996;3(9):827–831
- 50 Perry JJ, Stiell IG, Sivilotti ML, et al. Sensitivity of computed tomography performed within six hours of onset of headache for diagnosis of subarachnoid haemorrhage: prospective cohort study. *BMJ* 2011;343:d4277
- 51 Bhadelia RA, Bengoa F, Gesner L, et al. Efficacy of MR angiography in the detection and characterization of occlusive disease in the vertebrobasilar system. *J Comput Assist Tomogr* 2001;25(3):458–465
- 52 du Mesnil de Rochemont R, Neumann-Haefelin T, Berkefeld J, Sitzer M, Lanfermann H. Magnetic resonance imaging in basilar artery occlusion. *Arch Neurol* 2002;59(3):398–402
- 53 Wijdicks EFM. *Catastrophic Neurologic Disorders in the Emergency Department*. 2nd ed. New York, NY: Oxford University Press; 2004
- 54 Husain AM, Horn GJ, Jacobson MP. Non-convulsive status epilepticus: usefulness of clinical features in selecting patients for urgent EEG. *J Neurol Neurosurg Psychiatry* 2003;74(2):189–191