

Esophageal bezoar in a patient with esophageal epiphrenic diverticulum

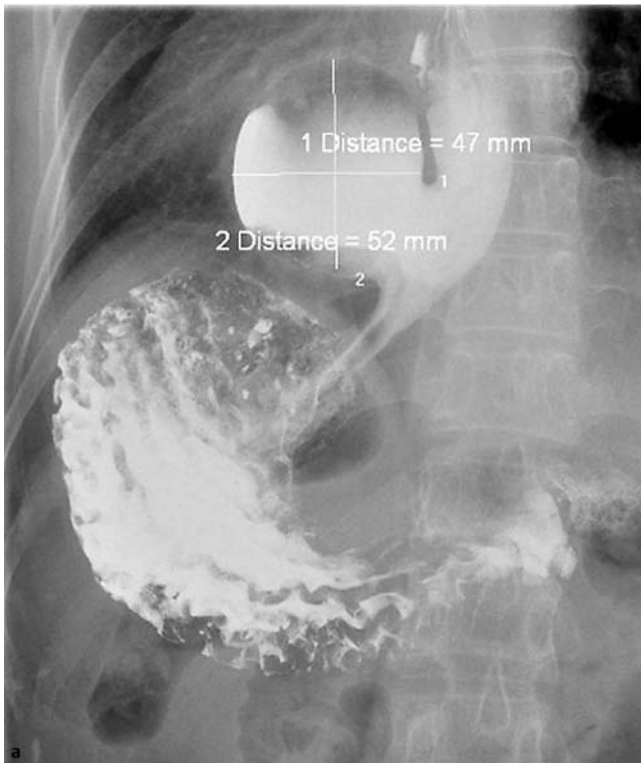


Fig. 1 **a** Barium swallow esophagography showing focal out-pouching, measured about 5 cm in size, at the distal third of the esophagus near the esophagogastric junction in a 57-year-old woman with dysphagia and postprandial epigastric fullness. **b** Esophagogastroduodenoscopy (EGD) showing dilated esophageal lumen with diverticulum formation at the lower esophagus.

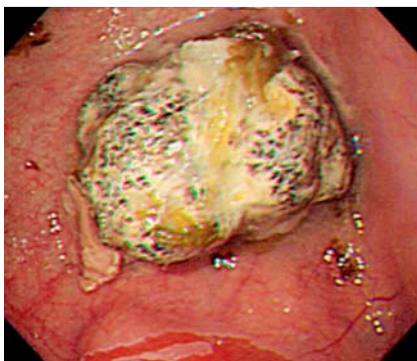
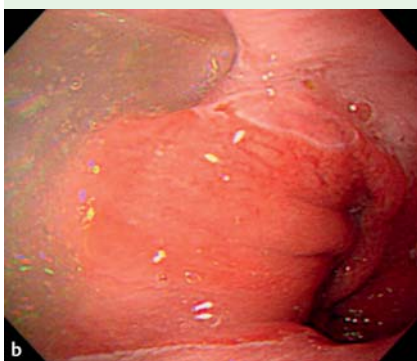
Fig. 2 Blackish, 3-cm long bezoar in the diverticulum.

A 57-year-old woman presented with dysphagia and postprandial epigastric fullness for about two years. Esophagogastroduodenoscopy (EGD) showed an esophageal diverticulum at the lower portion of the esophagus, and barium swallow esophagography showed a focal out-pouching space (measured about 5 cm in size) at the distal third of the esophagus near the esophagogastric junction (● Fig. 1). The patient reported having nausea and vomiting after eating in the past 2 days. She underwent another EGD, which revealed a 3-cm, blackish bezoar impacted in the esophageal diverticulum (● Fig. 2). The bezoar was removed with a snare basket. On reviewing her history, it was found that she had been taking Pho Pu Zi (*Cordia dichotoma* Forst. f.) as an appetizer for a month. Esophageal diverticulum is a rare esophageal disease and can occur anywhere in the esophagus [1]. The epiphrenic diverticulum is an acquired pulsion diverticulum that occurs near the diaphragmatic hiatus [1]. In about 80% of patients it is

associated with an underlying motility disorder, such as diffuse esophageal spasm, hypertensive lower esophageal sphincter (LES), and achalasia. The dysphagia is usually due to extrinsic compression by a large food-filled diverticulum or the underlying motility disorder. Esophageal bezoars are also usually associated with an underlying motility disorder. They mainly occur de novo [2] and are typically either phyto bezoars or medication bezoars [3]. Pho Pu Zi is a traditional Taiwanese appetizer, which may be ingested in large amounts during the harvesting season, when the sticky pulp of the fruit can form a phyto bezoar [4]. In the present case, the large epiphrenic diverticulum resulted in stagnation of the undigested food, which triggered the formation of a bezoar. The symptoms may worsen if an esophageal bezoar progressively increases in size. EGD is mandatory for diagnosis and treatment of esophageal bezoars [5].

Endoscopy_UCTN_Code_CCL_1AB_2AC_3AF

Competing interests: None

Y. C. Chen¹, M. C. Tsai^{1,2}, T. Y. Chen^{1,3}, C. C. Lin^{1,3}

¹ Division of Gastroenterology, Department of Internal Medicine, Chung Shan Medical University Hospital, Taichung, Taiwan

² Institute of Medicine, Chung Shan Medical University, Taichung, Taiwan

³ School of Medicine, Chung Shan Medical University, Taichung, Taiwan

References

- 1 Herbella FAM, Dubecz A, Patti MG et al. Esophageal diverticula and cancer. *Dis Esophagus* 2012; 25: 153–158
- 2 Gupta R, Share M, Pineau BC et al. Dissolution of an esophageal bezoar with pancreatic enzyme extract. *Gastrointest Endosc* 2001; 54: 96–99
- 3 Kim KH, Choi SC, Seo GS et al. Esophageal bezoar in a patient with achalasia: case report and literature review. *Gut Liver* 2010; 4: 106–109

- 4 Lin CS, Tung CF, Peng YC et al. Successful treatment with a combination of endoscopic injection and irrigation with coca cola for gastric bezoar-induced gastric outlet obstruction. *Chin Med Assoc* 2008; 71: 49–52
- 5 Forget P, Hantson P. Esophageal bezoar. *CJEM* 2008; 10: 574

Bibliography

DOI <http://dx.doi.org/10.1055/s-0033-1344127>
Endoscopy 2013; 45: E193–E194
© Georg Thieme Verlag KG
Stuttgart · New York
ISSN 0013-726X

Corresponding author**Dr C. C. Lin**

Department of Internal Medicine
Chung Shan Medical University Hospital
No. 110, Chien-Kuo N. Rd Sec. 1
Taichung 402
Taiwan
Fax: +886-4-24739220
forest65@ms8.hinet.net