

Bleeding left hepatic artery pseudoaneurysm: a complication of endoscopic ultrasound-guided hepaticogastrostomy

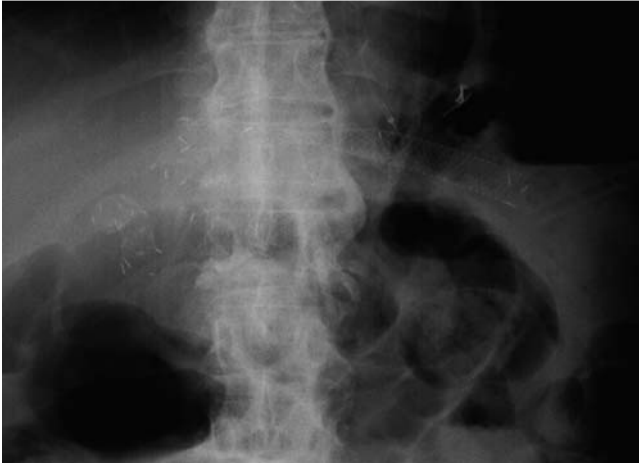

Fig. 1 Radiographic image showing the position of the self-expandable metal stent (SEMS) after endoscopic ultrasound (EUS)-guided hepaticogastrostomy in a patient with cancer of the pancreatic head who had previously undergone pancreaticoduodenectomy and hepaticojejunostomy.

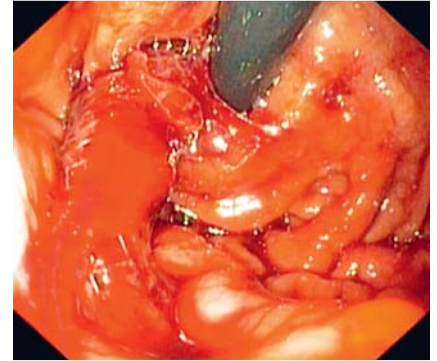


Fig. 2 View during an endoscopy performed 13 days after the hepaticogastrostomy showing active bleeding from self-expandable metal stent (SEMS).

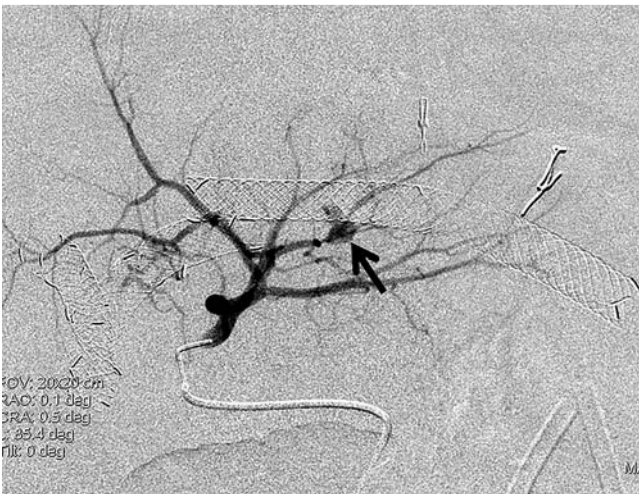

Fig. 3 Left hepatic angiogram showing a pseudoaneurysm (arrow) originating from a small branch of the left hepatic artery adjacent to the stent.

A 66-year-old man, who had undergone pylorus-preserving pancreaticoduodenectomy with Roux-en-Y hepaticojejunostomy for cancer of the pancreatic head, developed recurrent obstructive jaundice. He underwent balloon-assisted endoscopic retrograde cholangiopancreatography (ERCP) with insertion of bilateral self-expandable metal stents (SEMSs). Following this, he was admitted again because of recurrent cholangitis; on this occasion, he underwent endoscopic ultrasound (EUS)-guided hepaticogastrostomy (EUS-HG) for biliary drainage. The procedure was carried out under EUS and fluoroscopic guidance using a curvilinear echoscope (GF UC-140P; Olympus, Tokyo, Japan). After segment II of left intrahepatic

bile duct had been localized, a 19-gauge needle (EchoTip ultra; Cook Ireland, Limerick, Ireland) was used to puncture the bile duct and a 0.035-inch Jagwire was inserted. The tract was then dilated using a 7-Fr Soehendra stent retriever, followed by 8.5-Fr and 10-Fr Soehendra dilators. A 10×100-mm fully covered SEMS was deployed in a good position (● Fig. 1). The patient was discharged after an uneventful recovery.

He was admitted 13 days later because of massive bleeding and hypovolemic shock. After he had been resuscitated, he underwent esophagogastroduodenoscopy (EGD), which showed active bleeding from the gastric side of SEMS (● Fig. 2). He was therefore referred for angiography,

which showed a pseudoaneurysm of the segment II branch of the left hepatic artery adjacent to the mid portion of the SEMS (● Fig. 3). Superselective angiography was then performed with coil embolization using two pieces of 3×3.3-mm and 4×4-mm fiber coil (VortX Diamond-18; Boston Scientific, Natick, Massachusetts, USA) and the bleeding stopped (● Fig. 4).

Hepatic artery pseudoaneurysm is a rare cause of gastrointestinal bleeding. The causes of this condition are iatrogenic trauma, such as post-pancreatobiliary surgery, and inflammation, such as acute and chronic pancreatitis [1,2]. There are only a few case reports of this condition following ERCP with biliary stenting [3,4]. Endovascular embolization has been previously reported as an impressive treatment [5]. To the best of our knowledge, this is the first case of a hepatic artery pseudoaneurysm following EUS-HG to be reported. We hypothesize that this complication could have occurred during creation of the hepaticogastrostomy tract using the Soehendra stent retriever. An awareness of this life-threatening condition is very important to patient safety.

Endoscopy_UCTN_Code_CPL_1AK_2AD

Competing interests: None

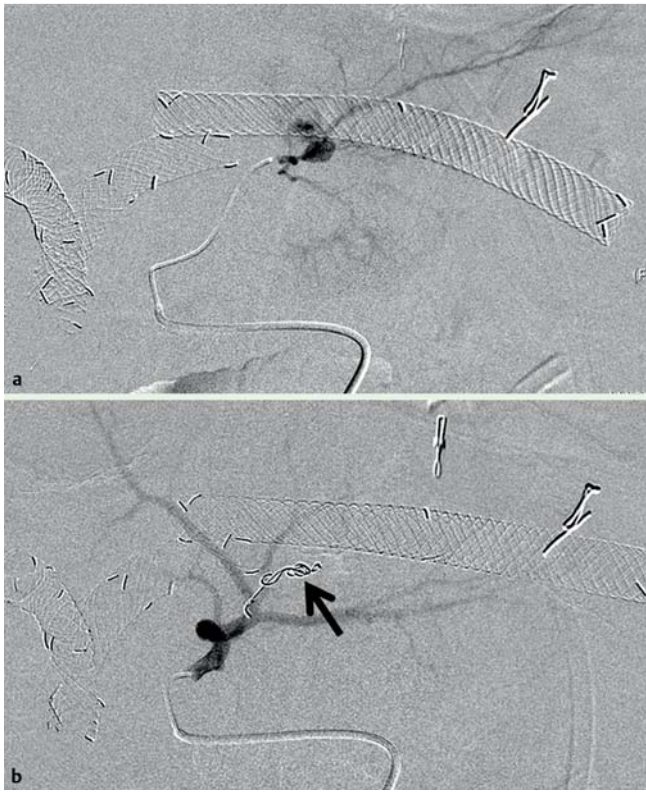


Fig. 4 Supraselective angiograms at the branch of left hepatic artery: **a** prior to the coil embolization; **b** after embolization showing the coils in position (arrow) and complete obliteration of the pseudoaneurysm.

**V. Prachayakul¹, S. Thamtorawat²,
C. Siripattanamongkol¹,
P. Thanathane¹**

¹ Siriraj GI Endoscopy Center, Siriraj Hospital, Bangkok, Thailand

² Interventional Unit, Radiology Department, Siriraj Hospital, Bangkok, Thailand

References

- 1 Yu YH, Sohn JH, Kim TY et al. Hepatic artery pseudoaneurysm caused by acute idiopathic pancreatitis. *World J Gastroenterol* 2012; 18: 2291–2294
- 2 Chen WC, Frenette C. Hepatic artery pseudoaneurysm: a rare cause of gastrointestinal bleeding in a post liver transplant patient. *J Gastrointest Liver Dis* 2012; 21: 125
- 3 Watanabe M, Shiozawa K, Mimura T et al. Hepatic artery pseudoaneurysm after endoscopic biliary stenting for bile duct cancer. *World J Radiol* 2012; 4: 115–120
- 4 Park JY, Ryu H, Bang S et al. Hepatic artery pseudoaneurysm associated with plastic biliary stent. *Yonsei Med J* 2007; 48: 546–548
- 5 Klauß M, Heye T, Stampfl U et al. Successful arterial embolization of a giant pseudoaneurysm of the gastroduodenal artery secondary to chronic pancreatitis with literature review. *J Radiol Case Rep* 2012; 6: 9–16

Bibliography

DOI <http://dx.doi.org/10.1055/s-0033-1344064>
Endoscopy 2013; 45: E223–E224
 © Georg Thieme Verlag KG
 Stuttgart · New York
 ISSN 0013-726X

Corresponding author

V. Prachayakul, MD
 Division of Gastroenterology
 Department of Internal Medicine
 Faculty of Medicine
 Siriraj Hospital, Mahidol University
 Bangkok 10700
 Thailand
 Fax: +66-2419-6101
 kaiyjr@gmail.com