

Endoscopic ultrasound-guided diagnosis and management of an unusual gastric submucosal lesion – gastric wall abscess

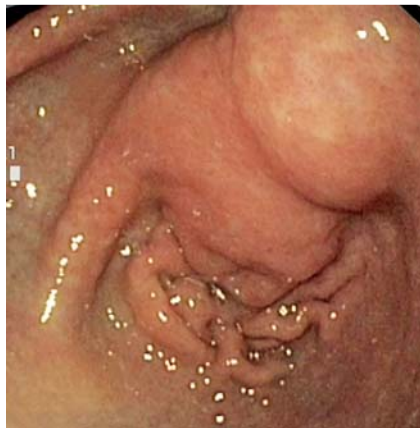

Fig. 1 Submucosal bulge in the gastric antrum in a 65-year-old alcoholic man with upper abdominal pain, early satiety and nausea of 6 weeks' duration.

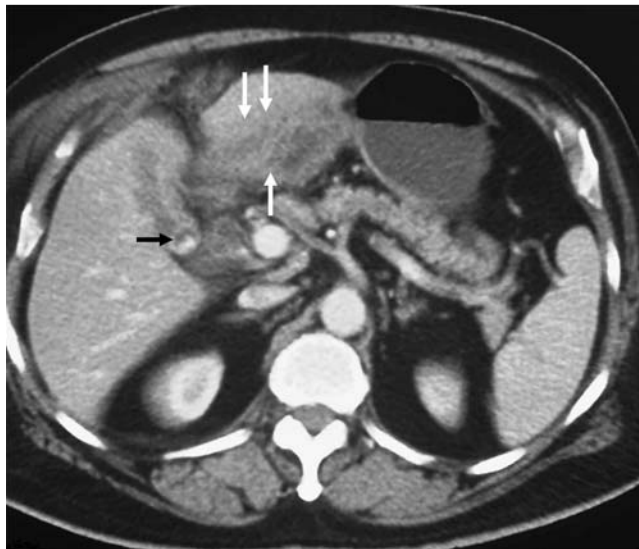


Fig. 2 Contrast-enhanced computed tomography (CECT) abdomen showing thickening of the antral wall (white arrows) and gallbladder stone (black arrow).

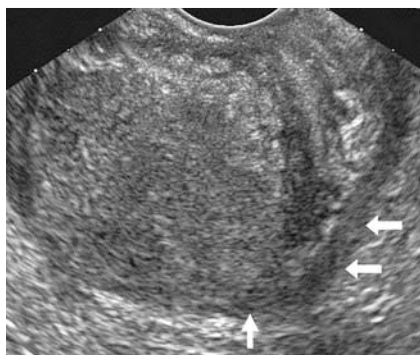


Fig. 3 Endoscopic ultrasound (EUS) showing a submucosal lesion in the antrum. Muscularis propria is seen around the lesion (white arrows).

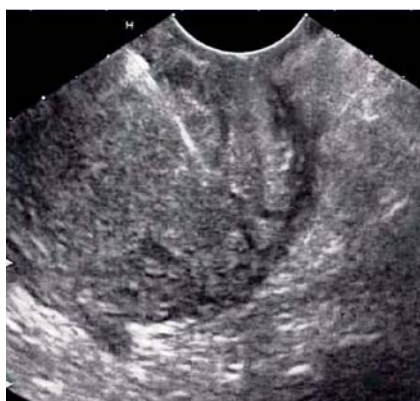

Fig. 4 EUS-guided fine needle aspiration.

A 65-year-old alcoholic man presented with upper abdominal pain accompanied by early satiety and nausea of 6 weeks' duration. He had a history of loss of weight and he also had a low-grade fever for the past 7 days. Examination revealed a vague lump in the right upper abdomen. The patient had undergone gastroscopy at the referring center, where a mass in the antrum was reported with inconclusive endoscopic biopsy. We performed a repeat endoscopy, which revealed a submucosal lesion in the antrum (▶ Fig. 1). Contrast-enhanced computed tomography (CECT) of abdomen showed gallbladder stones with thickening of the antral wall (▶ Fig. 2). Endoscopic ultrasound (EUS) revealed a well-defined, heterogeneously echo-textured lesion of 2.5 cm diameter in the gastric wall (▶ Fig. 3). EUS-guided fine needle aspiration from the lesion yielded purulent material full of inflammatory cells (▶ Fig. 4). The CECT was reviewed with coronal reconstruction, revealing thickening of the gallbladder wall adjacent to the antrum, and the possibility of a sealed gallbladder perforation was considered (▶ Fig. 5). The patient was treated with intravenous antibiotics and EUS-guided drainage of the gastric abscess was done using a nasocystic drain (▶ Video 1). The patient's condition showed gradual

improvement and repeat CECT abdomen revealed resolution of the gastric wall lesion (▶ Fig. 6). After 6 weeks he underwent cholecystectomy, and histopathological examination of the gallbladder revealed features of chronic cholecystitis with deep ulcers and transmural inflammation. The patient's postoperative course was uneventful and he remained asymptomatic over a follow-up of 6 months. Gastric wall abscess is an unusual and rare infection of the stomach with most cases being diagnosed at laparotomy [1]. EUS is an useful investigation for evaluating intramural lesions [2]. On EUS, gastric wall abscesses are usually seen as a predominantly hypoechoic lesion located mainly in the muscularis propria or the submucosa layer [1,3]. However, as there are no specific EUS findings it is difficult to distinguish them from intramural tumors [1]. EUS-guided aspiration can help in arriving at correct diagnosis as in the present case. Surgery along with broad-spectrum antibiotics has been the tradi-

Video 1

EUS-guided transmural drainage of the gastric abscess. Balloon dilation of the transmural tract is being done.

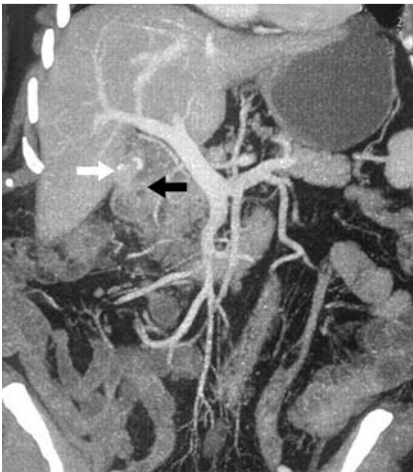

Fig. 5 Reconstructed contrast-enhanced computed tomography (CECT) image shows gallbladder stones (white arrow), the thickened gallbladder wall, and the adjoining gastric wall (black arrow).

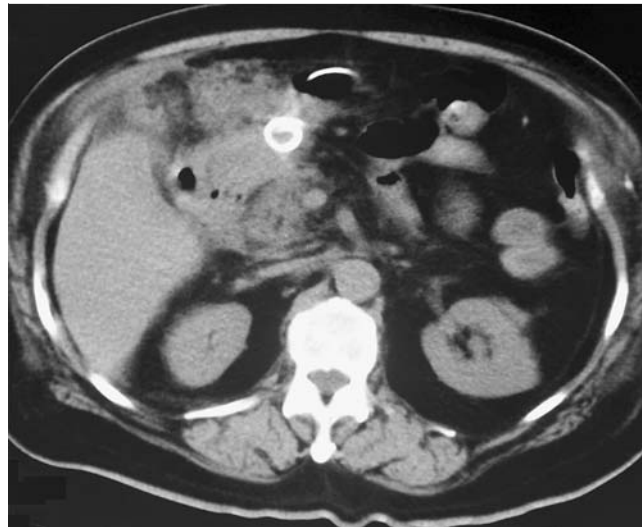


Fig. 6 Post EUS-guided drainage contrast-enhanced computed tomography (CECT) view showing pigtail of the nasocystic drain in the abscess cavity.

tional method of treating gastric wall abscess [4]. Recently, both percutaneous drainage and endoscopic drainage by resecting the mucosa using a snare or a needle-knife, along with a course of antibiotics, have been reported to be successful [1].

Endoscopy_UCTN_Code_CCL_1AF_2AD

Competing interests: None

S. S. Rana¹, D. K. Bhasin¹, C. Rao¹, R. Gupta²

¹ Department of Gastroenterology, Post Graduate Institute of Medical Education and Research (PGIMER), Chandigarh, India

² Department of Surgery, Post Graduate Institute of Medical Education and Research (PGIMER), Chandigarh, India

4 Kim GY, Ward J, Hennessey B et al. Phlegmonous gastritis: case report and review. *Gastrointest Endosc* 2005; 61: 168

Bibliography

DOI <http://dx.doi.org/10.1055/s-0032-1326451>
Endoscopy 2013; 45: E136–E137
 © Georg Thieme Verlag KG
 Stuttgart · New York
 ISSN 0013-726X

Corresponding author

Dr S. S. Rana

Department of Gastroenterology
 Post Graduate Institute of Medical Education and Research (PGIMER)
 Chandigarh – 160 012
 India
 Fax: +91-172-2744401
 drsurinderrana@yahoo.co.in

References

- 1 Yang CW, Yen HH. Endoscopic sonography in the diagnosis and treatment of a gastric wall abscess: a case report and review of the literature. *J Clin Ultrasound* 2012; 40: 105–108
- 2 Rana SS, Bhasin DK, Rao C. Gastric outlet obstruction caused by duodenal intramural pseudocyst. *Ann Gastroenterol* 2013; 26: 71
- 3 Choong NW, Levy MJ, Rajan E et al. Intramural gastric abscess: case history and review. *Gastrointest Endosc* 2003; 58: 627