

TC-325 application leading to transient obstruction of a post-sphincterotomy biliary orifice

TC-325 (Hemospray, Cook Medical Inc., Bloomington, Indiana, USA), a novel endoscopic hemostatic powder has been approved in many countries for nonvariceal gastrointestinal bleeding. It consists of a proprietary inorganic powder, which, when put in contact with moisture, becomes coherent and adhesive, creating a mechanical barrier and effecting hemostasis. Preliminary results in benign and malignant upper and lower gastrointestinal bleeding are promising [1–4]. Optimal indications and technical limitations are still being characterized [5].

We recently treated a patient presenting with hematemesis 12 hours after choledocholithiasis removal, in whom endoscopy confirmed oozing from the sphincterotomy site. Hemostasis occurred immediately following application of 5 g (1/4 canister) Hemospray; however, resulting arrest of bile flow and caking of the orifice with the powder were noted. Biliary patency was quickly restored with vigorous water irrigation and prodding open of the papillotomy orifice with a sphincterotome tip; prolonged hemostasis was achieved with epinephrine injection. Subsequent follow-up at 4 months after the procedure did not reveal any clinical stigmata of gastrointestinal bleeding (● Fig. 1).

TC-325 appears highly effective in achieving initial hemostasis [1–5], yet technical difficulties related to the first-generation delivery system have included blockage of the 10-Fr catheter or the accessory channel of the endoscope if there is premature contact with moisture. Initial flushing of the accessory channel with air using a syringe before introduction of the catheter is thus recommended. Additional limitations include kinking of the delivery system's soft catheter sheath when the endoscope is looped or positioned over a duodenoscope elevator. Recently, 7-Fr and 10-Fr catheters have been marketed as part of a second-generation delivery system. TC-325 powder application so far appears quite safe, with no reported bowel obstruction or systemic embolization [1–5]. Here we have reported transient biliary obstruction following successful use of Hemospray in post-sphincterotomy hemorrhage. Caution should therefore be taken when applying hemostatic powders near small orifices adjacent to the bowel lumen.

Endoscopy_UCTN_Code_CPL_1AK_2AI

Competing interests: Alan Barkun received research funding and is a consultant for Cook Inc., Sarvee Moosavi and Yen-I Chen do not have any conflict of interest to report.

S. Moosavi¹, Y. I. Chen¹, A. N. Barkun^{1,2}

¹ Divisions of Gastroenterology, McGill University Health Centre, McGill University, Montréal, Québec, Canada

² Epidemiology Biostatistics and Occupational Health, McGill University Health Centre, McGill University, Montréal, Québec, Canada

References

- 1 Sung JJ, Luo D, Wu JC et al. Early clinical experience of the safety and effectiveness of Hemospray in achieving hemostasis in patients with acute peptic ulcer bleeding. *Endoscopy* 2011; 43: 291–295
- 2 Chen YI, Barkun AN, Soulellis C et al. Use of the endoscopically applied hemostatic powder TC-325 in cancer-related upper GI hemorrhage: preliminary experience (with video). *Gastrointest Endosc* 2012; 75: 1278–1281
- 3 Soulellis C, Carpenter S, Chen YI et al. Lower gastrointestinal hemorrhage controlled with endoscopically applied TC-325: (with videos). *Gastrointest Endosc* Jan 2, 2013 [Epub ahead of print]
- 4 Morris A, Smith L, Stanley A et al. 284 Hemospray for non-variceal upper gastrointestinal bleeding: results of the seal dataset (survey to evaluate the application of Hemospray in the luminal tract). *Gastrointest Endosc* 2012; 75: AB133–AB134
- 5 Moosavi S, Barkun A. Case-series: utility of Hemospray™ in management of benign upper and lower GI bleed of various etiologies: preliminary experience. *Can J Gastroenterol* 2012; 26: A081

Bibliography

DOI <http://dx.doi.org/10.1055/s-0032-1326370>
Endoscopy 2013; 45: E130
 © Georg Thieme Verlag KG
 Stuttgart · New York
 ISSN 0013-726X

Corresponding author

Dr A. Barkun
 Division of Gastroenterology
 McGill University Health Centre
 Montreal General Hospital Site
 1650 Cedar Avenue, Room D7-346
 Montréal
 Canada H3G 1A4
 Fax: +514-834-8531
alan.barkun@muhc.mcgill.ca

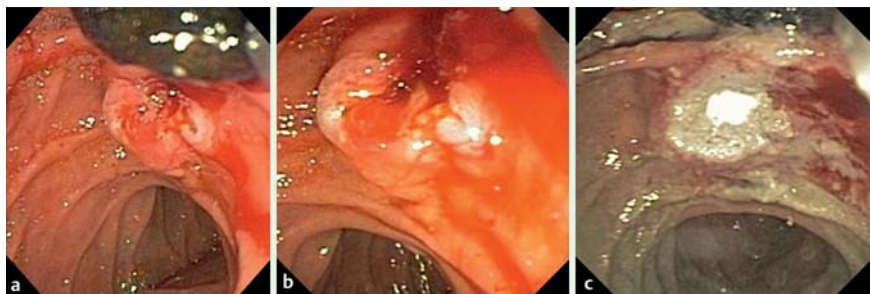


Fig. 1 a Endoscopic image of the bleeding site post endoscopic retrograde cholangiopancreatography (ERCP) sphincterotomy in a patient presenting with hematemesis after choledocholithiasis removal. Note the bile duct stone in the top right hand corner of the image. b Bleeding obvious at the sphincterotomy site. c Sphincterotomy site covered by TC-325 powder (light is shining off TC-325 laden surface). Note the complete obstruction of the biliary opening with no bile flow.