

Delayed perforation after intralesional triamcinolone injection for esophageal stricture following endoscopic submucosal dissection

Stricture is a major complication of wide endoscopic mucosal resection (ESD) of the esophagus and its management requires multiple balloon dilation sessions [1]. Endoscopic intralesional injection of triamcinolone is being used as a prophylactic treatment in patients in whom wide areas of mucosa were removed with ESD [2, 3].

A 60-year-old man developed dysphagia 1 month after ESD for superficial esophageal carcinoma. Esophagogastroduodenoscopy (EGD) showed a stricture in the mid-esophagus (Fig. 1), which did not allow the endoscope to pass through. The patient then underwent endoscopic balloon dilation. The surface of the muscularis propria was partially exposed but there was no endoscopic evidence of esophageal perforation just after the dilation. Subsequently, 1 mL (10 mg) aliquots of triamcinolone (Kenakort A 40 mg/5 mL, Bristol-Myers Squibb, Tokyo, Japan) were injected into the submucosa, until a total amount of 100 mg of triamcinolone had been administered. A few punctures penetrated the muscularis propria (Fig. 2). After 24 hours of treatment, the patient had chest pain and fever. Chest radiography performed by his general physician revealed pneumomediastinum, and he was immediately admitted in our hospital. A chest computed tomography (CT) scan confirmed pneumomediastinum and periesophageal fluid collection. EGD showed a large esophageal perforation at the injection site (Fig. 3). The patient underwent surgery, and extensive esophageal perforation was seen in the resected esophagus. We suspect that triamcinolone injected into the muscularis propria might have caused tissue damage and resulted in delayed perforation and periesophageal abscess [4]. Prophylactic injections of intralesional steroids after creation of wide mucosal defects with endoscopic mucosal resection/ESD are increasingly performed in Japan; however, the hazardous complication presented here should be kept in mind and direct puncture of the muscularis propria should be avoided.

Endoscopy_UCTN_Code_CPL_1AH_2AZ

Competing interests: None

T. Yamashina¹, N. Uedo¹, M. Fujii¹, R. Ishihara¹, M. Mikamori², M. Motoori², M. Yano², H. Iishi¹

¹ Department of Gastrointestinal Oncology, Osaka Medical Center for Cancer and Cardiovascular Diseases, Osaka, Japan

² Department of Gastrointestinal Surgery, Osaka Medical Center for Cancer and Cardiovascular Diseases, Osaka, Japan

References

- 1 Katada C, Muto M, Manabe T et al. Esophageal stenosis after endoscopic mucosal resection of superficial esophageal lesions. *Gastrointest Endosc* 2003; 57: 165–169
- 2 Hashimoto S, Kobayashi M, Takeuchi M et al. The efficacy of endoscopic triamcinolone injection for the prevention of esophageal stricture after endoscopic submucosal dissection. *Gastrointest Endosc* 2011; 74: 1389–1393
- 3 Hanaoka N, Ishihara R, Takeuchi Y et al. Intralesional steroid injection to prevent stricture after endoscopic submucosal dissection for esophageal cancer: a controlled prospective study. *Endoscopy* 2012, Aug 28. [Epub ahead of print]
- 4 Rajan E, Gostout C, Feitoza A et al. Widespread endoscopic mucosal resection of the esophagus with strategies for stricture prevention: a preclinical study. *Endoscopy* 2005; 37: 1111–1115

Bibliography

DOI <http://dx.doi.org/10.1055/s-0032-1326253>
Endoscopy 2013; 45: E92
 © Georg Thieme Verlag KG
 Stuttgart · New York
 ISSN 0013-726X

Corresponding author

N. Uedo
 Department of Gastrointestinal Oncology
 Osaka Medical Center for Cancer and Cardiovascular Disease
 1-3-3 Nakamichi Higashinari-ku
 Osaka 537-8511
 Japan
 Fax: +81-6-69814067
 uedou-no@mc.pref.osaka.jp

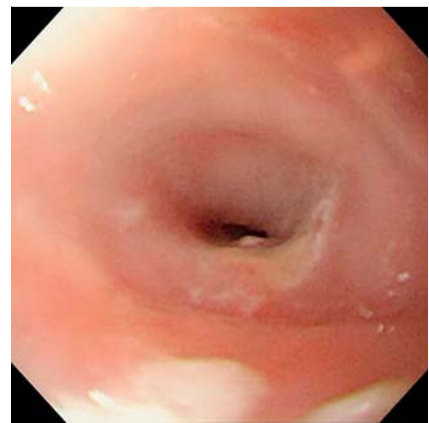


Fig. 1 Esophagogastroduodenoscopy (EGD) showing stricture in the mid-esophagus in a 60-year-old man with dysphagia after endoscopic submucosal dissection (ESD) for superficial esophageal carcinoma.

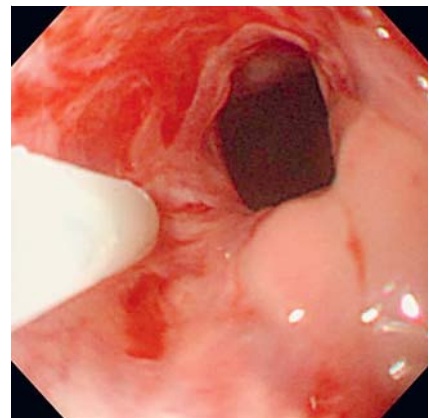


Fig. 2 Triamcinolone was injected into the submucosal tissue; a few of the punctures penetrated the muscularis propria.

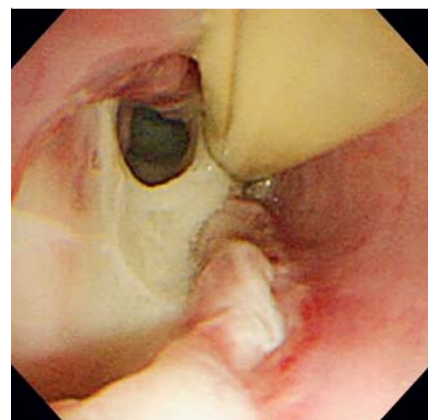


Fig. 3 Esophagogastroduodenoscopy (EGD) showing large esophageal perforation.