

Application of endoscopic double illumination technique for management of anastomotic site membranes

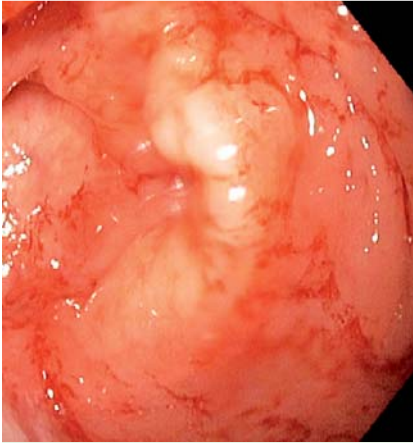


Fig. 1 Colonoscopy in a 87-year-old woman showing a membrane at the colorectal anastomosis site.

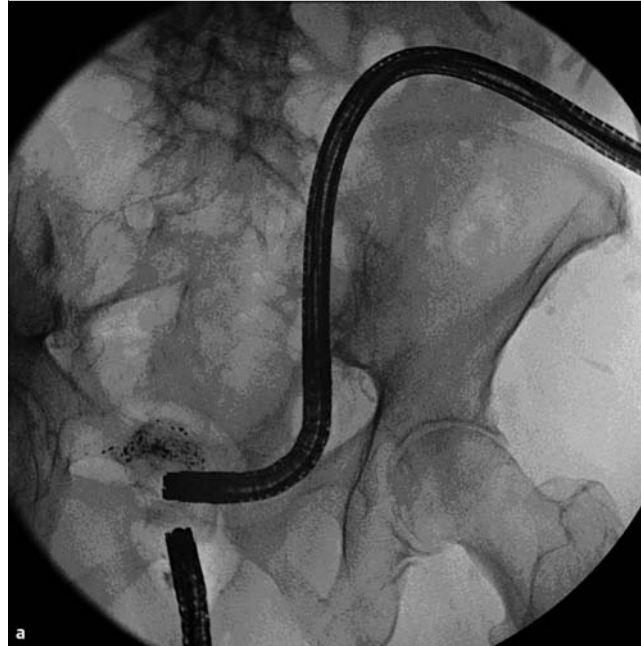
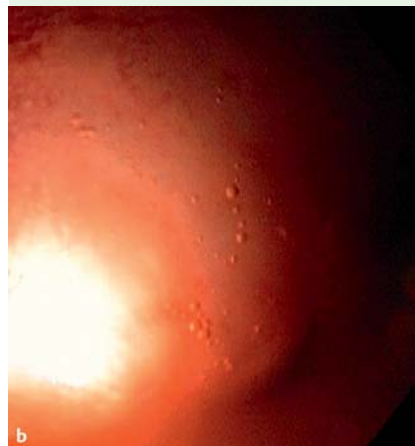


Fig. 2 a Fluoroscopic images of the lower (from anus) and upper (from colostomy site) scopes. b Transillumination.



Colonoscopy in a 87-year-old woman showed a friable, erythematous rectosigmoid mass approximately 18 cm from the anal verge, engulfing one-half to two-thirds of the circumference. Multiple biopsy samples were obtained, which were reported as carcinoma in situ. Laparoscopic colectomy with colorectal anastomosis and diverting loop ileostomy was done. Repeat colonoscopy showed complete closure of the anastomosis site by a membrane (◉ Fig. 1). Two GIF H-180 esophagoduodenoscopy (EGD) scopes (Olympus, New York, USA) were simultaneously passed from the anus (lower scope) and the colostomy site (upper scope) under fluoroscopic guidance and advanced to the rectum pouch and distal end of the colon, respectively (◉ Fig. 2a). The light source from both the scopes was easily seen on both sides (◉ Fig. 2b). The mucosal wall at the area of the previous colorectal anastomosis was cannulated using an endo-knife under direct proximal and distal visualization via the lower scope (◉ Fig. 3a). Then, using the lower scope again, a through-the-scope balloon was passed over the guide wire and dilation was carried out up to a maximum diameter of 8 mm

(◉ Fig. 3b). Serial dilations were done up to 20 mm (◉ Fig. 3c). Complete closure of an anastomotic site by mucosal membranes is a rare finding, for which endoscopic double illumination technique [1–3] is a safe and convenient procedure, especially in patients who are already surgically diverted.

Endoscopy_UCTN_Code_TTT_1AQ_2AF

Competing interests: None

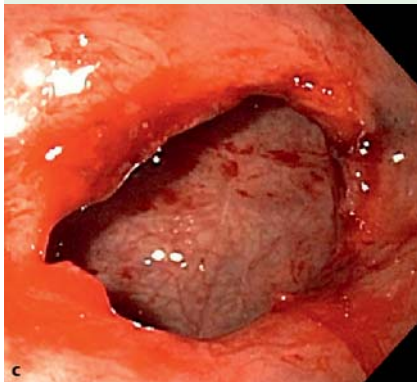
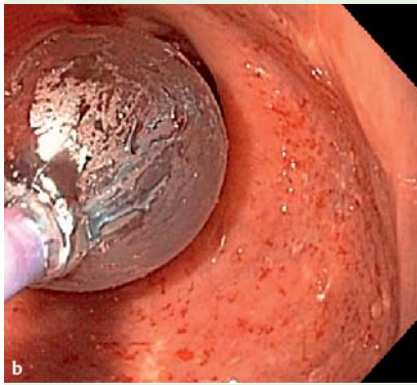
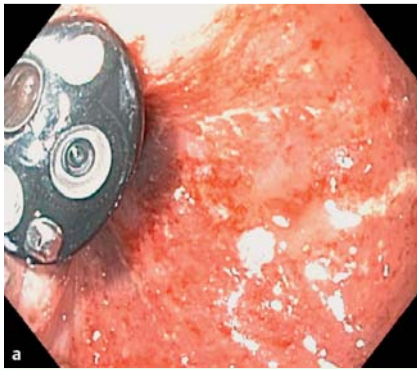


Fig. 3 a Membrane incised and lower scope visualized. b Balloon dilation. c Dilation to 20 mm.

A. Rafiq¹, H. Nemat², J. C. Morgan², R. Sabbagh³

¹ Department of Internal Medicine, Wyckoff Heights Medical Center, Brooklyn, New York, USA

² Department of Gastroenterology, Harlem Hospital Center, New York, USA

³ Department of Surgery, Harlem Hospital Center, New York, USA

References

- 1 Laucks SS. Method for re-establishing patency of a completely closed colorectal anastomosis. *Dis Colon Rectum* 1993; 36: 299–300
- 2 Koo JS, Park SM, Yim HJ et al. Ileorectal anastomotic obstruction treated with a dual endoscopic transillumination technique. *Endoscopy* 2009; 41: E259
- 3 Anselme PF. Management of colorectal anastomotic membrane by an endoscopic double-illumination technique. *ANZ J Surg* 2006; 76: 270–272

Bibliography

DOI <http://dx.doi.org/10.1055/s-0032-1326243>
Endoscopy 2013; 45: E75–E76
 © Georg Thieme Verlag KG
 Stuttgart · New York
 ISSN 0013-726X

Corresponding author

A. Rafiq

Department of Internal Medicine
 Wyckoff Heights Medical Center
 374 Stockholm Street, Brooklyn
 NY 11237
 USA
 giresearch2011@hotmail.com