

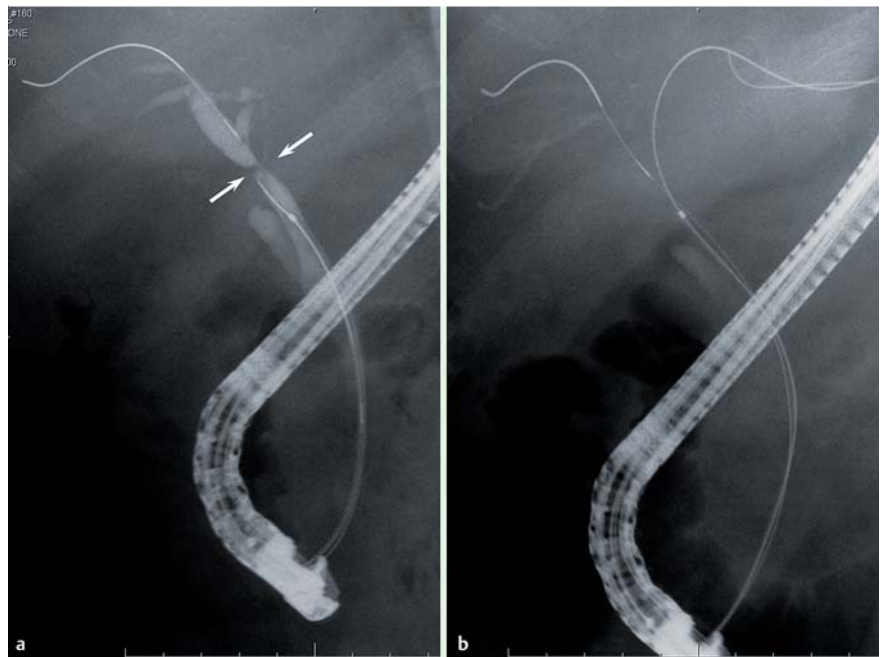
## Resolution of a refractory severe biliary stricture using a diathermic sheath

Endoscopic treatment of postoperative bile duct strictures (BDSs) is safe and effective [1]. However, when the BDS is severe and only the guide wire can be passed through it, stent placement is not possible. We describe a case of refractory, severe postoperative hilar BDS that was successfully treated using a diathermic sheath.

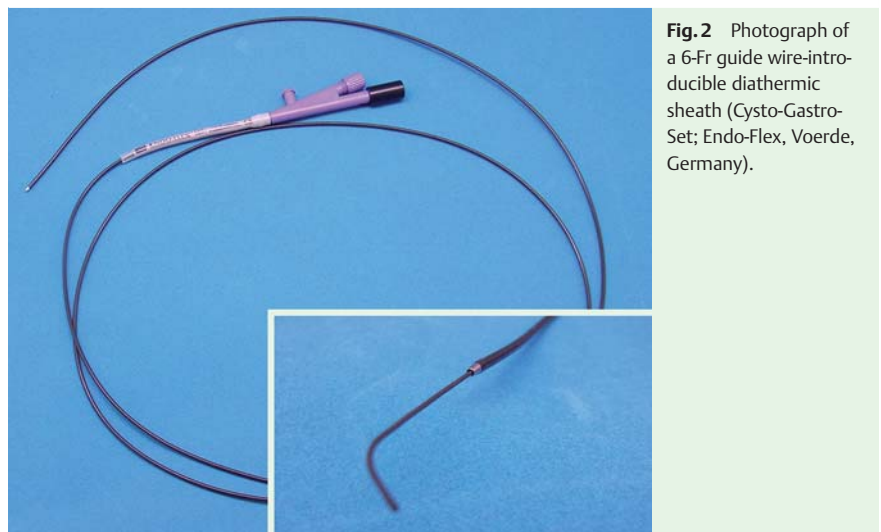
A 47-year-old man was admitted to our department with recurrent cholangitis. He had previously undergone surgical treatment for gallbladder cancer in 2009, which was followed by regular placement of 7-Fr tube stents for BDS, until the stent was removed at the request of the patient, despite the fact that endoscopic retrograde cholangiopancreatography (ERCP) still revealed a BDS. As a result, 17 months later he developed cholangitis. An ERCP following admission revealed severe hilar BDSs (▶ **Fig. 1 a**). Although a 0.035-inch guide wire was successfully advanced across the left hepatic BDS (▶ **Fig. 1 b**), it was not possible to pass a tapered catheter, Soehendra biliary dilation catheter, or stent retriever (Wilson–Cook, Winston-Salem, North Carolina, USA; ▶ **Video 1**).

It was therefore decided to incise the BDS using a 6-Fr diathermic sheath (Cysto-Gastro-Set; Endo-Flex, Voerde, Germany; ▶ **Fig. 2**), which was advanced over the guide wire to the level of the left hepatic BDS (▶ **Fig. 3 a**; ▶ **Video 1**). An incision was made in the BDS using an electro-surgical generator (▶ **Fig. 3 b**, ▶ **Video 1**) and a 5-Fr nasobiliary tube was placed. The patient experienced no serious complications. An ERCP 5 days later revealed resolution of the left hepatic BDS (▶ **Fig. 4 a**), and 7-Fr plastic stents were successfully placed (▶ **Fig. 4 b**).

Diathermic sheaths have been used previously to enlarge the channel between the stomach or duodenum and a pancreatic pseudocyst, the pancreatic duct or the gallbladder [2–5]. To our knowledge, this is the first report of a refractory, severe postoperative BDS successfully treated using a diathermic sheath. Although further study is required, this approach has great potential for selected patients with refractory BDS.



**Fig. 1** Radiographic images showing: **a** a severe hilar bile duct stricture in a 47-year-old man previously treated for gallbladder cancer; **b** the hydrophilic, 0.035-inch guide wire that was successfully advanced across the left hepatic bile duct stricture.



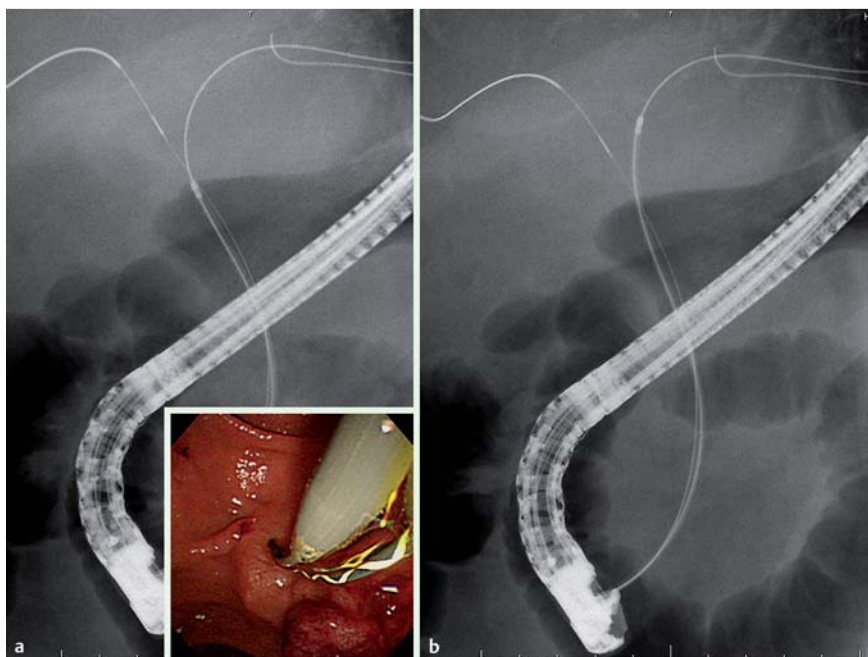
**Fig. 2** Photograph of a 6-Fr guide wire-introducible diathermic sheath (Cysto-Gastro-Set; Endo-Flex, Voerde, Germany).

### Video 1

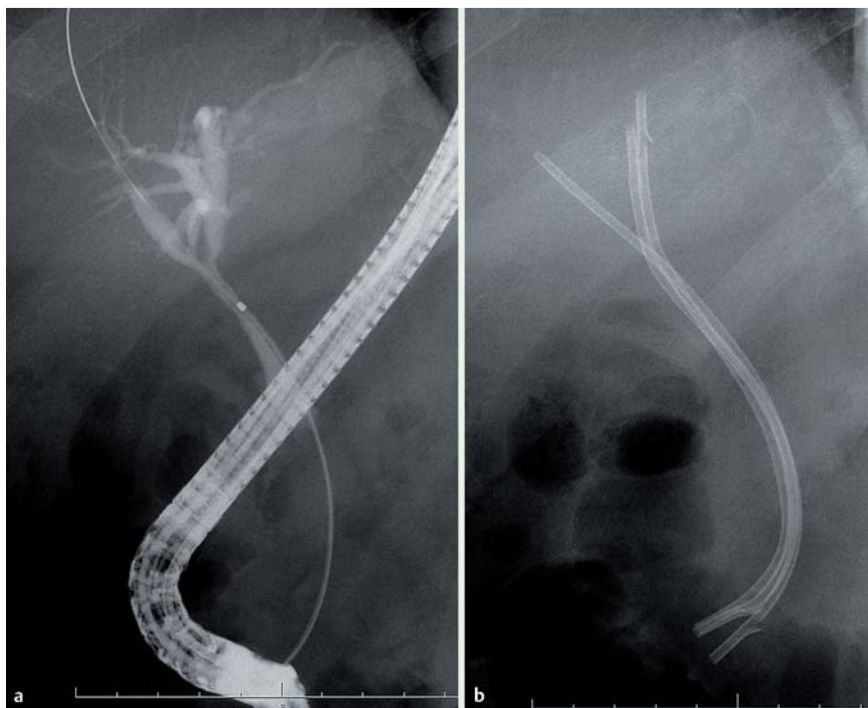
Video showing that catheters could not be advanced over the 0.035-inch guide wire; therefore, a 6-Fr diathermic sheath is advanced to the level of the left hepatic bile duct stricture and an incision is made using an electro-surgical generator.

Endoscopy\_UCTN\_Code\_TTT\_1AR\_2AG

**Competing interests:** None



**Fig. 3** Radiographic images showing: **a** the diathermic sheath being advanced over the guide wire to the level of the bile duct stricture (inset: endoscopic view of the diathermic sheath being advanced over the guide wire into the bile duct); **b** the diathermic sheath after its passage through the stricture in the left hepatic bile duct.



**Fig. 4** Radiographic images taken during an endoscopic retrograde cholangiopancreatography (ERCP) performed 5 days after treatment showing: **a** resolution of the left hepatic bile duct stricture; **b** the multiple 7-Fr plastic stents that were successfully placed.

**H. Kawakami<sup>1</sup>, M. Kuwatani<sup>1</sup>, K. Eto<sup>1</sup>,  
T. Kudo<sup>1</sup>, Y. Abe<sup>1</sup>, S. Kawahata<sup>1</sup>,  
M. Kato<sup>2</sup>**

<sup>1</sup> Department of Gastroenterology,  
Hokkaido University Graduate School  
of Medicine, Sapporo, Japan

<sup>2</sup> Division of Endoscopy, Hokkaido  
University Hospital, Sapporo, Japan

## References

- 1 François E, Kahaleh M, Giovannini M et al. EUS-guided pancreaticogastrostomy. *Gastrointest Endosc* 2002; 56: 128–133
- 2 Hookey LC, Debroux S, Delhaye M et al. Endoscopic drainage of pancreatic-fluid collections in 116 patients: a comparison of etiologies, drainage techniques, and outcomes. *Gastrointest Endosc* 2006; 63: 635–643
- 3 Giovannini M. Therapeutic Endoscopic Ultrasonography in Pancreatic Malignancy. Is the ERCP Passè? *JOP* 2004; 5: 304–307
- 4 Kwan V, Eisendrath P, Antaki F et al. EUS-guided cholecystenterostomy: a new technique (with videos). *Gastrointest Endosc* 2007; 66: 582–586
- 5 Sübtel JC, Betes M, Muñoz-Navas M. Gallbladder drainage guided by endoscopic ultrasound. *World J Gastrointest Endosc* 2010; 2: 203–209

## Bibliography

**DOI** <http://dx.doi.org/10.1055/s-0031-1291675>  
*Endoscopy* 2012; 44: E119–E120  
 © Georg Thieme Verlag KG  
 Stuttgart · New York  
 ISSN 0013-726X

## Corresponding author

**H. Kawakami, MD PhD**  
 Department of Gastroenterology  
 Hokkaido University Graduate School of Medicine  
 Kita 15, Nishi 7, Kita-ku  
 Sapporo 060-8638  
 Japan  
 Fax: +81-11-7067867  
 hiropon@med.hokudai.ac.jp