

Esthesioneuroblastoma in an HIV-1 Infected Patient: Case Report

Enrico Maria Trecarichi, M.D.,¹ Jacopo Galli, M.D.,² Enrica Tamburrini, M.D.,¹ Katleen de Gaetano Donati, M.D.,¹ Giancarlo Scoppettuolo, M.D.,¹ Cesare Colosimo, M.D.,³ Francesco Pierconti, M.D.,⁴ Gaetano Paludetti, M.D.,² and Mario Tumbarello, M.D.¹

ABSTRACT

Esthesioneuroblastoma (ENB) is an uncommon malignant tumor derived from the specialized neuroepithelium of the upper nasal cavity. The largest case series and meta-analyses suggest the combination of surgery and radiotherapy as the gold standard treatment for ENB. However, an increasing number of case series have reported excellent survival and few complications with minimally invasive endoscopic resection (MIER) in conjunction with radiotherapy of ENB in early stages of the disease. In this case report, the authors describe the first case of ENB in a young adult man who was human immunodeficiency virus (HIV)-1 and Hepatitis C virus (HCV) coinfecting. The authors discuss all the aspects of this rare disease, focusing on treatment options and prognosis.

KEYWORDS: Esthesioneuroblastoma, human immunodeficiency virus-1 infection, Hepatitis C virus infection, non-acquired immunodeficiency syndrome-related cancer, treatment and prognosis

Esthesioneuroblastoma (ENB) is an uncommon malignant tumor derived from the specialized neuroepithelium of the upper nasal cavity. Since its first description in 1924, almost 1000 cases of this tumor have been reported, mostly as single case reports.¹ ENB accounts for ~5% of intranasal cancers and shows a variety of symptoms and a heterogeneous histopathology.^{1,2} No data are presently available about either causal factors or factors associated with a poor prognosis. The largest case series and meta-analyses suggest the combination of surgery and radiotherapy as the gold standard treatment for ENB.¹⁻⁵

It has been reported that the incidence of malignancies is increased among individuals who are infected with human immunodeficiency virus (HIV). In recent

years, while a significant decrease in acquired immunodeficiency syndrome (AIDS) defining cancers such as Kaposi sarcoma has been reported, patients infected with HIV remain at increased risk for developing non-AIDS-related solid and hematological malignancies, an increasingly prominent cause of death in the later stages of AIDS.⁶⁻⁹

The oncogenic role of Hepatitis C virus (HCV) infection in hepatocellular carcinoma has been definitely established.¹⁰ In addition, a possible role of this virus in the pathogenesis of extrahepatic neoplastic disorders (B-cell malignancies) has been also suggested.¹¹

We describe here, to the best of our knowledge, the first case of ENB in a young adult man who was HIV-1 and HCV coinfecting.

¹Institutes of Infectious Diseases, ²Otolaryngology, ³Bio-images, and Radiological Sciences, and ⁴Pathological Anatomy, Catholic University of the Sacred Heart, Rome, Italy.

Address for correspondence and reprint requests: Mario Tumbarello, M.D., Istituto di Clinica delle Malattie Infettive, Università Cattolica del Sacro Cuore, Largo A. Gemelli 8, 00168 Roma, Italy (e-mail: tumbarello@rm.unicatt.it).

Skull Base Rep 2011;1:129-132. Copyright © 2011 by Thieme Medical Publishers, Inc., 333 Seventh Avenue, New York, NY 10001, USA. Tel: +1(212) 584-4662.

Received: March 25, 2011. Accepted: April 26, 2011. Published online: July 22, 2011.

DOI: <http://dx.doi.org/10.1055/s-0031-1284208>.
ISSN 2157-6971.

CASE REPORT

The patient was a 36-year-old man with a history of previous intravenous drug abuse; he had been HIV-1 seropositive for 14 years and had never experienced opportunistic infections. The CD4 cell count had always been higher than $350/\text{mm}^3$. The antiretroviral therapy was started 12 years after the diagnosis of HIV-1 infection, and HIV-1 viral load was consistently undetectable during the past 5 years. Our patient was also affected by chronic HCV infection in follow-up since 1992 and characterized by a relatively low HCV viral

load ($\sim 750,000$ UI/mL), genotype 3b, and low-moderate elevation of liver function tests. In April 2004, the patient presented an acute onset of right maxillary swelling, for which he was admitted to our Infectious Diseases ward. Magnetic resonance imaging (MRI) revealed a tumor filling almost completely the upper right nasal cavity and ethmoid, reaching the cribriform plate but without intracranial involvement; there was initial involvement of the medial wall of the right orbit, with displacement of the retrobulbar orbital fat but without evidence of extension into the orbit (Fig. 1).

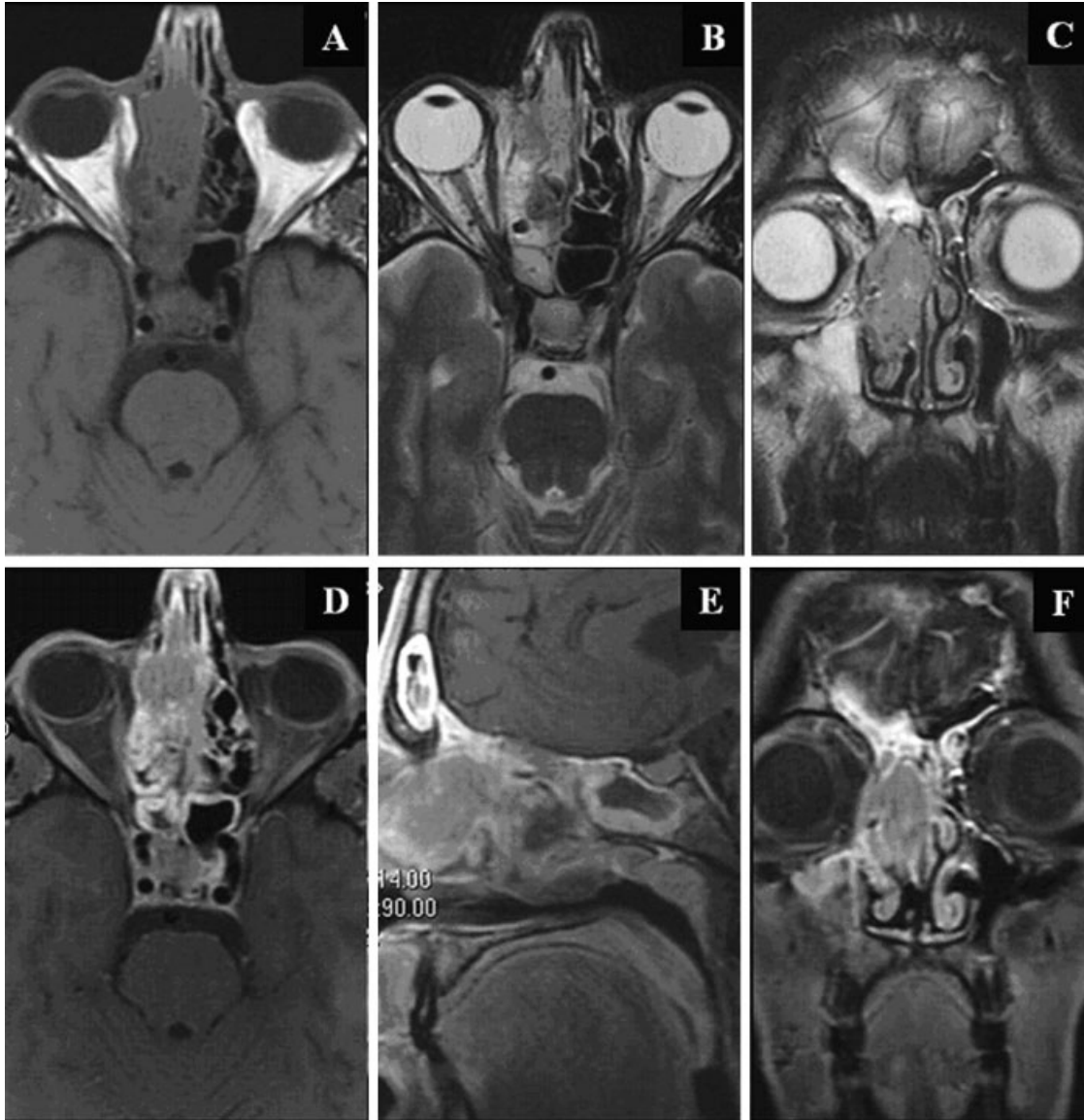


Figure 1 Preoperative MRI: (A) Axial T1-weighted images without contrast; (B) Axial T2-weighted images; (C) Coronal T2-weighted images; (D) Axial fat-saturated T1-weighted images after contrast; (E) Sagittal fat-saturated T1-weighted images after contrast; (F) Coronal fat-saturated T1-weighted images after contrast. The tumor fills almost completely the upper right nasal cavity and ethmoid, reaching the cribriform plate but without intracranial involvement; there was initial involvement of the medial wall of the right orbit, with displacement of the retrobulbar orbital fat but without evidence of extension into the orbit. The tumor showed relatively low signal on T2-weighted images and moderate enhancement due to its high cellularity. Combination of T2-weighted and postcontrast fat-saturated T1-weighted images allowed good differentiation between the tumor itself and the associated reactive/obstructive findings in the right maxillary, frontal, sphenoid sinuses.

No regional and systemic metastases were found at that moment by computed tomography (CT) evaluation. Histological examination of the mass revealed diffuse sheets of neoplastic cells with lobular pattern and prominent background of capillaries, but little intervening stroma. The neoplastic cells had high nucleus-to-cytoplasm ratio and often showed rosettes formation. Scattered and rare mitoses were observed, there was no necrotic area present. Immunohistochemical staining showed that the tumor was positive for synaptophysin, neuron-specific enolase, chromogranin, and CD56, and negative for keratin, lymphoid markers, and epithelial membrane antigen; some S-100 protein-positive sustentacular cells were also seen. On the basis of these features, a diagnosis of ENB was made. According to Hyams' histopathological grading,¹ the tumor was classified as grade II. Based on staging classification systems of Kadish and Dulguerov,¹ tumor was classified as stage B and T2N0M0, respectively. Because of stage and comorbidities, patient underwent a minimally invasive endoscopic resection (MIER) of the tumor by means of antrostomy, ethmoidectomy, and sphenoidectomy.

Subsequently, the patient received 55 Gy of external beam radiotherapy on the resected area from the nasal cavity to the adjacent meninges over a 6-week period and chemotherapy with cisplatin (three cycles of 40 mg/m² per day for 5 days every 3 weeks). A cranial MRI performed 6 months later showed no residual tumor; this finding was confirmed by two different histological examinations performed on local biopsies.

In June 2005, right upper cervical lymphadenopathy was noted; MRI showed the presence of an extensive lymph node metastasis infiltrating the carotid sheath. The cytologic diagnosis performed by fine needle aspiration (FNA) of the mass confirmed ENB relapse; MRI did not show signs of local recurrence. The patient underwent a new treatment of external beam radiotherapy on the metastatic area (total dose 50 Gy over a 6-week period). The subsequent MRI showed partial reduction of the mass which had no cleavage planes with the adjacent muscles. Simultaneously, the patient developed lumbar pain. MRI and CT showed regional and multiple distant metastases localized at bones (thoracic, lumbar, and sacral vertebrae, ileum, sacrum, and thigh-bones), at liver, and at abdominal and pelvic lymph nodes. The cytologic examination performed by FNA of one of the hepatic nodules confirmed the diagnosis of ENB metastases; the immunohistochemistry showed the same pattern of the primitive tumor. Due to the underlying persistent leukopenia (white blood cell count <2000/mm³), thus making the use of polychemotherapy regimens contraindicated, the patient was treated with four cycles of cisplatin (60 mg/m² per week), but a new MRI and CT staging showed a dramatic progression of the neoplasm. The patient died in July 2006.

DISCUSSION

With the advent of highly active antiretroviral therapy, the morbidity and mortality associated with HIV infection dramatically reduced, resulting in a large number of older individuals living with HIV infection and in increasing incidence of non-AIDS-related malignancies.⁶ In large database of AIDS-associated cancer, the overall rates of several non-AIDS-related neoplasms (including Hodgkin lymphoma, invasive anal carcinoma, multiple myeloma, leukemia, lung cancer, as well as other solid malignancies), were found to be higher in patients infected with HIV than in general population.⁸ However, unlike AIDS-defining malignancies, no association has been established between many non-AIDS-defining cancers and specific risk factors. In addition, some studies reported the absence of correlation between CD4 cell count and development of solid non-AIDS-defining cancers.^{7,9}

Neither data nor risk factors about clear etiological agents for ENB in human beings are presently available. However, type C retrovirus particles have been demonstrated in the tumor rosettes of spontaneous ENB from domestic cats as well as in transgenic mice developing ENB.¹ Although the role of retroviral sequences in human ENB remains unclear and no association between HIV-1 and this neoplasm has been established, it can be hypothesized that HIV-1 retroviral activity may play a role as a cofactor in the development of ENB. Furthermore, it is noteworthy that our patient was coinfecting with HCV, a well-recognized oncogenic factor.

Although ENB can be locally aggressive and metastasize by lymphatic and hematogenous, distant metastases and very poor prognosis are not common (less than 10% of patients); the largest studies reported a 5-year survival around 45%.¹⁻⁵

Interestingly, in two recent studies of 30 and 18 cases of ENB, respectively, the frequency of recurrence was ~30%, no distant metastases were observed, and the overall 10-year disease-specific survival was 81% and 80%, respectively.^{3,4} In both of these studies, the standard therapeutic approach included surgery, mostly combined with preoperative or postoperative radiotherapy; the chemotherapy was used in patients with advanced initial stages or with recurrent disease. Similarly, the recent and largest case series published by Jethanamest and colleagues⁵ including 311 patients with ENB, reported the overall and disease-specific survival rates at 10 years to be 49% and 68.3%, respectively, and an overall mean survival time of 149.5 months for patients with Kadish B stage disease; no patients received treatment with chemotherapy in this study. In contrast with these data, in our case, although the combination of surgery and postoperative radiotherapy and chemotherapy constituted the initial approach, and despite the early stage of the disease, the patient developed regional and

then distant metastases after ~12 months, with a rapid poor outcome.

Concerning the surgical approach, although the craniofacial resection (CFR) is still considered the gold standard for surgical resection in treatment of ENB, postoperative morbidity (~35%) and mortality (2 to 5%) related to this procedure remain relatively high.⁴ Since the MIER was introduced by Stammberger et al in 1999 as an alternative to CFR in early stages (A, B, T1, and T2 tumors), an increasing number of case series have reported excellent survival and few complications with MIER of ENB in selected patients.⁴ It is not yet clear if MIER approach enables an adequate margin of resection and, if not, whether this matters, particularly if adjuvant radiotherapy is given.² In addition, although there is a lack of consensus about the prognostic value of histologic features of this tumor, it has been reported that Hyams and coworkers' grading could represent an important factor affecting prognosis.¹² Noteworthy, poorly differentiated tumors might have already metastasized and it could be considered reasonable to minimize surgical morbidity and mortality using MIER, rather than CFR.¹³ Adjuvant radiation therapy for ENB has been reported to improve local tumor control, particularly for high-grade and high-stage tumors¹²; in addition, it has been suggested that cisplatin-based chemotherapy is active against ENB, even in advanced, high-grade stages.^{1,2} Despite the early grade and stage of the disease, and taking into account our patient's comorbidities, adjuvant radiotherapy and monotherapy with cisplatin were considered reasonably indicated as consolidation treatment after surgery to optimize the patient's survival.

Although this is the only one case of ENB in an HIV-1 infected patient described until now, the rapid and aggressive progression of this cancer in our patient suggests that in HIV-1 infected patients the possibility of a more intrinsic aggressiveness of the tumor, as documented by rapid development of distant metastases and poor prognosis also in presence of a well-established and prolonged immune reconstitution, should be taken into account. Several studies have shown that some malignancies tend to present with a more aggressive clinical course in HIV-positive patients, when compared with the same neoplastic processes in HIV-negative patients, and the absence of correlation between CD4 cell count and development of solid non-AIDS-defining cancers has been reported.^{7,8} In addition, the role of chemotherapy, radiation therapy, and surgery for treatment of non-AIDS-related malignancies in HIV-1 infected patients remains unclear.⁶

Until larger numbers of cases ideally controlled for stage and differentiation and with longer follow-up

will confirm the opportunity to treat endoscopically in conjunction with radiotherapy early stages (A, B, T1, T2) of ENB, our case seems to suggest that in HIV-1 infected patients a more aggressive therapeutic approach to ENB at the onset, with en-bloc CFR, and adjuvant radiotherapy (including the possible use of concomitant chemotherapy, usually reserved to patients with recurrent or metastatic disease), should be considered. Furthermore, it could be reasonable to consider the use a more frequent and intensive clinical and radiological follow-up and the use of combination chemotherapy regimens.

REFERENCES

1. Dulguerov P, Allal AS, Calcaterra TC. Esthesioneuroblastoma: a meta-analysis and review. *Lancet Oncol* 2001;2(11):683-690
2. Bradley PJ, Jones NS, Robertson I. Diagnosis and management of esthesioneuroblastoma. *Curr Opin Otolaryngol Head Neck Surg* 2003;11(2):112-118
3. Diaz EM Jr, Johnigan RH III, Pero C, et al. Olfactory neuroblastoma: the 22-year experience at one comprehensive cancer center. *Head Neck* 2005;27(2):138-149
4. Zafero ME, Fakhri S, Prayson R, et al. Esthesioneuroblastoma: 25-year experience at a single institution. *Otolaryngol Head Neck Surg* 2008;138(4):452-458
5. Jethanamest D, Morris LG, Sikora AG, Kutler DI. Esthesioneuroblastoma: a population-based analysis of survival and prognostic factors. *Arch Otolaryngol Head Neck Surg* 2007;133(3):276-280
6. Pantanowitz L, Schlecht HP, Dezube BJ. The growing problem of non-AIDS-defining malignancies in HIV. *Curr Opin Oncol* 2006;18(5):469-478
7. Chiao EY, Krown SE. Update on non-acquired immunodeficiency syndrome-defining malignancies. *Curr Opin Oncol* 2003;15(5):389-397
8. Cheung MC, Pantanowitz L, Dezube BJ. AIDS-related malignancies: emerging challenges in the era of highly active antiretroviral therapy. *Oncologist* 2005;10(6):412-426
9. Burgi A, Brodine S, Wegner S, et al. Incidence and risk factors for the occurrence of non-AIDS-defining cancers among human immunodeficiency virus-infected individuals. *Cancer* 2005;104(7):1505-1511
10. Gurtsevitch VE. Human oncogenic viruses: hepatitis B and hepatitis C viruses and their role in hepatocarcinogenesis. *Biochemistry (Mosc)* 2008;73(5):504-513
11. Zignego AL, Giannini C, Ferri C. Hepatitis C virus-related lymphoproliferative disorders: an overview. *World J Gastroenterol* 2007;13(17):2467-2478
12. Foote RL, Morita A, Ebersold MJ, et al. Esthesioneuroblastoma: the role of adjuvant radiation therapy. *Int J Radiat Oncol Biol Phys* 1993;27(4):835-842
13. Levine PA, Gallagher R, Cantrell RW. Esthesioneuroblastoma: reflections of a 21-year experience. *Laryngoscope* 1999;109(10):1539-1543