

# Neonatal Listeriosis: The Importance of Placenta Histological Examination—A Case Report

**Amarilis Batista Teixeira, M.D., Ph.D.,<sup>1</sup> Ana Maria Arruda Lana, M.D., Ph.D.,<sup>2</sup> Joel Alves Lamounier, M.D., Ph.D.,<sup>1</sup> Orlando Pereira da Silva, M.D., M.Sc.,<sup>4</sup> and Silvana Maria Eloi-Santos, M.D., Ph.D.<sup>3</sup>**

## ABSTRACT

Neonatal listeriosis is not a rare disease, but it is infrequently diagnosed and reported in the literature. Herein we report a case of listeria lethal sepsis, followed by increased cytokines levels in the cord blood, in which diagnosis was made possible by histological examination of the placenta.

**KEYWORDS:** Neonatal listeriosis, chorioamnionitis, sepsis, *Listeria monocytogenes*, cytokine

Worldwide, listeriosis is an important public health and food safety problem. In the perinatal period, it is associated with pregnancy loss, premature birth, and neonatal death. In the United States, it has been a mandatory reportable disease since 2001 and in Canada since 2006, but not in other countries, such as Brazil.<sup>1–3</sup> During pregnancy, the diagnosis of listeria infection is difficult as most cases are asymptomatic and may lead to miscarriages and stillbirths. Furthermore, the frequent failure to isolate the bacteria in blood and tissue cultures contributes to paucity of confirmed diagnosis and fewer reports in the literature of neonatal listeriosis.<sup>4</sup> Inflammatory response is a frequent reason of premature deliveries and miscarriages,<sup>5</sup> so cord blood was analyzed for inflammatory cytokines.

The present study reports a case of chorioamnionitis and early neonatal sepsis caused by *Listeria monocytogenes*. It reinforces the importance of clinical suspicion, careful assessment of obstetric history, and

placental histology, which confirmed the diagnosis in the present case.

## CASE REPORT

A male infant was born to a 26-year-old primigravida mother by vaginal delivery at 25 weeks' gestational age and weighed 775 g. The pregnancy was unremarkable except for a flulike illness early in pregnancy and fever a few days prior to delivery. The fetal membranes were ruptured just prior to delivery. The baby was floppy at birth and required resuscitation. Apgar scores were 4 at 1 minute and 8 at 5 minutes of age. Nonconfluent erythematous maculopapular and micropapular exanthema (1-mm diameter) with purpuric lesions as large as 2 to 3 mm were noted at birth mostly located on the trunk, buttocks, and thighs but absent from palms, plants, and scalp, different from classical "blueberry muffin."

<sup>1</sup>Child and Adolescent Health; <sup>2</sup>Department of Pathology; <sup>3</sup>Department of Propedeutics, School of Medicine, Universidade Federal de Minas Gerais, Belo Horizonte, Brazil; <sup>4</sup>Department of Paediatrics, University of Western Ontario, Schulich School of Medicine and Dentistry, London, Canada.

Address for correspondence and reprint requests: Silvana Maria Eloi-Santos, M.D., Ph.D., Av. Alfredo Balena, 190 Sala 403. Santa Efigênia, 30 130 100 Belo Horizonte–Minas Gerais,

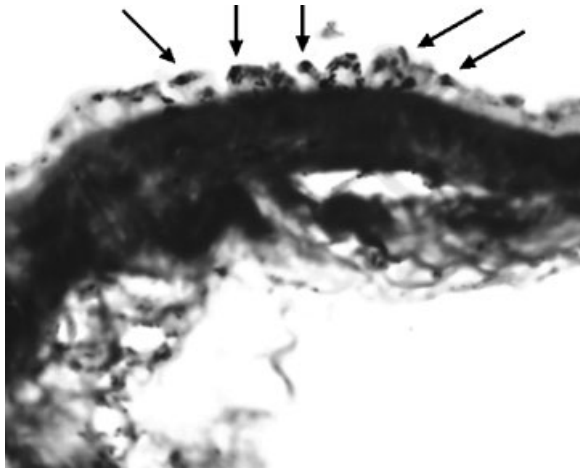
Brazil (e-mail: eloisil@medicina.ufmg.br).

Am J Perinatol Rep 2011;1:3–6. Copyright © 2011 by Thieme Medical Publishers, Inc., 333 Seventh Avenue, New York, NY 10001, USA. Tel: +1 (212) 584-4662.

Received: October 26, 2010. Accepted: October 28, 2010. Published online: January 24, 2011.

DOI: <http://dx.doi.org/10.1055/s-0030-1271216>.

ISSN 2157-6998.



**Figure 1** Microscopic (eight-silver; 1000 ×) amniotic epithelium, showing silver-positive intracellular bacteria, staining by Grocott's method (silver impregnation).

After initial resuscitation, the patient was admitted to the neonatal intensive care unit and intubated for respiratory distress. Surfactant replacement therapy via endotracheal tube was given 40 minutes after birth. His clinical course continued to deteriorate, and he died 24 hours later with septic shock that failed to respond to clinical septic shock management, including administration of volume expanders, antibiotics, and inotropes.

Blood culture taken at birth failed to grow any organisms. The placental histology showed acute necrotizing chorioamnionitis with funisitis, characterized by a green-yellowish discoloration and thickening and opacity of the amnion, chorion, and fetal membranes, associated with the presence of dense and diffuse inflammatory neutrophilic exudates, often forming subchorionic abscesses. There was acute funisitis, with neutrophilic exudates in the umbilical vessel walls and Warton's jelly, as well as necrosis and presence of intracellular gram-positive bacteria in membranes and umbilical cord. The amnion also presented necrosis and gram-positive and silver-positive intracellular bacteria were seen (Grocott's method, Fig. 1), histological findings typical of *L. monocytogenes* infection.

Inflammatory cytokines in cord blood, collected aseptically in heparinized tubes at birth and measured by flow cytometry using cytometric bead array (BD Cytometric Blood Array Human Inflammatory Cytokine kit, BD Biosciences, Pharmingen, San Diego, CA), were elevated [interleukin (IL)-8 and IL-6 (both >5000 pg/mL) and IL-10 (100 pg/mL)], when compared with mean values of 329 (7 to 4135), 246 (50 to 1100), and 3.6 (2.2 to 7.0) pg/mL, respectively, already described in cord blood of very low-gestational-age neonates with chorioamnionitis.<sup>6</sup>

## DISCUSSION

*L. monocytogenes* is a facultative anaerobe, intracellular gram-positive,  $\beta$ -hemolytic coccobacillus. Surface proteins and enzymes allow it to invade and survive inside phagocytes and infect other cells without exposure to antibodies and neutrophilic and complement defenses. Factors responsible for listeria's intracellular survival, intracytosol replication, as well as the polymerization process, which provides energy for motility and insertion in the nearby cells, have been described in detail elsewhere.<sup>7</sup>

*L. monocytogenes* attacks mainly the central nervous system and may cross the blood-brain barrier, causing meningoencephalitis and thromboencephalitis. The infecting dose varies according to the strain and patient susceptibility, and in a recent study in animals, it was found to be  $10^7$  colony forming units.<sup>8</sup> Thirteen serotypes have been described, according to cellular and flagellar antigens, but serotypes 1/2a, 1/2b, and 4b are responsible for almost all human infections.

The most frequent transmission route is through the ingestion of contaminated food (mainly milk and dairy products, poultry, uncooked meat, raw vegetables, and even water). It is estimated that 5 to 10% of the population are carriers of *L. monocytogenes* in their digestive tract, cervix, or vagina, but there has not been any description of person-to-person transmission.<sup>4</sup> Vertical transmission is well documented, and contamination may be ascendant, via direct invasion or transplacental or hematogenous dissemination<sup>9</sup> and may also occur in the birth canal during labor<sup>10</sup> and through the breast milk.<sup>11</sup> Outbreaks due to the contact with contaminated equipment devices or material are rare, but occasionally occur in neonatal intensive care units.

Recent review showed that a considerable proportion of reported listeriosis cases (16.9%) in the United States from 2004 to 2007 consists of pregnant women, and maternal infection resulted fetal loss in 20.3%.<sup>12</sup> Pregnant women are 20 times more susceptible than healthy nonpregnant adults to be infected by this bacteria. Neonates are even more susceptible than their mothers.<sup>1-3</sup>

Clinical presentation varies according to transmission route and patient immune system status. Incubation period ranges from 8 to 14 days (outbreaks: 3 to 70 days). Many cases are asymptomatic, or the patient may report mild complaints (discomfort and myalgia). Pregnant women may present with a flulike illness with fever, gastrointestinal symptoms, low abdominal pain, skin rashes, and meningitis. The flulike illness is always short-lived but bacteremia is always present. Skin lesions usually consist of papules, pustules, vesicles, ulcers, and purpura.<sup>4</sup>

The neonate may present with early or late sepsis. In cases of intrauterine transmission, the signs of early sepsis are apparent from birth up to 2 days of life, and eventually can be lethal. Amniotic fluid is

usually meconium-stained. Sepsis syndrome may predominate, but respiratory symptoms are more frequent. Cyanosis, apnea, respiratory difficulties, and pneumonia with reticulogranular pattern or diffuse infiltrates on chest X-ray can be present. The respiratory distress is usually associated with fever and convulsion. Cutaneous eruptions with papules, pustules, vesicles, and/or widespread ulcers usually appear before 3 days of life. An especially severe form of neonatal listeriosis, called "granulomatosis infantiseptica," presents widespread microabscesses and a mortality rate over 80%. In these cases, anatomopathological examination shows miliary granulomas and areas of necrosis and abscess formation, with liver involvement. Other lesions include endocarditis and widespread abscesses.

In late sepsis, when transmission has happened through the colonized birth canal, symptoms may occur up to 2 weeks after delivery and include meningitis without associated skin lesions.<sup>11,13</sup>

The incidence of listeriosis has been increasing in several European countries while decreasing in the United States, possibly due to the efforts to control food quality and disease outbreaks.<sup>14</sup> Neonatal listeriosis is relatively rare in Asian countries such as Taiwan and Japan, and this difference may be due to local dietary habits compared with Western countries.<sup>15</sup> An Israeli report reviewed 34% of all cases of perinatal listeriosis in the world. The incidence rate ranges from 0.1 to 1.1 for 100,000 in different periods and countries. The mortality rate was 45% and 36% for perinatal and nonperinatal cases, respectively. Of neonates from infected mothers, 10% did not show any evidence of infection. Most patients presented early sepsis and in the cases of late onset, almost all presented central nervous system involvement with increased overall mortality rate (70%).<sup>16</sup>

When suspected by clinical features, early infection can be easily and promptly confirmed by cytological and gram studies of skin lesions and meconium. Definitive diagnosis can be established through blood culture (in systemic cases) or culture of skin lesion material or by the demonstration of microorganisms in the anatomopathological examination.<sup>11</sup> *L. monocytogenes* may be mistaken by hemolytic streptococcus, diphtheroids, or enterococcus. Serological studies are not helpful for the diagnosis, and the white blood cell count shows leukocytosis or leukopenia and thrombocytopenia.<sup>4</sup> Spinal fluid analysis is essential to rule out meningitis, and if the organism persists for more than 2 days, despite appropriate antibiotic treatment, central nervous system imaging may be required.<sup>17</sup> Unfortunately, the presence of thrombocytopenia in this case does not allow lumbar puncture.

Many antibiotics are active against *L. monocytogenes*, but ampicillin is the treatment of choice even during pregnancy. During the neonatal period, high-

dose intravenous ampicillin and an aminoglycoside is recommended for 2 to 4 weeks, and up to 6 weeks in the presence of brain abscess or endocarditis.

Because *L. monocytogenes* is a facultative intracellular organism, the antibiotic might not be fully effective. This explains the cure rate of only 70% despite the high susceptibility of the strains to the antibiotics. The ideal antibiotic should have bactericidal activity superior to that of ampicillin and be able to readily cross the blood-brain barrier and reach high concentration inside the host cells and cytoplasm. Therefore, new quinolones are of particular interest; however, further clinical data are still lacking. It is uncertain whether antibiotics are sufficient to improve the prognosis by themselves. Possibly, additional therapy with immunomodulators may improve the successful treatment of listeriosis as a strong correlation between inflammatory cytokines and severity of illness is evident.<sup>18</sup>

*L. monocytogenes* may even be found in the stool of preterm neonates after adequate systemic treatment. Therefore, it is essential to take infection control measures to reduce the risk of nosocomial infection.<sup>10</sup>

*L. monocytogenes* should be considered in the differential diagnosis of neonatal sepsis and meningitis. Early diagnosis and prompt treatment can improve outcomes.

Placental pathology evaluation is invaluable in suspected cases. Pathological features are remarkable. The placenta shows diffused scattered, tiny, yellowish lesions consisting of villous microabscesses with foci of necrosis and peripheral palisaded histiocytes. Focal villitis may be seen with the presence of neutrophils between the trophoblast and the villous stroma. Gram-positive bacilli can be visualized in the villous inflammation.<sup>19-21</sup>

Finally, education of pregnant women about changes in their dietary habits and of health care professional to recognize and promptly treat the pregnant woman and newborn is critical to reduce the incidence of perinatal listeriosis.

#### ACKNOWLEDGMENTS

This article is dedicated to our friend Dr. Lincoln S. Freire, who recently passed away, for his encouragement and support in the writing of this manuscript.

#### REFERENCES

1. Bortolussi R. Listeriosis: a primer. *CMAJ* 2008;179:795-797
2. Reddy UM, Fry A, Pass R, Ghidini A. Infectious diseases and perinatal outcomes. *Emerg Infect Dis*; 2004. Available at: [http://www.cdc.gov/NCIDOD/EID/vol10no11/04-0623\\_10.htm](http://www.cdc.gov/NCIDOD/EID/vol10no11/04-0623_10.htm). Accessed February 23, 2010
3. Almeida GN, Gibbs PA, Hogg TA, Teixeira PC. Listeriosis in Portugal: an existing but under reported infection. *BMC Infect Dis* 2006;6:153

4. Bennett L. *Listeria monocytogenes*. In: Mandel GL, Bennet JE, Dolin R, eds. *Principles and Practice of Infectious Diseases*. New York: Churchill Livingstone; 2005:2478–2483
5. Romero R, Espinoza J, Gonçalves LF, Kusanovic JP, Friel LA, Nien JK. Inflammation in preterm and term labour and delivery. *Semin Fetal Neonatal Med* 2006;11:317–326
6. Paananen R, Husa AK, Vuolteenaho R, Herva R, Kaukola T, Hallman M. Blood cytokines during the perinatal period in very preterm infants: relationship of inflammatory response and bronchopulmonary dysplasia. *J Pediatr* 2009;154:39–43, e3
7. Cossart P, Toledo-Arana A. *Listeria monocytogenes*, a unique model in infection biology: an overview. *Microbes Infect* 2008;10:1041–1050
8. Williams D, Irvin EA, Chmielewski RA, Frank JF, Smith MA. Dose-response of *Listeria monocytogenes* after oral exposure in pregnant guinea pigs. *J Food Prot* 2007;70:1122–1128
9. Huang YT, Chen SU, Wu MZ, et al. Molecular evidence for vertical transmission of listeriosis, Taiwan. *J Med Microbiol* 2006;55(Pt 11):1601–1603
10. Puopolo KM. Bacterial and fungal infections. In: Cloherty JP, Eichenwald EC, Stark AR, eds. *Manual of Neonatal Care*. Philadelphia: Lippincott Williams & Williams; 2008: 286–2872
11. Heras C, García-Patos V, Palacio L, et al. Listeriosis neonatal. *Actas Dermosifiliogr* 2006;97:59–61
12. Jackson KA, Iwamoto M, Swerdlow D. Pregnancy-associated listeriosis. *Epidemiol Infect* 2010;138:1503–1509 (Epub ahead of print)
13. Srivastava S, Sen MR, Kumar A, Anupurba S. Neonatal listeriosis. *Indian J Pediatr* 2005;72:1059–1060
14. Goulet V, Hedberg C, Le Monnier A, de Valk H. Increasing incidence of listeriosis in France and other European countries. *Emerg Infect Dis* 2008;14:734–740
15. Hsieh WS, Tsai LY, Jeng SF, et al. Neonatal listeriosis in Taiwan, 1990–2007. *Int J Infect Dis* 2009;13:193–195
16. Siegman-Igra Y, Levin R, Weinberger M, et al. *Listeria monocytogenes* infection in Israel and review of cases worldwide. *Emerg Infect Dis* 2002;8:305–310 Erratum in: *Emerg Infect Dis* 2002;8:554
17. Chen SY, Lu FL, Lee PI, et al. Neonatal listeriosis. *J Formos Med Assoc* 2007;106:161–164
18. Hof H. An update on the medical management of listeriosis. *Expert Opin Pharmacother* 2004;5:1727–1735
19. Faye-Petersen OM, Heller DS, Joshi VV. Lesions of the placenta as a whole or of the placenta disk. In: Faye-Petersen OM, Heller DS, Joshi VV, eds. *Handbook of Placental Pathology*. Boca Raton, FL: Taylor and Francis Group; 2006;96:
20. Al-Adnani M, Sebire NJ. The role of perinatal pathological examination in subclinical infection in obstetrics. *Best Pract Res Clin Obstet Gynaecol* 2007;21:505–521
21. Driscoll SG, Gorbach A, Feldman D. Congenital listeriosis: diagnosis from placental studies. *Oncologia* 1962;20: 216–220