

Endoscopic hemostasis with multiple hemoclips and an endoloop for uncontrolled peptic ulcer bleeding

A method using a combination of multiple hemoclips and an endoloop was introduced for treating peptic ulcer bleeding and the large mucosal defects after endoscopic mucosal resection (EMR) or endoscopic submucosal dissection (ESD) [1–4]. We report the combined use of multiple hemoclips and an endoloop in patients with uncontrolled peptic ulcer bleeding. The endoscopic examination and therapy were performed using a one-channel endoscope. In contrast to a two-channel endoscope, a one-channel endoscope permits separating one catheter containing a clip from the other catheter containing an endoloop, and it also provides a wide range of therapeutic actions during combination therapy. The combination therapy was conducted using the step-by-step method (▶ Figs. 1 and 2).

Before insertion of the endoscope into the patient, alligator forceps were inserted into the working channel of the endoscope. We slightly released the catheter equipped with an endoloop, and the alligator forceps caught the tip of the endoloop. Next, the alligator forceps were pulled back into the working channel as much as possible to prevent contact injury to the patient. We then grasped the tip of

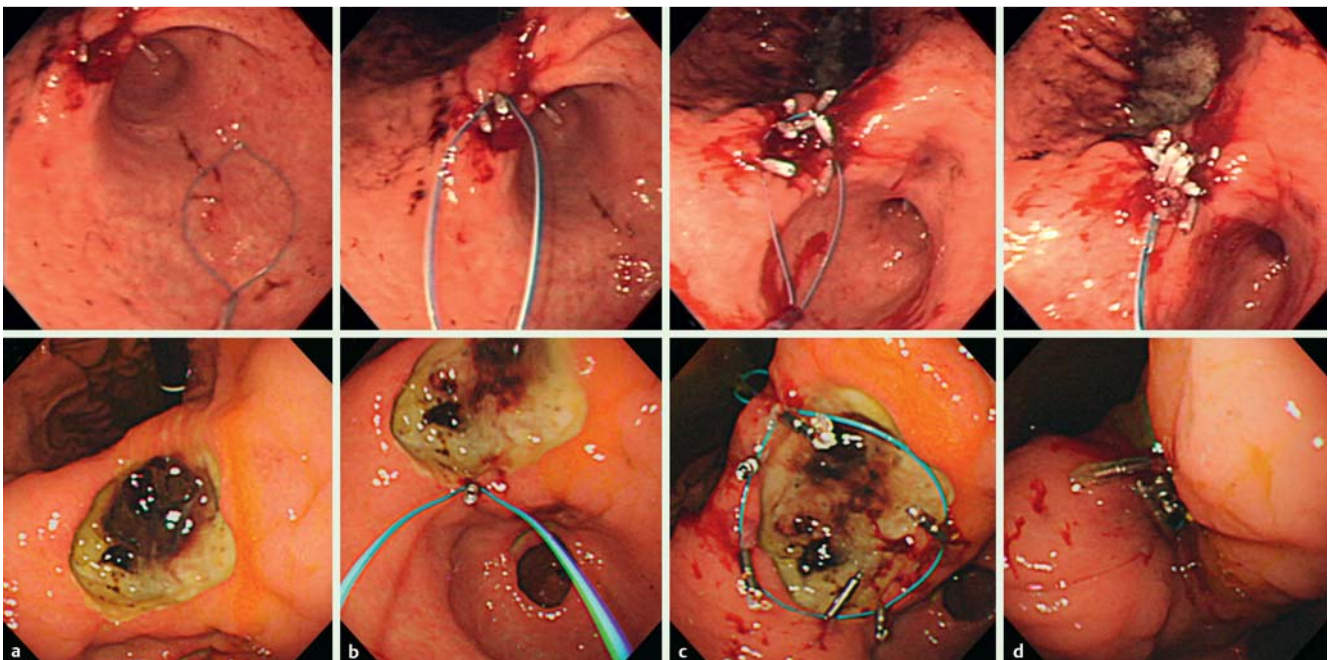
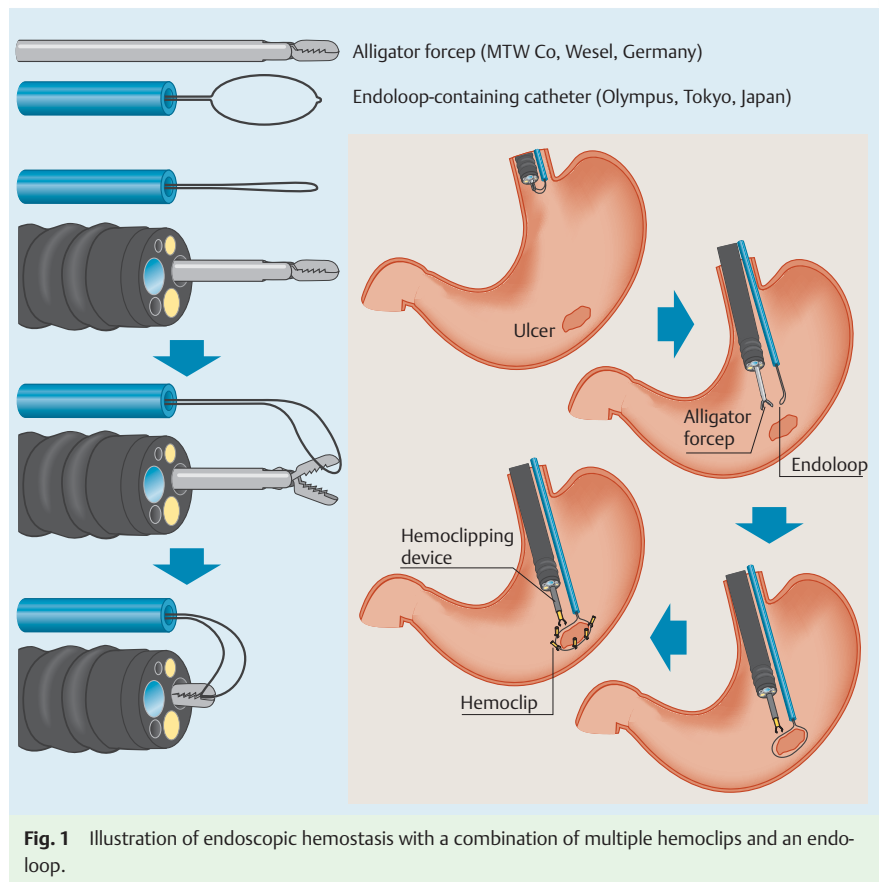


Fig. 2 Upper gastrointestinal endoscopic pictures of two patients. **a** Large, oozing ulcers at the angle of the stomach. **b** An endoloop and hemoclip were placed at the edge of the ulcer margin at the distal side. **c** The endoloop was attached at the ulcer margin and caught and fixed with multiple hemoclips. **d** Tightening of the endoloop closed the bleeding ulcer.

the endoscope along with the tip of the endoloop containing the catheter, and we inserted all this into the patient. The endoscope and the catheter containing the endoloop were placed near the bleeding ulcer. The alligator forceps were opened for detaching the catheter with the endoloop. Then the endoloop was fully released and shaped. After insertion of the clipping catheter equipped with a hemoclip into the working channel, we caught the tip of the endoloop with the hemoclip and started attaching the clips from the distal margin; several hemoclips were sequentially attached with the endoloop around the margin of the ulcer. Finally, we tightened the endoloop and this closed the bleeding ulcer. The ulcer margins were almost perfectly joined and they covered the ulcer's base.

Endoscopy_UCTN_Code_TTT_1AO_2AD

Competing interests: None

**D. H. Kim, C.-I. Kwon, J. G. Chung,
K. H. Ko, M. D. Kim, S. P. Hong,
P. W. Park**

Digestive Disease Center, CHA Bundang
Medical Center, CHA University, Seong-
nam, Korea

References

- 1 *Rác I, Kárász T, Saleh H.* Endoscopic hemostasis of bleeding gastric ulcer with a combination of multiple hemoclips and endoloops. *Gastrointest Endosc* 2009; 69: 580–583
- 2 *Endo M, Inomata M, Terui T et al.* New endoscopic technique to close large mucosal defects after endoscopic mucosal resection in patients with gastric mucosal tumors. *Dig Endosc* 2004; 16: 372–375
- 3 *Matsuda T, Fujii T, Emura F et al.* Complete closure of a large defect after EMR of a lateral spreading colorectal tumor when using a two channel colonoscope. *Gastrointest Endosc* 2004; 60: 836–838
- 4 *Sanders MK, Malick J, Fasanella KE et al.* Endoscopic closure of iatrogenic duodenal perforation during EUS in a patient with unusual anatomy. *Gastrointest Endosc* 2008; 68: 802–804

Bibliography

DOI 10.1055/s-0030-1255986

Endoscopy 2011; 43: E3–E4

© Georg Thieme Verlag KG Stuttgart · New York ·
ISSN 0013-726X

Corresponding author

C.-I. Kwon, MD, PhD

Digestive Disease Center
CHA Bundang Medical Center
CHA University
351 Yatap-dong
Bundang-gu
Seongnam, 463-712
South Korea
Fax: +82-31-780-5219
endoscopy@cha.ac.kr