

Pneumatosis coli as a rare complication of bowel preparation

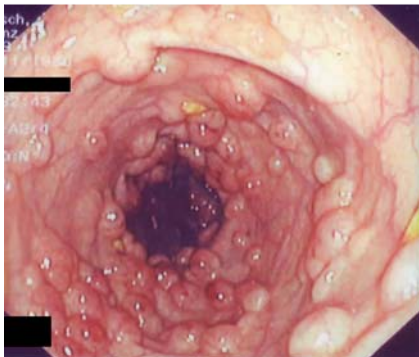


Fig. 1 Numerous (> 50) close standing polyps in the sigmoid over a total distance of 20 cm.

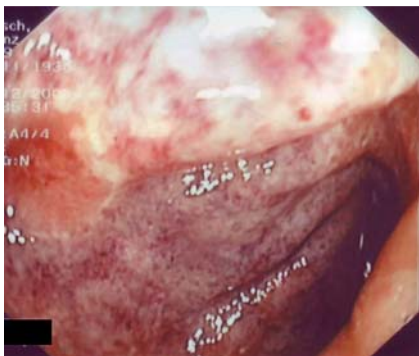


Fig. 2 Segmental erosive-ulcerative mucosal damage with punctuate hemorrhages and a deep-blue appearing mucosa in the descending colon.

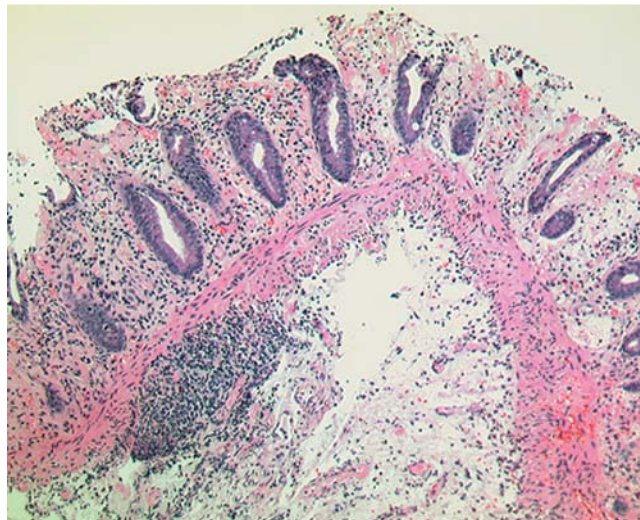


Fig. 3 Histopathologic examination of the descending colon showing necrotic mucosa with fibrinous exudates containing neutrophil granulocytes and capillary microthrombi, confirming acute colonic ischemia.

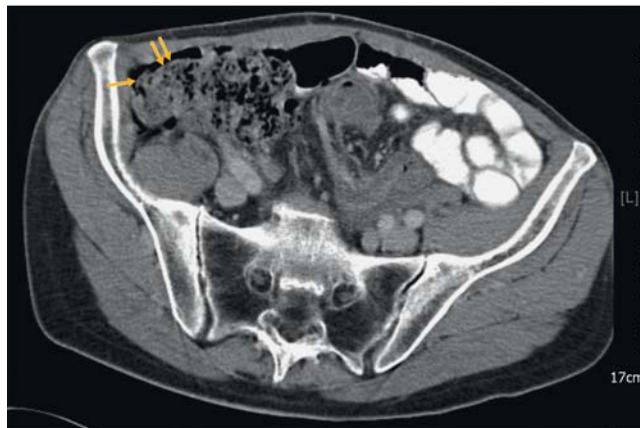

Fig. 4 Bubblelike pneumatosis intestinalis in the sigmoid (arrows).

Intestinal lavage for colonoscopy is a safe procedure, even in elderly patients [1]. This is the first report describing a case of acute ischemic colitis with pneumatosis coli resulting from bowel preparation in a patient with anatomic predispositions. A 69-year-old man was admitted for screening colonoscopy. His medical history was not significant. A formulation of polyethylene glycol and electrolytes was used for lavage. Physical examination and laboratory tests were unremarkable prior to endoscopy. Endoscopically, the sigmoid exhibited numerous (> 50) close standing polyps (● Fig. 1).

The descending colon showed a segmental, erosive-ulcerative colitis (● Fig. 2). In the transverse colon a subtotal stenosis could not be passed. Histopathologic examination revealed acute colonic ischemia in the descending colon (● Fig. 3)

and discrete crypt architectural distortion in the polypoid lesions.

Specific etiologies of ischemic colitis [2] were excluded in a thorough workup. Computed tomography (CT) showed a considerably elongated sigmoid with bubblelike pneumatosis coli (● Fig. 4) and a circular thickening of the transverse colon. Mesenteric angiography revealed markedly rarefied colonic arteries with small caliber, but no advanced atherosclerosis (● Fig. 5).

Double-contrast barium enema revealed an extensive dolichocolon with formation of a loop at the splenic flexure (● Fig. 6). About 15% of cases of colonic ischemia develop potentially life-threatening gangrene [3] and pneumatosis has been considered as an indicator of advanced ische-

mia [2]. Recent evidence suggests, however, that isolated pneumatosis does not always indicate transmural infarction [4]. In our case, the patient completely recovered and subsequent complete colonoscopies revealed no signs of ischemia. The ischemic colitis most likely resulted from a combination of enhanced colonic viability and the associated demand of increased perfusion during intestinal lavage on the one hand, and a limited perfusion reserve due to the extensive dolichocolon with rarefied visceral arteries on the other hand. This case further exemplifies that isolated pneumatosis is not necessarily associated with transmural infarction.

Competing interests: None

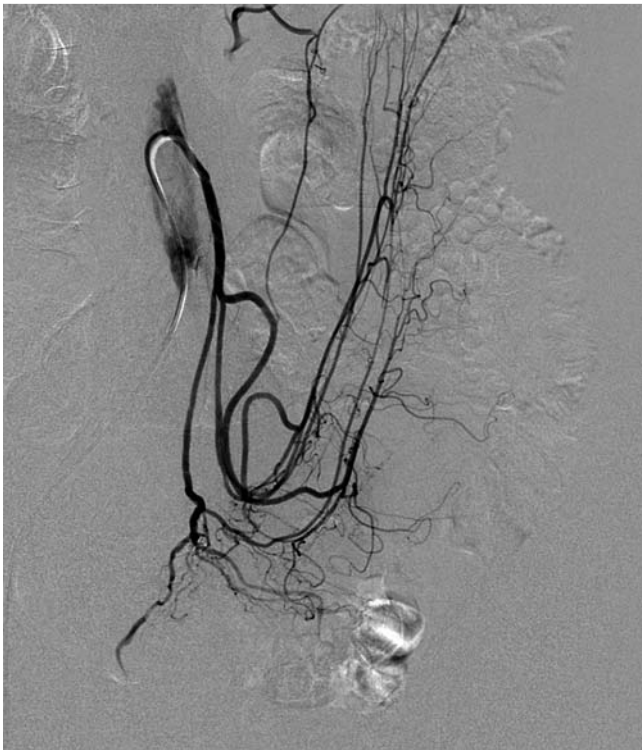

Fig. 5 Mesenteric angiography revealed markedly rarefied and small-caliber visceral arteries in the colon.

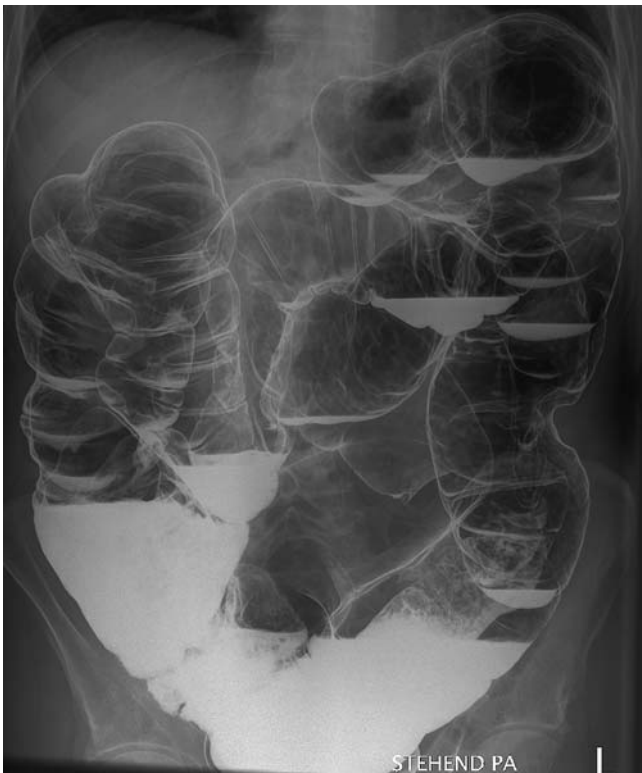

Fig. 6 Double-contrast barium enema showing extensive dolichocolon with formation of a loop at the splenic flexure.

Endoscopy_UCTN_Code_CPL_1AJ_2AI

T. Rath, E. Roeb, W. E. Doppl

Department of Internal Medicine,
Division of Gastroenterology,
Justus-Liebig-University, Giessen, Germany

References

- 1 Clarke GA, Jacobson BC, Hammett RF, Carr-Locke DL. The indications, utilization and safety of gastrointestinal endoscopy in an extremely elderly patient cohort. *Endoscopy* 2001; 33: 580–584
- 2 Brandt LJ, Boley SJ. AGA technical review on intestinal ischemia. *American Gastrointestinal Association. Gastroenterology* 2000; 118: 954–968
- 3 Elder K, Lashner BA, Al Solaiman F. Clinical approach to colonic ischemia. *Cleve Clin J Med* 2009; 76: 401–409
- 4 Kernagis LY, Levine MS, Jacobs JE. Pneumatosis intestinalis in patients with ischemia: correlation of CT findings with viability of the bowel. *AJR Am J Roentgenol* 2003; 180: 733–736

Bibliography

DOI 10.1055/s-0030-1255977

Endoscopy 2010; 42: E344–E345

© Georg Thieme Verlag KG Stuttgart · New York ·
ISSN 0013-726X

Corresponding author

Professor E. Roeb

Justus-Liebig-University
Gastroenterology
Paul-Meimberg-Str. 5
35385 Giessen
Germany
Fax: +49-641-9942339
elke.roeb@innere.med.uni-giessen.de