

Per oral dual-scope rendezvous technique for endoscopic bridging of complete pancreatic duct disruption

A 43-year-old man with a history of heavy alcohol consumption and recent acute pancreatitis was admitted for recurrent epigastric pain and diagnosed as having a 4-cm pancreatic pseudocyst. Endoscopic retrograde cholangiopancreatography (ERCP) showed a pancreas divisum with total obstruction of the main pancreatic duct (MPD) in the mid-pancreas and no communication with the fluid collection. Minor papilla sphincterotomy was performed with placement of a 7-Fr plastic stent (Zimmon, Wilson-Cook, Winston-Salem, North Carolina, USA) in the pancreatic duct. Endoscopic ultrasound-guided cystogastrostomy was carried out (Pentax EG3860UT, Hamburg, Germany) and a single, 10-Fr double-pig-tail stent was placed (● Fig. 1).

After 1 month, the patient complained of fever and recurrent pain. ERCP revealed total obstruction of the MPD and a fistula with the site of gastrostomy in the stomach. The corporeocaudal MPD was opacified via the cystogastrostomy site (● Fig. 2).

Dual drainage was carried out with a 5-Fr transgastric stent in the corporeal duct via the cystogastrostomy site and a 7-Fr transpapillogastric stent via the minor papilla. Complete bridging of the MPD rupture was tried again 1 month later, but the guide wire could not unite the proximal and distal parts of the pancreatic duct. A dual-scope approach (with both endoscopes inserted together per orally into the esophagus) was therefore attempted with insertion of a guide wire (Jagwire 0.035, Boston Scientific, Diegem, Belgium) through the papilla toward the stomach with the duodenoscope (TJF-160R, Olympus, Aartselaar, Belgium). Retrieving the guide wire and bringing it into the pancreatic tail was done with a gastroscope (GIF180, Olympus, Aartselaar, Belgium) positioned in front of the gastric fistula orifice (● Fig. 3).

A long, plastic, single-pig-tail stent was then placed to bridge the rupture and drain the entire pancreatic duct (● Fig. 4). Eventually, the patient's pain resolved and 10-Fr stent exchanges were carried out every 6 months for 2 years, with no further symptoms.

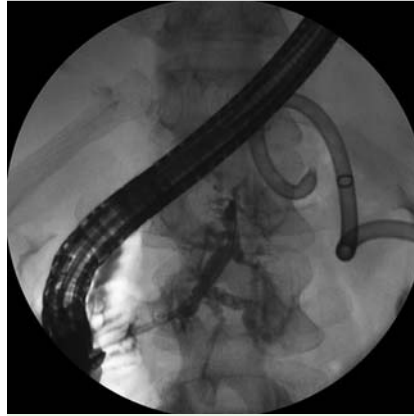

Fig. 1 Total obstruction of the main pancreatic duct, which is opacified via the minor papilla. In the background, a transgastric double-pig-tail stent is seen in the collection.

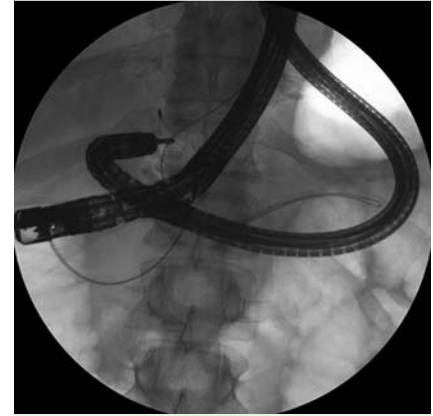

Fig. 3 Dual-scope rendezvous technique: A guide wire inserted via the minor papilla with the duodenoscope has been caught by the gastroscope with a pair of forceps to help advance it in the pancreatic tail.

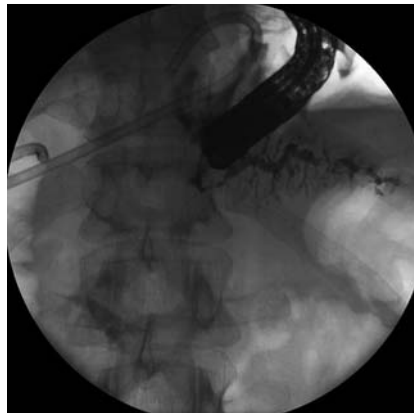


Fig. 2 Corporeocaudal opacification of the main pancreatic duct via the cystogastrostomy site, showing no connection with the head of the pancreas.

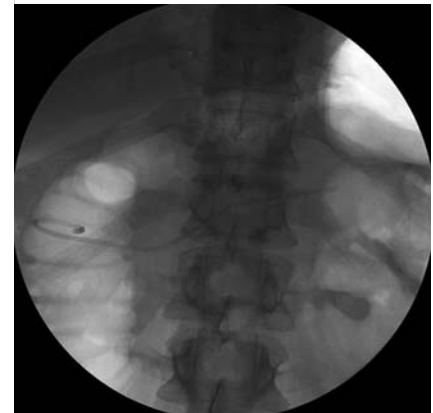


Fig. 4 A pancreatic stent bridging the entire duct and fistula.

Peroral dual-scope technique has been used for natural orifice transluminal endoscopic surgery (NOTES), but have been only reported in animals [1,2]. In this report, we have described an application of this approach to bridge a complicated rupture of the MPD and a pancreato-gastric fistula following EUS cystogastrostomy, using a modified dual-scope rendezvous technique [3–5].

Competing interests: None

Endoscopy_UCTN_Code_TTT_1AR_2AI

M. Ergun, C. Descamps, P. H. Deprez
Department of Gastroenterology,
Cliniques Universitaires Saint-Luc,
Université Catholique de Louvain,
Brussels, Belgium

References

- 1 Asakuma M, Perretta S, Allemann P et al. Peroral dual scope notes cholecystectomy in porcine model (with video). *Surg Endosc* March 31 2010; [Epub ahead of print]
- 2 Asakuma M, Perretta S, Cahill RA et al. Peroral dual scope for natural orifice transluminal endoscopic surgery (NOTES) gastrotomy closure. *Surg Innov* 2009; 16: 97–103
- 3 Will U, Meyer F, Manger T, Wanzar I. Endoscopic ultrasound assisted rendez-vous maneuver to achieve pancreatic duct drain-

age in obstructive chronic pancreatitis. *Endoscopy* 2005; 37: 171–173

- 4 Bataille L, Deprez P. A new application for therapeutic EUS: main pancreatic duct drainage with a “pancreatic rendezvous technique”. *Gastrointest Endosc* 2002; 55: 740–743
- 5 Frieling T, Bubic M, Streuter M et al. Pancreaticopleural fistula: successful treatment by major-to-minor duodenal papilla rendezvous stenting of the pancreatic duct. *Endoscopy* 2009; 41 (Suppl 2): E179–E180

Bibliography

DOI 10.1055/s-0030-1255765

Endoscopy 2010; 42: E275–E276

© Georg Thieme Verlag KG Stuttgart · New York · ISSN 0013-726X

Corresponding author

P. H. Deprez

Gastroenterology Department
Cliniques Universitaires St-Luc
Université Catholique de Louvain
Avenue Hippocrate 10
1200 Brussels
Belgium
Fax: +32-2-7648927
pierrehenri.deprez@uclouvain.be