

Hepatobiliary fascioliasis treated at endoscopic retrograde cholangiopancreatography

In most parts of Asia, hepatobiliary fascioliasis is sporadic and has been traditionally attributed to travel to endemic zones. Recently the World Health Organization has described fascioliasis as an 'emerging human disease', with cases being increasingly reported from non-endemic zones. A 28-year-old woman presented with a 2-month history of abdominal pain. Examination revealed fever and tender hepatomegaly. Laboratory investigation showed the following results: hemoglobin, 9.4 g/dL; white cell count, 9100 cells/mm³ (24% eosinophils); aspartate aminotransferase, 64 IU/L; alanine aminotransferase, 84 IU/L; and alkaline phosphatase, 746 IU/L. Computed tomography (CT) scan demonstrated multiple complex hepatic cysts (● Fig. 1).

At endoscopic retrograde cholangiopancreatography (ERCP) the cholangiogram showed a non-dilated common bile duct with multiple irregular ill-defined filling defects. During balloon extraction after sphincterotomy (● Video 1), live flat leaf-shaped adult *Fasciola hepatica* were withdrawn from the bile duct (● Fig. 2).

The patient was treated with triclabendazole (10 mg/kg) in two divided doses, and continues to be symptom-free after 6 months of follow-up.

Human hepatobiliary infection by this trematode has two distinct phases: an acute hepatic phase and a chronic biliary phase. The acute phase is clinically manifested by upper abdominal pain, fever, hepatomegaly, and intense eosinophilia. In the chronic biliary phase, the adult worms attach to the mucosal lining of the biliary tree, where they may survive for years, causing periodic biliary obstruction.

ERCP in biliary fascioliasis may be normal in early disease and closely mimics primary sclerosing cholangitis in the chronic phase [1]. A short sphincterotomy is often adequate to achieve removal of these soft parasites [2]. Some authors have described intraductal endoscopic treatment of massive biliary fascioliasis by means of 10% povidone iodine solution [3,4]. Although results have been encouraging in small groups of patients, larger studies need to validate the safety of intraductal endoscopic treatment before accepting it as a standard endoscopic intervention for biliary fascioliasis.

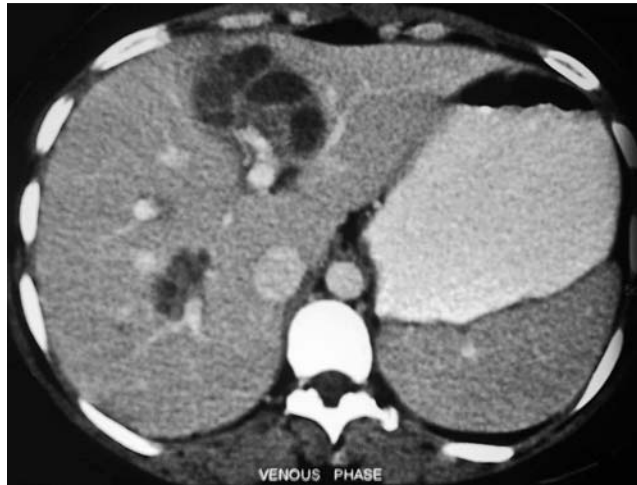


Fig. 1 Portal venous phase computed tomography scan showing multiple hypodense non-enhancing complex cystic lesions in the liver.

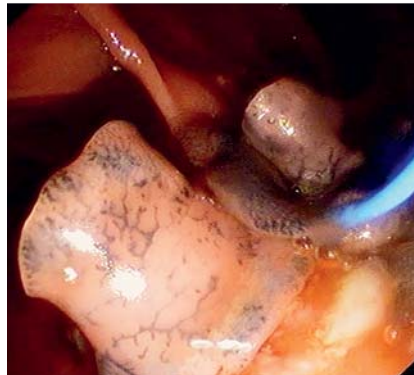

Fig. 2 Endoscopic image of a live *Fasciola hepatica* emerging from the bile duct during balloon extraction at endoscopic retrograde cholangiopancreatography.

In view of the global increase of migrant populations and international food trade, boundaries between endemic and non-endemic zones for human fascioliasis are being blurred. Hence, diagnosis of human fascioliasis should be strongly suspected in patients presenting with the triad of abdominal pain, hepatomegaly, and hypodense liver parenchymal lesion with or without peripheral eosinophilia even in non-endemic regions.

Competing interests: None

Endoscopy_UCTN_Code_CCL_1AZ_2AN

Video 1

Endoscopic sphincterotomy and balloon extraction of live *Fasciola hepatica* from the bile duct.

M. K. Goenka¹, S. Majumder¹,
P. K. Sethy¹, S. Kumar¹, U. Goenka²

¹ Institute of Gastroenterology, Apollo
Gleneagles Hospital, Kolkata, India

² Department of Radiology, Apollo
Gleneagles Hospital, Kolkata, India

References

- 1 Hauser SC, Bynum TE. Abnormalities on ERCP in a case of human fascioliasis. *Gastrointest Endosc* 1984; 30: 80–82
- 2 Dias LM, Suva R, Viana HL et al. Biliary fascioliasis: diagnosis, treatment and follow-up by ERCP. *Gastrointest Endosc* 1996; 43: 616–620
- 3 Dowidar N, El Sayad M, Osman M et al. Endoscopic therapy of fascioliasis resistant to oral therapy. *Gastrointest Endosc* 1999; 50: 345–351
- 4 Roig GV. Hepatic fascioliasis in the Americas: a new challenge for therapeutic endoscopy. *Gastrointest Endosc* 2002; 56: 315–317

Bibliography

DOI 10.1055/s-0029-1243907

Endoscopy 2010; 42: E103

© Georg Thieme Verlag KG Stuttgart · New York ·
ISSN 0013-726X

Corresponding author

M. K. Goenka, MD

Institute of Gastroenterology,
Apollo Gleneagles Hospital
BH – 97, Sector 2
Salt Lake City
Calcutta 700091
India
Fax: +91-33-23205218
dr_mkgoenka@yahoo.co.in