

Endoscopic Forehead and Brow Lift

Gregory S. Keller, M.D., F.A.C.S.,¹ and Grigoriy Mashkevich, M.D.²

ABSTRACT

Endoscopic method of rejuvenating the brow-forehead complex has evolved into the procedure of choice for many aesthetic surgeons. Safe and reliable application of the endoscopic technique depends on several important factors. These include technical expertise with the endoscopic equipment, understanding of the surgical goals in patients seeking rejuvenation in the forehead region, and detailed comprehension of the steps involved in altering forehead anatomy during endoscopic lifting. In this manuscript, the senior author reviews his experience with the endoscopic forehead lift and delineates a stepwise approach to this technically challenging operation. The text also highlights important details with respect to patient care, endoscopic equipment, and surgical anatomy. “Keller’ rules of fours” are introduced to summarize surgical pearls of the endoscopic forehead and brow lift.

KEYWORDS: Endoscopic, forehead lift, brow lift

Although almost two-thirds of plastic and facial plastic surgeons perform the endoscopic forehead and brow lift, few of the surgeons who observe these procedures in the senior author’s practice believe that they can achieve the same results with an endoscopic approach compared with those after an open procedure.

Several factors may slow the transition of surgeons to an endoscopic method of forehead rejuvenation. Even today, published book chapters on brow lifting offer the opinion that excisional techniques last longer¹ without providing an objective basis for this observation. Moreover, endoscopic brow-lift techniques are widely regarded as more difficult to learn. On the other hand, surgeons who become facile with the endoscope rarely resort to open procedures.

There is clearly a dichotomy of opinion between surgeons. In the senior author’s experience, since first performing endoscopic procedures in 1989,² no differences in longevity between the coronal, pretrichial, or endoscopic procedures have been identified. In fact, over

the past two decades, the senior author has needed to lower some brows that had been endoscopically elevated in prior years. Likewise, there are examples of brows lifted through an open coronal approach with skin excision needing revision and re-elevation.

After successfully training more than a dozen American Academy of Facial Plastic and Reconstructive Surgery (AAFPRS) fellows, it is the senior author’s opinion that the endoscopic brow lift is not a difficult procedure to teach and learn. Furthermore, most, if not all, of the open brow lift maneuvers can be performed endoscopically. As in most surgical procedures, the “devil is in the details.” Consequently, this article focuses more on “practical” aspects of endoscopic forehead and brow lifting while assuming a basic fund of knowledge in surgery as we perform it and teach it to the AAFPRS fellows. The description of the endoscopic technique is purposefully detailed, as most of the procedure failures are usually due to inadequate release of tissues.

¹Division of Head and Neck Surgery, David Geffen School of Medicine at UCLA, Los Angeles, California; ²Division of Facial Plastic and Reconstructive Surgery, Department of Otolaryngology–Head and Neck Surgery, New York Eye and Ear Infirmary, New York, New York.

Address for correspondence and reprint requests: Grigoriy Mashkevich, M.D., Assistant Professor, The New York Eye and Ear Infirmary, Division of Facial Plastic and Reconstructive Surgery, 310

East 14 Street, New York, NY 10003, (e-mail: gmashevich@yahoo.com).

Management of the Aging Face; Guest Editor, Anthony P. Sclafani, M.D., F.A.C.S.

Facial Plast Surg 2009;25:222–234. Copyright © 2009 by Thieme Medical Publishers, Inc., 333 Seventh Avenue, New York, NY 10001, USA. Tel: +1(212) 584-4662.

DOI 10.1055/s-0029-1242034. ISSN 0736-6825.

WHAT ARE OUR GOALS?

Generally, patients who are reasonably well adjusted wish a restoration of their youthful appearance rather than a change in their appearance to reflect a more “perfect” appearance. Although we have outlined, in previous writings, “ideal” brow height, glide ratios, frame heights, and the like, few people actually possess these numbers. Whereas, in some instances, we are required to “change” appearances, we are often better off attempting restoration to the extent that it is possible to do so.

Symmetry

Improvement of symmetry is a goal of brow-lift surgery, and most patients have some asymmetry of the brow along with an underlying asymmetry of their bony facial structures. Old pictures of patients, during their younger years, often reveal both a brow and facial asymmetry. Computed tomography (CT) scans of their faces typically show a marked difference in the size and volume of the upper facial bony skeleton from side to side. Obviously, this affects the brow position, as the brow resides in relation to the bony structures.

Furthermore, some patients' brows are relatively more symmetrical at rest than they are during expression. Patients who lift one brow with expression (“unilateral brow elevators”) are common. These brows can be improved but often cannot be made symmetrical in that there is “asymmetry” in motion.

The surgeon has to be aware of these patients and observe their movements preoperatively. Although adjustments to the asymmetry are possible with several different techniques, the patient complaining of asymmetry with motion is rarely pleased, even by multiple operations (open, closed, or direct) performed by multiple competent and/or well-known surgeons. Photography with the eyes closed at rest and then with eyes open can demonstrate the unilateral brow lift. Often, forehead creases are unilateral as well.

Patients' brows can also be of different thicknesses and lengths from one side to another. Although asymmetry in brow length and thickness may be present naturally, it may go unnoticed as patients frequently tweeze and alter their brows.

Caution and realistic expectations are important, as in other cosmetic surgery, and the perfectionist patient who desires symmetrical perfection more than restoration is unlikely, in our experience, to achieve satisfaction in our or other surgeons' hands. Still, improvement in brow symmetry is usually achievable.

Volume

One of the components of aging is loss of volume, particularly of the lateral brow. This reflects both bony and soft tissue loss. Volume restoration of the lateral

upper brow, through fat grafting, fatty superficial musculo-aponeurotic system (SMAS) grafts, implants, or other methods, is worthwhile to consider.

Still, volume replacement is usually not an end unto itself. It is our personal feeling that the aging brow and forehead, with associated brow ptosis and glabellar rhytides, results primarily from a downward shift of the upper facial structures.

Certainly, the agonist/antagonist relationship of the facial muscles plays a role in brow aging. The successful use of Botox (Botulinum toxin type A, Allergan, Irvine, CA) to partially correct the aging forehead and brow attests to this.

Brow Elevation

Brows do fall, but primarily at the brow tail. The agonist/antagonist relationship between brow elevators (frontalis muscle) and depressors (corrugator, depressor supercillii, procerus, and orbicularis muscles) is more pronounced where frontalis insertion is absent at the tail of the brow. Hence, the lateral tail of the brow descends to a greater degree than does its medial counterpart.

For this reason, fixation of the brow is always as far lateral a point as possible. Often, the only fixation that we perform is at the high point of an extended lateral temporal incision, near the temporal line.

If we choose to fixate over the frontal bone, we strive to place the fixation as close to the temporal line as possible. A lateral fixation at the temporal line results in less medial brow elevation than does a fixation 4 cm from the midline where frontal fixation is commonly placed. A lateral fixation also results in less “splay” of the brow head in the glabella. By placing frontal fixation lateral, the brow tail is most affected by the vertical vector of pull, while the brow head is affected the least.

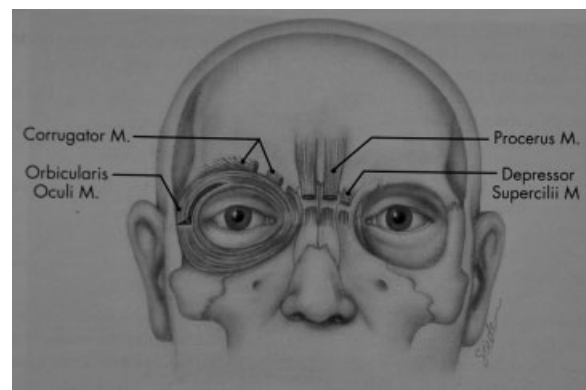


Figure 1 Myotomies of the depressor muscles (corrugator, orbicularis oculi, depressor supercillii, and procerus) performed to “release” the brow. (From Keller GS. Endoscopic Facial Plastic Surgery. St. Louis, MO: Mosby-Year Book Inc.; 1997:55. Reprinted with permission.)

Whereas it is possible to “overelevate” the lateral brow, this is not the usual case. “Cat Woman” eyes are possible to achieve but require more than the usual effort.

Elevation of the brow in its medial portion is usually achieved simply by releasing the brow depressor muscles (Fig. 1). At times, even releasing the depressors (should the frontal ligaments be severed) can require the surgeon to actually adjust the medial brow lower while raising the lateral brow.

Formerly, we attempted to elevate the brow over 5 mm. This is rare today. In women, we strive to lift the brow only 2 to 3 mm at its medial portion, to a point at or just above the bony rim. Because of its lower initial position, the lateral portion is often elevated to a greater extent but usually falls at approximately the same horizontal level as that of the medial portion. Typically, lateral brow elevation removes the “visor” of skin that overhangs the lateral canthus and bony orbit. If indicated, excess eyelid skin and ptosis repair is premeasured with the anticipated brow elevation and is performed prior to the brow lift.

Of course, there are patients with varying desires. To the extent that these requests are reasonable, they are honored. With a complete “release” of muscle and fascia attachments, the brow (with rare exceptions) can be placed as desired.

Glabellar, Lateral Orbital (“Crow’s-feet”), and Frontal Rhytides

Smoothing of the brow rhytides changes the expressive countenance of a patient. The “angry,” “sad,” or “tired” expression produced by a corrugated forehead and glabella is one of the primary targets of endoscopic foreheadplasty. Even the release of less severe rhytides is possible using endoscopic techniques. It is extremely rare that open techniques or incisional surgery upon the frontalis muscle are necessary.

Interestingly, myotomy of the corrugators alone will not suffice to elevate and/or release the brow. Nor will neurotomy of the frontal nerve supply to the corrugator. The procerus and depressor supercilii are the chief depressors of the brow, and myotomy of these muscles is required to alter the expression and release the brow. These muscles appear to receive their innervation from the zygomatic branch of the facial nerve.

Expanding and undermining the orbicularis oculi muscle in a superior and a superior lateral direction is required to achieve reduction of lateral crow’s-feet and elevation of the lateral brow. To accomplish this goal, release of the orbicular retaining ligaments and frontal retaining ligaments, as described later, is necessary. Myotomy of the orbicularis muscle is performed, on occasion, and in the absence of a dry eye.

THE PROCEDURE: KELLER’S RULES OF FOURS

Rule 1: Four Layers to Know and Dissect

1. Temporal parietal fascia (superficial fascia) and fat pad
2. Innominate fascia
3. Superficial layer of deep temporal fascia (intermediate fascia)
4. Subperiosteal

Rule 2: Four Areas of Adhesion to Release

1. Lateral orbital thickening (precanthal tendon)
2. Conjoint fascia and tendon (frontal ligament)
3. Arcus marginalis and associated periosteum
4. Muscular zone (corrugator, depressor, orbicularis, procerus)

Rule 3: Four Danger Zones in the Dissection

1. Temporal vein and nerve lateral to the sentinel vein (VII)
2. Temporal vein 0.5 cm lateral to the brow (VII)
3. Supraorbital nerve foramina zone 2 cm superior to the brow (V)
4. Deep branch of the supraorbital near the paramedian incision (V)

Rule 4: Four Common Methods of Fixation

1. Screw
2. COAPT plate
3. Bone tunnel
4. Suture fixation (temporal parietal fascia to the deep temporal fascia)

Rule 5: Four Most Common Incisions

1. Midline
2. Paramedian
3. Lateral frontal (superior temporal line)
4. Lateral temporal

Incisions

Incisions are patterned to fit the goal at hand. Their placement becomes easier once the goals of surgery are clearly defined.

For most patients, who require mostly lateral brow elevation in the 2- to 4-mm range and demonstrate adequate hair with normal forehead height, a vertical midline incision is placed immediately behind the hairline and carried through the frontalis and periosteum.

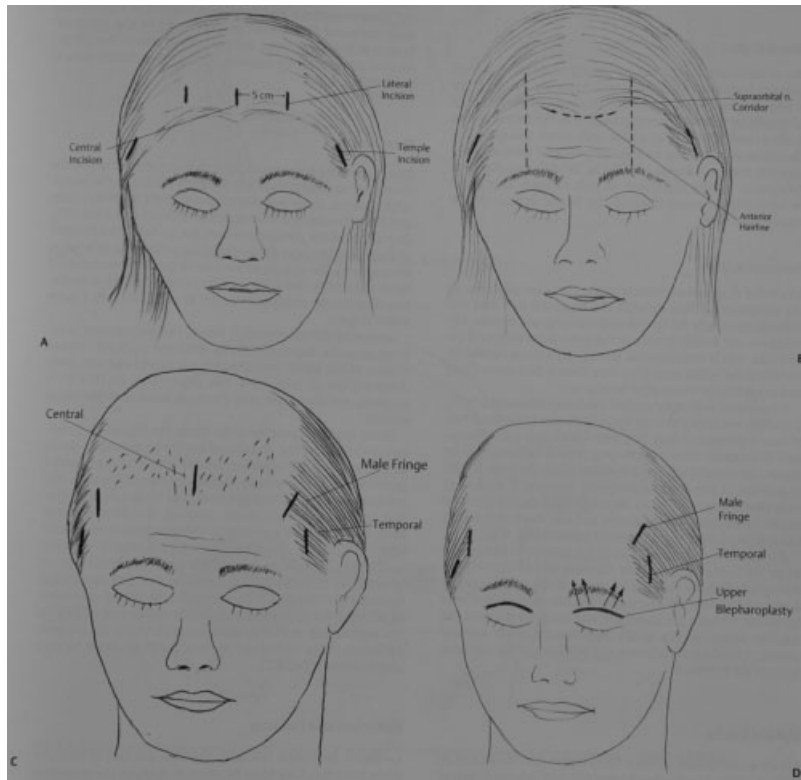


Figure 2 (A) Standard endoscopic forehead incisions. (B) Alternate incisions for female patients with high hairlines. (C) Endoscopic forehead incisions for male pattern baldness (Norwood II to V). (D) Endoscopic forehead incisions for male pattern baldness (Norwood VI to VII). (From Truswell WH. *Surgical Facial Rejuvenation: A Roadmap to Safe and Reliable Outcomes*. New York, NY: Thieme Medical Publishers; 2009:65. Reprinted with permission.)

Paramedian vertical incisions are then placed ~5 cm on either side of the midline incision, also directly behind the hairline (Fig. 2). These incisions are performed only to the fascia overlying the frontalis muscle. The frontalis muscle and galea are then carefully severed in the oblique direction of the lateral branch of the supraorbital nerve using blunt scissors with a spreading motion.

The deep, lateral branches of the supraorbital nerve usually lie between 0.5 and 1.5 cm lateral to the superior temporal line at the hairline. They normally are located between the galea and the periosteum. By using blunt dissection, an effort is made to identify and preserve these nerves. The vertical paramedian incisions are then carried through the periosteum.

Formerly, we limited the size of midline and paramedian incisions to 1 to 2 cm. However, we have found that longer incisions greatly assist in the forehead dissection and lead to a diminished hair loss, due to less endoscope “rub.” In addition, the longer vertical incisions are extremely difficult to find and usually heal “hair to hair” across themselves, provided that no tension is placed upon them. Consequently, 3-cm-long incisions are commonly used today.

If a face-lift is performed or has been performed in the past, the temple incisions are those of a face-lift. Otherwise, the incisions are placed in the approximate line where a face-lift incision might be placed in the

future. The midpoint of this incision is usually found by placing an oblique line drawn between the nasal ala and the lateral canthus to a point where it intersects with the temporal incision line. The incision may be extended upward toward the temporal line if fixation of the lateral brow requires it.

If hairline lowering (as in a patient with high forehead) is desired, a trichophytic incision is placed immediately within the hairline between two vertical lines drawn upward from the origins of supraorbital nerves (Fig. 2B). This incision is carried to the frontalis muscle, followed by a subcutaneous dissection inferiorly for 2 to 3 cm. One or two vertical incisions are then made in the frontalis and carried to the periosteum. The frontalis is emphatically not incised horizontally, as the resultant forehead deactivation can give an “odd” look.

If medial brow elevation is desired, the excess skin over the frontalis muscle is excised. If medial brow elevation is not desired, advancement of the posterior scalp forward is performed. The scalp is fixed with a COAPT Endotine plate (COAPT Systems, Palo Alto, CA), oriented in a retrograde direction. Skin over the frontalis is then excised. The length of the incision limits the amount of forehead lowering, but usually 0.5 cm of lowering can be attained.

Male patients demand creativity in the placement of incisions. Most prefer to avoid a visible scar, though

there are many examples of men satisfied with a mid-frontal incision placed in a forehead crease. As there is a potential to create a visible scar, direct brow or mid-forehead lifts are usually avoided, with the exception of occasional patients (seen once every few years in the senior author's practice).

For males with a severe temporal recession or balding with a frontal forelock (Norwood I to III), two median incisions are placed in the midfrontal area, assuming a stable hair loss pattern. Temporal incisions are then placed either in the midtemporal area or at the temporal fringe, depending on the hair pattern (Fig. 2C).

For males with more severe balding (Norwood IV to V), lateral incisions are made lower on the temporal fringe. Usually, most of the necessary work is performed through these two incisions. If necessary, temporal incisions can be placed more lateral for triangulation access to the temporal areas. In the midline, upper blepharoplasty incisions can be used for a retrograde midline access (Fig. 2C).

Instrumentation

Our instrumentation for brow surgery is not extensive. We use one periosteal elevator that is curved downward and two relatively straight elevators, a 30-degree endoscope with a downward open dissection sheath and irrigation portal, and two scissors (curved and straight) to complete the specialty instrumentation. For cautery and suction, we use a disposable suction cautery similar to what is used for tonsil dissection. We are currently working with PEAK Surgical (Palo Alto, CA) to use their PlasmaBlade to diminish ecchymosis during the dissection.

Frontal Cavity Creation

Unlike endoscopic sinus, endoscopic abdominal, or other endoscopic surgeries, no natural cavities exist over the frontal, temporal, or midface areas in which the surgeon can place an endoscope. Consequently, it falls upon the surgeon to create a cavity in which he can access the structures that tether the brow and frontal areas.

Over the frontal bone, we have created these cavities in the subperiosteal, subgaleal, and subcutaneous planes. Similar to open surgeries, each has its advantages and disadvantages. Over the years, however, most surgeons have adopted subperiosteal techniques. For this reason, subperiosteal undermining over the frontal bone is going to be discussed in detail.

First, a zone in the form of an arc with a radius of 2 cm is delineated from brow head to brow tail to protect the supraorbital nerve and lateral supraorbital nerve branch emerging from a foramen above the bony rim. Blunt subperiosteal undermining, without the endoscope, is performed with an elevator curved down almost

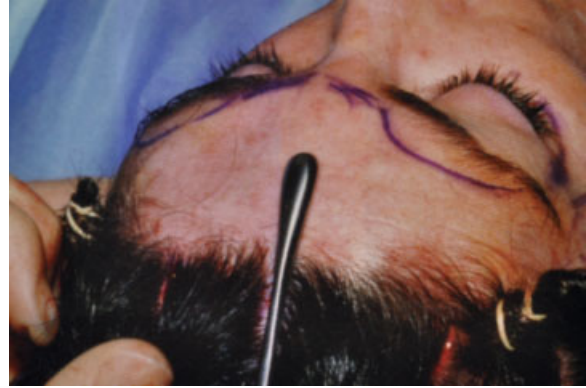

Figure 3 Elevator used to blindly undermine in the subperiosteal plane over the frontal bone. A semicircular area above the supraorbital nerve is not elevated. (From Keller GS. *Endoscopic Facial Plastic Surgery*. St. Louis, MO: Mosby-Year Book Inc.; 1997:57. Reprinted with permission.)

90 degrees at the tip (Karl Storz, El Segundo, CA) to the delineated markings (Fig. 3).

In the glabellar region, this dissection is carried to the origin of the corrugators in the midline. The dissector then “pops through” the periosteum and enters the subgaleal plane over the nose. This leaves the origin of the corrugators and neighboring ligaments intact.

Near the temporal line, the subperiosteal dissection is taken to the level of arcus marginalis. The arcus is not elevated at this point, however, to allow either subperiosteal or supraperiosteal dissection over the maxillary process of the frontal bone.

Temporal Cavity Creation

The temporal incision is carried through skin and temporoparietal fascia to the superficial layer of the deep temporal fascia, overlying the temporal muscle. The temporoparietal fascia moves when pulled with

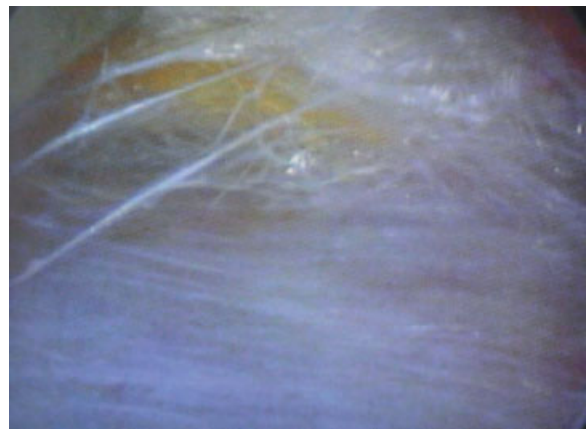


Figure 4 Loose areolar tissue of the innominate fascia is swept upward. (From Keller GS. *Endoscopic Facial Plastic Surgery*. St. Louis, MO: Mosby-Year Book Inc.; 1997:58. Reprinted with permission.)

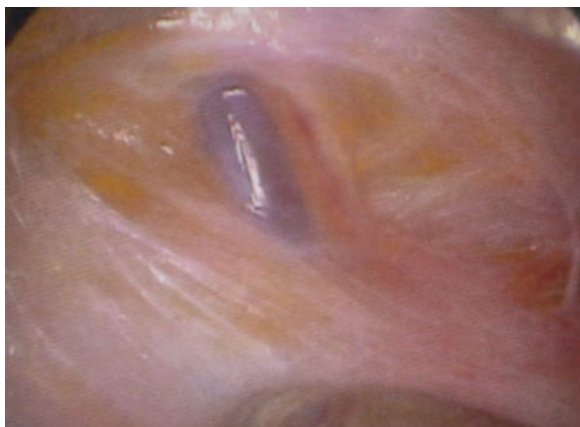

Figure 5 Sentinel vein is uncovered. (From Keller GS. Endoscopic Facial Plastic Surgery. St. Louis, MO: Mosby-Year Book Inc.; 1997:60. Reprinted with permission.)

the skin. The superficial layer of the deep temporal fascia is a glistening gray layer that does not move with pull on the skin.

During the dissection, tissue layers are separated with blunt scissors, spreading to identify branches of the facial nerve. Between the temporoparietal fascia and the superficial layer of the deep temporal fascia, there exists a loose areolar layer, the innominate fascia. This layer consolidates, when pushed upward to form a layer of fascia that forms the “basement” of the temporal fat pad containing the facial nerve. It is emphatic that the surgeon elevates the entire innominate fascia to protect the facial nerve (Fig. 4).

Grasping the temporal incision edge with an Adson-Brown pickup, dissection is carried bluntly with the straight elevator in a posterior direction along the superficial layer of the deep temporal fascia under direct visualization. This creates a cavity, which can then be extended forward under direct visualization to the hairline.

Beyond the hairline, we elevate the temporal cavity under direct endoscopic control. Placing both

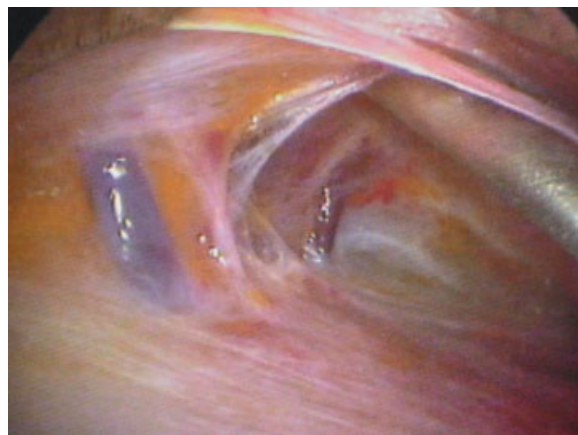

Figure 6 Dissection showing another vein lateral to that shown in Fig. 5. A nerve passing above this may represent a frontal branch of the facial nerve. (From Keller GS. Endoscopic Facial Plastic Surgery. St. Louis, MO: Mosby-Year Book Inc.; 1997:60. Reprinted with permission.)

the 30-degree endoscope and the straight dissector into the temporal incision, the innominate fascia is swept upward along with the temporal parietal fat pad. This dissection is quickly advanced to the temporal line, to the lateral orbital rim, and the malar eminence.

Below a horizontal line drawn laterally from the tail of the brow, a yellow tinge to the fascia is visible. This yellowish tinge marks the boundary of the superficial temporal fat pad, separating the deep from the superficial layer of deep temporal fascia. We do not incise this fascia to avoid traumatizing the fat pad and causing postoperative wasting of the temple.

The sentinel vein, one of the zygomatico-temporal veins, is visualized at the level of the zygomatico-frontal suture (Fig. 5). Lateral to this, the zygomatico-facial nerve, often accompanied by a second vein is seen at the lateral malar eminence (Fig. 6). Dissection into the mid-face is safe between these two landmarks. If necessary, the sentinel vein can be safely cauterized with bipolar cautery to improve access and ease of dissection (Fig. 7).

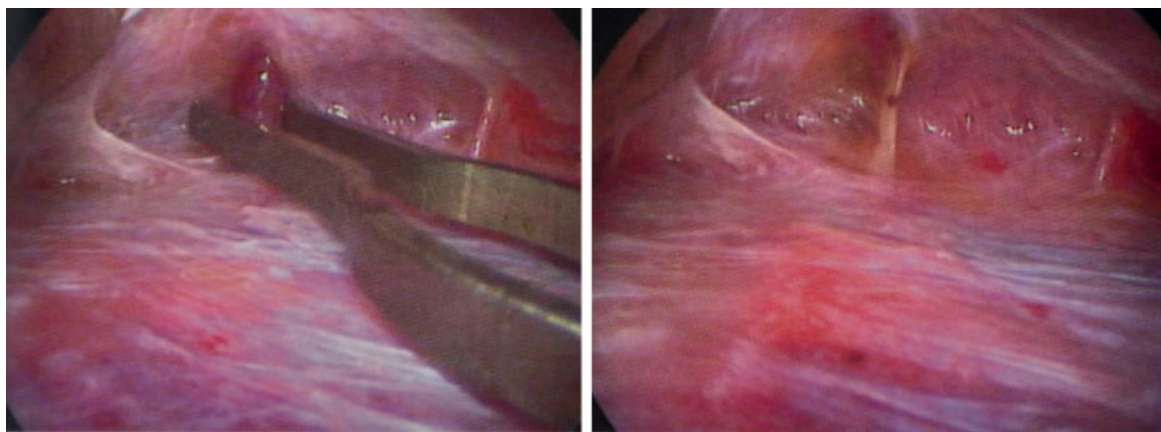


Figure 7 (Left) Bipolar cautery is placed on the sentinel vein. (Right) Sentinel vein is cauterized. (From Keller GS. Endoscopic Facial Plastic Surgery. St. Louis, MO: Mosby-Year Book Inc.; 1997:61. Reprinted with permission.)

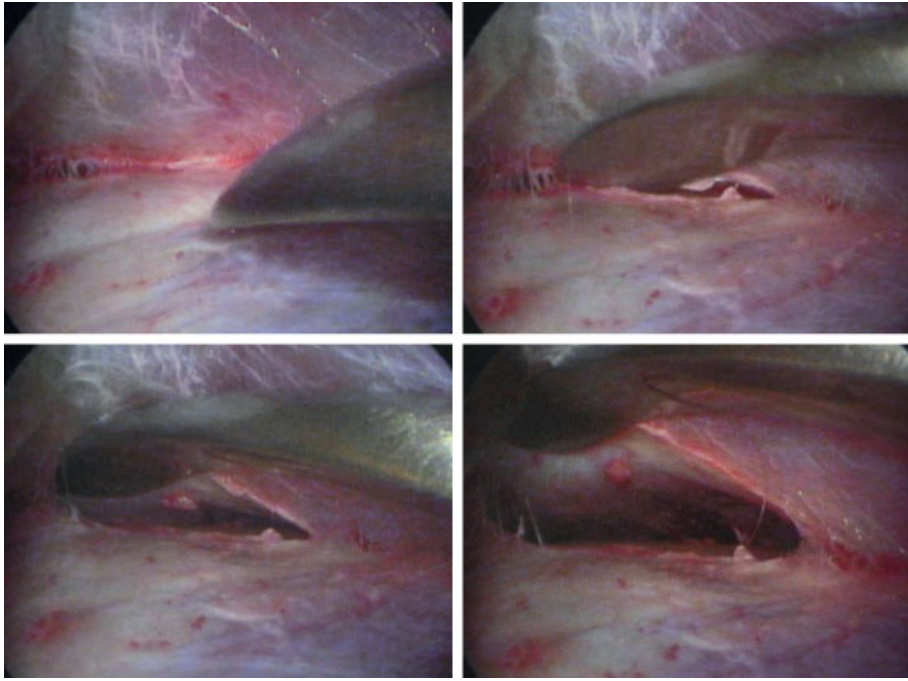


Figure 8 (Top Left) Periosteal elevator is placed on the temporal line. (Top Right) Incision of the frontal periosteum at the temporal line. (Bottom Left) Elevation of the frontal periosteum. (Bottom Right) Connection of the temporal and frontal dissections from lateral to medial. (From Keller GS. Endoscopic Facial Plastic Surgery. St. Louis, MO: Mosby-Year Book Inc.; 1997:62. Reprinted with permission.)

At the lateral orbit rim, the dissection meets resistance. This area of resistance represents the thickened lateral orbicularis retaining ligament, also called the “precanthal tendon” or “lateral orbital thickening (LOT).”

The orbicularis attaches only medially to the medial orbital margin and the medial canthal tendon. Elsewhere, the orbicularis is attached by retaining ligaments from the periosteum to the fascia on its under-surface. At the lateral edge of the lateral orbit, the retaining ligaments thicken, especially in the area of the lateral canthus.

To elevate the brow, especially in its lateral aspect, the orbicularis muscle must be freed and elevated. The lateral orbital thickening (or precanthal tendon) is cut in a supraperiosteal plane with a scissors or, for diminished bruising, the PEAK PlasmaBlade.

Connecting the Frontal and Temporal Cavities

At this point in the dissection, there are two distinct cavities: the frontal and temporal. Connection of the two cavities is performed from the temporal side.

At the temporal line, there is a consolidation of fascias termed the “conjoint fascia.” Above the horizontal hairline, the curved-down elevator is used to elevate the conjoint fascia. Then placing both the 30-degree endoscope and the curved-down elevator into the lateral temporal incision, the conjoint fascia is elevated (Fig. 8). If needed, the elevator can be placed into the paramedian

incision and used in this incision to separate the conjoint fascia from lateral to medial.

As the orbital rim around the lateral brow is approached, the conjoint fascia thickens and is termed the “conjoint tendon” or the “frontal ligament.” Often there is a vessel in this area that can cause troublesome bleeding. This vessel must be coagulated cautiously, as the facial nerve is in this region. The facial nerve passes in the temporal parietal fascia ~0.5 cm lateral to the lateral brow at the superolateral orbit.

The conjoint tendon (or frontal ligament) is excised sharply, lifting the periosteal attachments with the curved-down elevator. After the conjoint fascia and tendon are incised and the periosteum is elevated from lateral to medial, the frontal cavity and the temporal cavity are connected.

If visualization permits, the surgeon may dissect the frontal cavity further from the temporal incision. Otherwise, the surgeon completes further elevation of the frontal cavity and release of the depressor musculature and arcus marginalis through the median and paramedian incisions.

Release of the Frontal Ligaments, Arcus Marginalis, and Depressor Musculature

The surgeon can perform further elevation of the periosteum to the level of the arcus marginalis in one of two ways. The endoscopic surgeon can use the dissection sheath with one hand to simultaneously elevate the

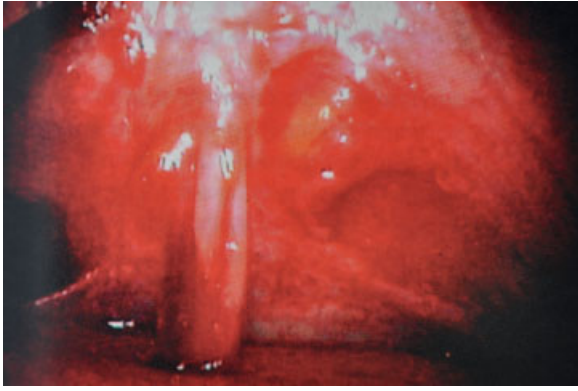


Figure 9 Supraorbital bundle is seen to emerge from a foramen 1.5 cm above the orbital rim. If the surgeon were to blindly undermine to the orbital rim, he or she would avulse the nerve on this side. (From Keller GS. *Endoscopic Facial Plastic Surgery*. St. Louis, MO: Mosby-Year Book Inc.; 1997:65. Reprinted with permission.)

periosteum and visualize the dissection. Alternately, the surgeon can triangulate, using the endoscopic sheath to retract and visualize, while using a curved-down elevator to elevate the periosteum.

By elevating the periosteum to the arcus marginalis under direct vision with the endoscope, the surgeon can avoid cutting the supraorbital nerve or a branch of the supraorbital nerve that emerges from a foramen (Figs. 9 and 10). The supraorbital nerve emerges from the orbit in an almost infinite variety of ways, and the surgeon needs to proceed cautiously in this area to avoid cutting or stretching this nerve or its branches.

Commonly, the supraorbital nerve emerges from a notch in the superior orbit, separate from the supratrochlear nerve. It separates into the medial, superficial, and lateral, deep branch. The most common

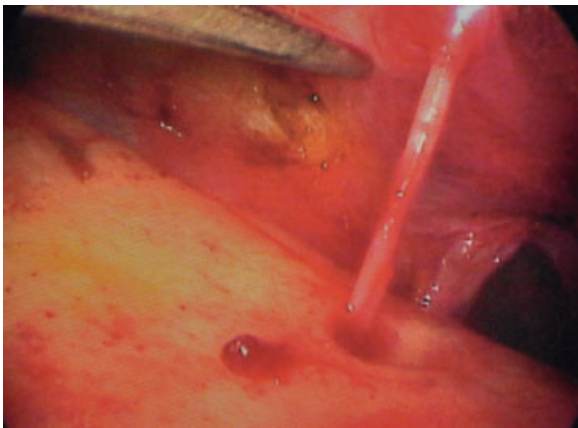


Figure 10 A left lateral supraorbital nerve branch is seen exiting from a foramen 1 cm above the orbital rim. The main supraorbital bundle is seen emerging from a notch below the supraorbital rim. (From Keller GS. *Endoscopic Facial Plastic Surgery*. St. Louis, MO: Mosby-Year Book Inc.; 1997:65. Reprinted with permission.)

location of this notch is approximately superior to the medial limbus.

The supraorbital nerve can also emerge from a foramen above the orbital rim, encased in periosteum. This is most common on the patient's left side, but can occur on either. A notch may or may not be palpable.

Another common variant is where the medial branch emerges from a notch or foramen and the lateral branch emerges from a foramen. The supraorbital and supratrochlear nerves can also emerge together. The lacrimal nerve can also emerge from a lateral foramen and supply sensation to the lateral superior area adjacent to the orbit.

Whenever possible, these nerves should be preserved with delicate dissection to avoid microscopic stress fractures. Scalp numbness is not entirely preventable in every instance but can be minimized. In our hands, the use of the laser, plasma scalpel (PEAK Technologies), or the harmonic scalpel (Ethicon, Somerville, NJ), with "hands off" dissection, helps to diminish stress fractures and scalp numbness.

The periosteum over the orbit is elevated from lateral to medial with the dissecting sheath. Often, the arcus marginalis can be elevated easily with the dissection sheath. The arcus marginalis represents the insertion of the orbital septum to the periosteum. Once it is elevated, dissection can be carried along the orbital septum to the tarsal plate.

If there is resistance from a fibrous (or "tough") periosteum, the surgeon uses a knife, scissors, laser, plasma knife, or harmonic scalpel to incise the periosteum and push it upwards. On the right side (for a right-handed surgeon), the endoscope is placed in the midline incision and the knife, scissors, plasma blade, laser, or harmonic scalpel are used through the right paramedian incision. On the left side, the endoscope is placed through the left paramedian incision and the

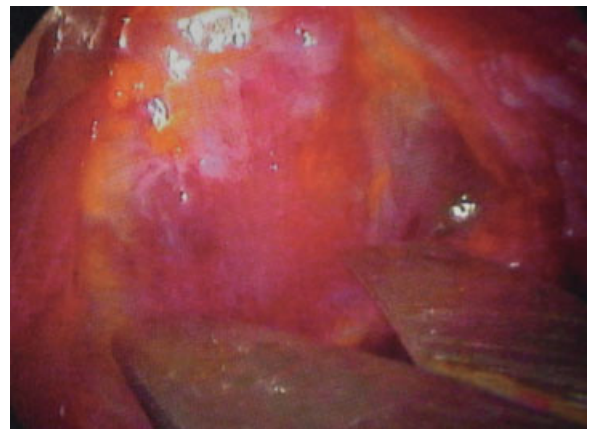

Figure 11 Incision of the procerus muscle with straight scissors. (From Keller GS. *Endoscopic Facial Plastic Surgery*. St. Louis, MO: Mosby-Year Book Inc.; 1997:68. Reprinted with permission.)

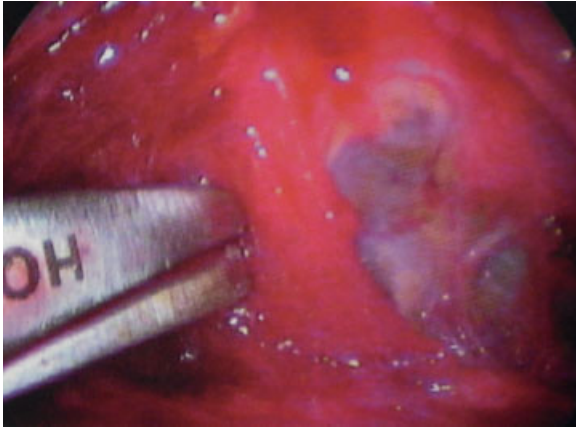


Figure 12 The corrugator muscle may be identified by its oblique course between the supraorbital and supratrochlear neurovascular bundles. Endoscopic scissors are used to divide this muscle. (From Keller GS. *Endoscopic Facial Plastic Surgery*. St. Louis, MO: Mosby-Year Book Inc.; 1997:68. Reprinted with permission.)

instrumentation is placed through the left side. The dissection is carried medial until the supraorbital nerve is identified.

Medial to the supraorbital nerve, and lateral to the corrugator insertions, the periosteum usually must be incised. The periosteum is then elevated, exposing the corrugator and procerus muscles. Either a scissors (used bluntly and sharply), a plasma knife (PEAK Surgical), an ultrasonic scalpel, or a laser are then used to incise the corrugator, depressor, and procerus muscles, preserving the supraorbital and supratrochlear nerve branches (Figs. 11 and 12).

Often, there is a large venous branch with a convoluted course that runs superficial and deep to the supraorbital nerve. It is essential to coagulate these branches with suction (tonsil) cautery prior to beginning the muscle dissection.

The muscle separation and dissection is performed in a variety of ways. We prefer to incise and divide the muscles completely in a horizontal plane. We make small incisions in the muscle and then bluntly push it apart, continuing this process until the dissection across the corrugator, depressor, and procerus muscles is complete.

The corrugator superciliaris arises from the medial end of the superciliary arch (bony prominence of the medial orbital rim) and departs obliquely, deep to the frontalis and superficial to orbicularis, to eventually merge with the frontalis muscle. It usually extends lateral and behind the supraorbital nerve and must be incised lateral as well as medial to the supraorbital nerve. The supratrochlear nerve either penetrates the muscle or lies anterior to it.

The depressor superciliaris lies anterior to the corrugator. Generally, its fibers are more vertically oriented

than those of the corrugator. Controversy exists whether the depressor is a separate muscle or a segment of the orbicularis.

The procerus is a vertical muscle that is lighter in hue than either the depressor or the corrugator and has a more vertical course. It arises from the tendinous fibers attached to the fascia covering the nasal bones and, after decussating with frontalis fibers, inserts into the skin of the lower part of the forehead. Supratrochlear vessels exit the orbit and pass superficial to the corrugator and deep to frontalis and orbicularis muscles.

We find that there is a much lesser incidence of numbness, paresthesia, or bruising postoperatively if a laser, plasma knife, or harmonic scalpel is used to separate the muscle compared with that after use of a scissor, knife, or cautery. Currently, our preferred method of muscle incision is with the plasma knife. We first use the “cut” mode to slightly incise and coagulate the muscle and then push the muscle gently apart.

If rhytides are minimal, we might make several incisions vertically in the corrugator, dividing it vertically medial and lateral to the supraorbital nerve, rather than incising it completely. If we do this, we are careful to incise the depressor and procerus (see later). We then “cross hatch” the musculature of the glabellar area between the brows with the plasma knife.

Undermining of the orbicularis muscle is performed both medially and laterally to the level of the tarsal plate along the orbital septum. If the orbicularis function is excellent, periorbicular eyelids rhytides are pronounced, and the eye is not dry, we will, on rare occasions, make a horizontal incision across the orbicularis above the lateral canthus. Usually, though, we undermine the orbicularis muscle into the midface to “stretch it out” and diminish rhytides.

We never rely on neurotomy alone to improve glabellar rhytides. The frontal branch of the facial nerve, which is the only nerve available for neurotomy, innervates the corrugator.

The depressor superciliaris (the primary depressor of the brow) and procerus receive their innervation from the zygomatic branch of the facial nerve and will continue to function (in time) with a neurotomy performed medial and lateral to the supraorbital nerve. Obviously, during myotomy of the corrugator, some degree of neurotomy also occurs.

At the end of the dissection, attention is turned to the lateral precanthal area (or lateral orbital thickening). Usually, further dissection and incision of this area is warranted. After further separation of the precanthal ligament, the brow tail loosens and becomes movable in all directions, often dramatically so. We do not usually incise the lateral canthal ligament, as we do not usually wish to elevate the canthus.

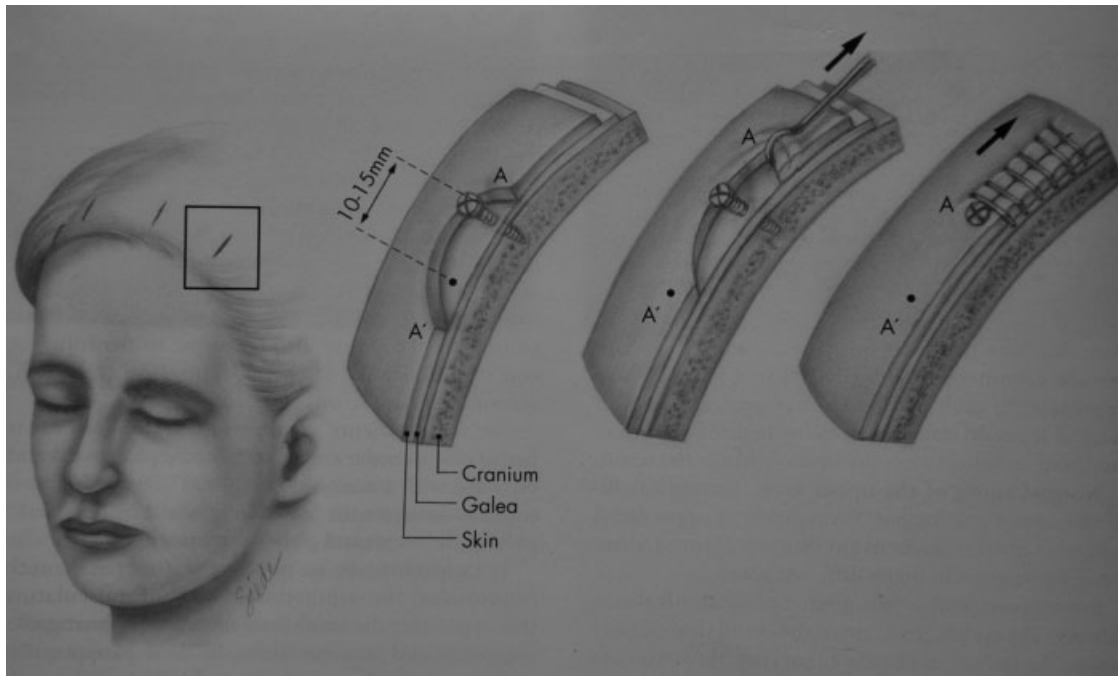


Figure 13 To elevate the brow a predetermined distance ($A'-A$), a screw is placed at A' , the scalp pulled back, and a staple placed behind the screw to hold the scalp in place. (From Keller GS. Endoscopic Facial Plastic Surgery. St. Louis, MO: Mosby-Year Book Inc.; 1997:72. Reprinted with permission.)

Rotation and Fixation to Elevate the Brow

After the dissection is complete, the brow is quite movable. As previously mentioned, we usually do not wish to elevate the medial brow more than several millimeters and rarely wish to elevate the lateral brow more than 5 mm (0.5 cm).

Usually, we fix the brow only from the temporal incision. If we have adequately released the brow, it is free to the extent that we can elevate it without any tension. Consequently, backward pull and suture fixation from the temporal parietal fascia to the superficial layer of deep temporal fascia, with a figure-of-eight interlocking suture, will usually place the lateral brow where we want it. If we are not confident that the brow is adequately fixated with posterior traction from the hairline at the temporal line or that it can be pulled backward to achieve the desired placement, we use a screw or an Endotine or Ultratine (COAPT Systems, Palo Alto, CA) method of fixation.

In this event, and if the patient is able to return for screw removal, we make a small stab incision (~5 mm long) to periosteum behind the hairline at the temporal line. We place a hook in the upper part of the incision and pull the brow backward to the desired position. We then relax the hook and drill a hole in the bone at approximately the midline of the incision. Pulling the incision backward against the screw, we place a staple behind the screw (Figs. 13 and 14).

Such fixation method enables easy adjustment in the postoperative period by releasing a staple and allowing the fixation to slide forward, lowering the brow.

Alternately, the incision can be extended inferiorly, allowing one to pull the fixation point posteriorly, raising the brow.

We usually remove the screw in ~2 weeks. Despite animal studies indicating that periosteal adherence is not complete until 6 weeks,³ we have not experienced a failure of fixation upon screw removal.

If the patient is not able to return for screw removal, we will commonly use a COAPT Ultratine plate. We will also use a larger Endotine plate for male patients with heavier brows or older patients with lax skin.

To accommodate the Endotine, we make a stab incision at the temporal line large enough to insert the plate and posterior enough to hide the plate behind the hairline, as the temporal hairline is advanced posteriorly to a slight degree. The plate is then inserted and fixed according to the company's directions. A manual surgical drill is used to create a hole, which should lie medial to the temporal fusion line and anterior to the coronal suture. The bone is suctioned to remove all debris. The Endotine device is then inserted firmly with the supplied insertion tool and is placed flush with the cranium. The forehead tissue is then repositioned and is firmly affixed onto the Endotine device with digital pressure, ensuring adequate penetration of tissue by the device tines.

On occasion, the medial brow needs to be lowered and the lateral brow elevated. In this event, we place an Ultratine or Endotine backward into the medial incision and pull the scalp forward.

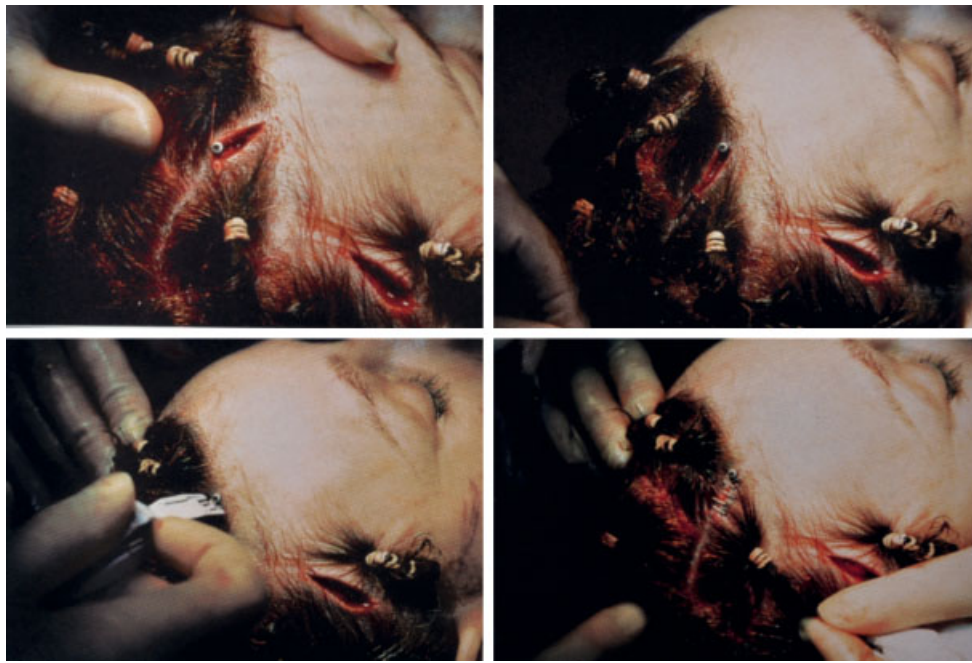

Figure 14 (Top Left) Titanium screw is placed 1.25 cm posterior to the anterior edge of the vertical right lateral incision. (Top Right) Hook is placed in the posterior edge of the incision and pulled backward until the screw sits at the anterior edge of the incision. (Bottom Left) Staple is used to close the incision behind the screw. (Bottom Right) Staples about screw holding fixation advancement in place. (From Keller GS. Endoscopic Facial Plastic Surgery. St. Louis, MO: Mosby-Year Book Inc.; 1997:73. Reprinted with permission.)

For a more substantial lowering of the brow, we make an incision immediately below the brow. After drilling a hole into the orbital rim at the lateral, and/or paramedian and/or medial brow, we suture fixate the

brow downward with a 4-0 Prolene (Ethicon, Somerville, NJ) suture.

The Ultratine and Endotine plate fixation also allows one to adjust the position of the brow in the

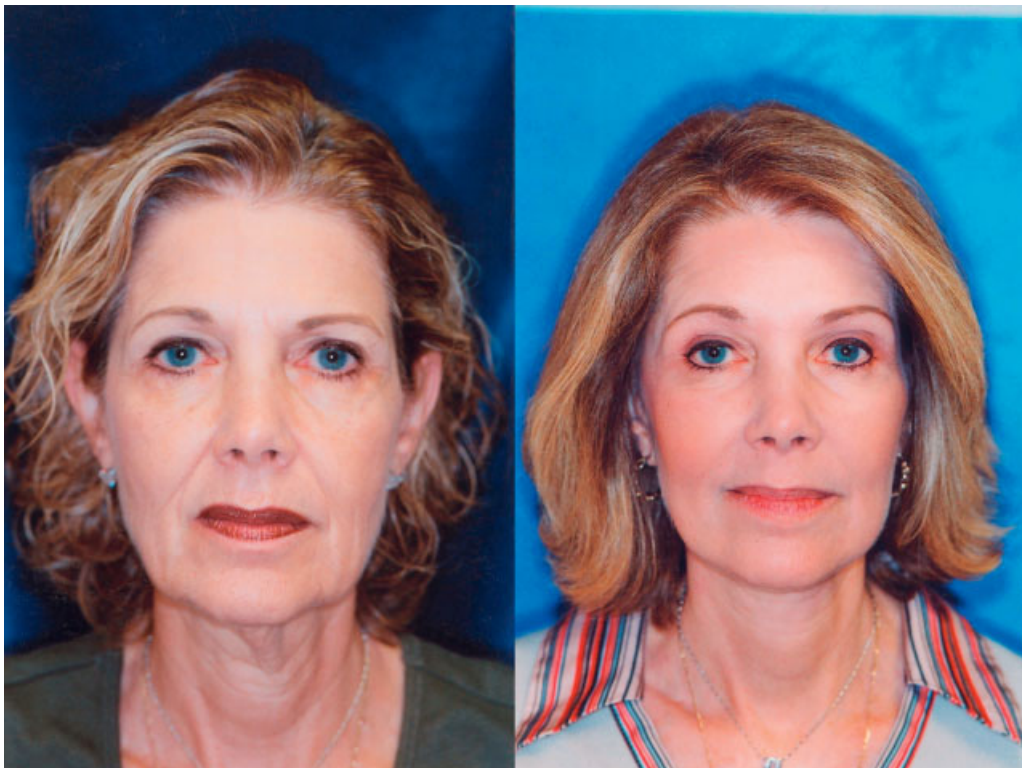

Figure 15 Preoperative and postoperative frontal views of a patient after an endoscopic forehead lift in addition to a blepharoplasty and face-lift. Note improvements in brow height and symmetry.

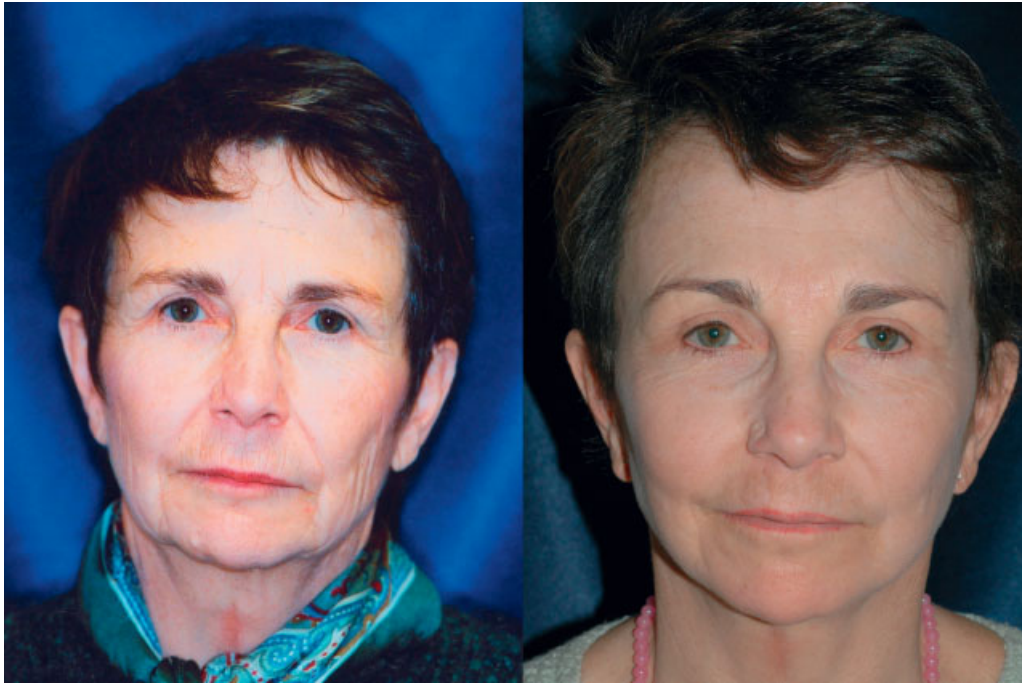

Figure 16 Preoperative and postoperative frontal views of a patient after an endoscopic forehead lift, blepharoplasty, and face and neck lifts. Note elevated brow position with aesthetic improvement of the brow arch.

postoperative period. By injecting local anesthesia into the scalp in the area over the device, the scalp can be moved posteriorly, inferiorly, and/or laterally.

We rarely use cortical bone bridges, although they are an excellent form of fixation. Our only objection to this technique is that it makes it difficult to adjust fixation in the postoperative period. When required, cortical bone bridges are created with a 1-mm drill bit by drilling two troughs into the diploic space, separated by ~ 2 mm of cortical bone. A permanent suture is then used to suspend the periosteum under the anterior aspect of the paramedian incision to the bone bar.

Postoperative Care and Follow-Up

Patients are given adequate pain medications and are seen in the office on the first postoperative day to assess all wounds and remove drains and bandages. Patients are instructed to apply ice to the face during the first 72 hours and avoid vigorous activity during the first 3 weeks after the operation. Showering with a mild shampoo is allowed starting on the third postoperative day. Temporal staples are removed at 7 to 10 days. Recovery of postoperative ecchymosis, if present, is hastened by the use of *Arnica montana* (cream and pills), available over the counter in most pharmacies.

Potential complications of endoscopic brow lifting include seroma, hematoma, numbness, motor paresis, transient alopecia, scarring, asymmetrical brows, and pruritus. Most of these resolve with conservative management and without any intervention.

Patients return for a follow-up visit at 3, 6, 12 months, and annually thereafter. Photographs are taken at each visit, in frontal, three-quarter, and profile facial views (Figs. 15 and 16).

CONCLUSION

During the previous two decades, endoscopic forehead and brow lifting has steadily evolved into the procedure of choice for the surgical rejuvenation of the aging forehead and brow complex. Precise and safe brow repositioning largely depends on detailed understanding of the regional neurovascular, muscular, and soft tissue anatomy, coupled with technical skill and comfort in using endoscopic equipment. In the authors' experience, endoscopic forehead and brow lifting provides natural, long-term results, with the elegance and minimal surgical morbidity associated with an endoscopic approach.

REFERENCES

1. Janis JE, Potter JK, Rohrich RJ. Brow lift techniques. In: Fagien S, ed. Putterman's Cosmetic Oculoplastic Surgery. 4th ed. Philadelphia, PA: Saunders; 2008:91–105
2. Keller GS, Hucherson R. Endoscopic forehead and brow lift. In: Keller GS, ed. Endoscopic Facial Plastic Surgery. Philadelphia, PA: Mosby; 1997:49–81
3. Sclafani AP, Fozo MS, Romo T III, McCormick SA. Strength and histological characteristics of periosteal fixation to bone after elevation. *Arch Facial Plast Surg* 2003;5:63–66