

# Management of the Aging Nose

Vito C. Quatela, M.D.,<sup>1</sup> and James M. Pearson, M.D.<sup>1</sup>

## ABSTRACT

As a growing segment of our population, mature patients seeking rhinoplasty for both functional and aesthetic reasons will increasingly be encountered by the facial plastic surgeon. The aging process is characterized by a gradual derotation and deprojection of the nasal tip. This article provides an overview of versatile and proven techniques that may be applied to the majority of aging nose rhinoplasty cases and that have been found to yield predictable and lasting results.

**KEYWORDS:** Rhinoplasty, aging nose, projection, rotation, nose-lift

Demographic changes in the United States over the next couple of decades will result in a rapidly expanding population of mature adults. By 2030, it is estimated that ~19.6% of the U.S. population will be 65 years or older.<sup>1</sup> In this population, rhinoplasty may be indicated for functional or cosmetic reasons or both. The facial plastic surgeon will increasingly be charged with addressing the needs of this growing patient population.

The surgeon should be mindful that patients of this age group may display characteristics not usually encountered in younger rhinoplasty patients. Some issues pertinent to the aging population include psychological motivation, medical comorbidities, anatomic changes typical of the aging process, and technical considerations to enhance the safety and predictability of rhinoplasty for the aging nose.

Psychologically, the patient's motivation for surgery should be assessed. Any recent traumatic events, such as the death of a spouse, should be elucidated. Surgical planning should allow for adequate time to elapse enabling the patient to adjust to new life circumstances prior to undertaking surgery. The surgeon should recognize that patients in this age group typically have a well-formed self-identity and may not be seeking or prepared for a dramatic change in nasal appearance.

Alternatively, patients who have lived their entire adult lives with what they consider to be an unsatisfactory nose may overestimate the magnitude of change that can be reasonably anticipated with rhinoplasty.<sup>2</sup> During consultation, a frank discussion should be undertaken about the patient's motivations and goals for surgery.

In terms of comorbidities, medical clearance should be sought from the patient's primary doctor. Specifically, cardiopulmonary issues, which are more common in this age group, including hypertension, coronary artery disease, and chronic obstructive pulmonary disease should be addressed and the patient's condition optimized prior to surgical intervention.

Age-related anatomic changes are most dramatic in the lower nasal third, which becomes relatively elongated. Consistently observed changes include thinning of the nasal skin, weakening of the nasal cartilages, and separation of the fibrous attachments between nasal cartilages.<sup>3</sup> The hallmark of nasal aging is loss of nasal tip support.<sup>4</sup> The loss of nasal tip support leads to gradual nasal lengthening, deprojection, and derotation. To address these changes, surgical techniques that increase projection and rotation are the focus of methods to surgically manage the aging nose. Various proven methods to accomplish those goals are described in this article.

<sup>1</sup>Department of Otolaryngology, University of Rochester, Rochester, New York.

Address for correspondence and reprint requests: James M. Pearson, M.D., Clinical Assistant Professor, Department of Otolaryngology, University of Rochester, 973 East Avenue, Suite 100, Rochester, NY 14607 (e-mail: dr.pearson@hotmail.com).

Management of the Aging Face; Guest Editor, Anthony P. Sclafani, M.D., F.A.C.S.

Facial Plast Surg 2009;25:215–221. Copyright © 2009 by Thieme Medical Publishers, Inc., 333 Seventh Avenue, New York, NY 10001, USA. Tel: +1(212) 584-4662. DOI 10.1055/s-0029-1242032. ISSN 0736-6825.

In addition to aesthetic effects, the same age-related anatomic changes may predispose to functional impairment. Some degree of nasal airway obstruction is often encountered in the aging nose. The sites of obstruction may be at the internal nasal valve or the external nasal valve.<sup>3</sup> Internal nasal valve dysfunction due to separation of the upper and lower lateral cartilages may be diagnosed using the Cottle maneuver and should be addressed with the placement of spreader grafts as usual.

Impairment of the external nasal valve may be due to tip ptosis or lateral nasal wall collapse or both. Using the methods described below to reposition a derotated and deprojected tip, some degree of external valve improvement is typically accomplished. While the nose is manually held in a more favorably rotated and projected position during examination, lateral nasal wall collapse may be noted during inspiration. In that case, the resiliency of the aging lateral crura may be compromised. Lateral crural strut grafting or alar batten grafting may be indicated.<sup>5</sup> Some authors have proposed that prophylactic grafting of the external valve area may be desirable in this population even when external valve collapse is not noted preoperatively.<sup>3</sup>

Given the anatomic changes inherent to aging, certain technical considerations should be heeded. First, nasal lengthening may result in the development of an apparent dorsal hump. Typically, if the hump was not present throughout adult life, it is merely an illusion resulting from nasal lengthening and derotation, which contribute to the appearance of dorsal convexity and may be interpreted as a hump. In reality, dorsal height may be well within normal limits once nasal projection and rotation are adjusted to the desired extent. Thus, prior to attempts at lowering dorsal height, the nasal surgeon should first visualize the ideal dorsal height by manually holding the tip in a desirable location. Only then should dorsal height be lowered as indicated. Using this method, excessive lowering of dorsal height may be avoided.

Second, the nasal bones may become brittle with advancing age, predisposing them to comminution during osteotomy performance. Many authors advise against performing osteotomies in this age group for that reason unless absolutely necessary. When osteotomies are indicated, several authors recommend using a transcutaneous external technique to minimize the chances of comminution.<sup>2</sup>

Third, atrophy of soft tissue constituents of the nose may lead to both diminished support and increased risk for visualizing imperfections through the skin-soft tissue envelope (SSTE). Similarly, ossification of septal cartilage may preclude its use as a grafting material. The patient should be counseled about and the surgeon should be prepared for the possible harvest of alternative sources of grafting material including auricular and costal cartilage.

## ANATOMY

The nasal tip is a dynamic structure, hinged by the upper lateral cartilages and by the recurvature of the lower lateral cartilages. Major and minor tip support mechanisms play a central role in tip stability and positioning.

The nasal tip is composed of the paired lower lateral cartilages, or alar cartilages, each of which may be divided into three crura: medial, middle, and lateral. The domal junction denotes the border between the lateral and middle crura, and the columellar junction separates the middle and medial crura<sup>6</sup> (Fig. 1).

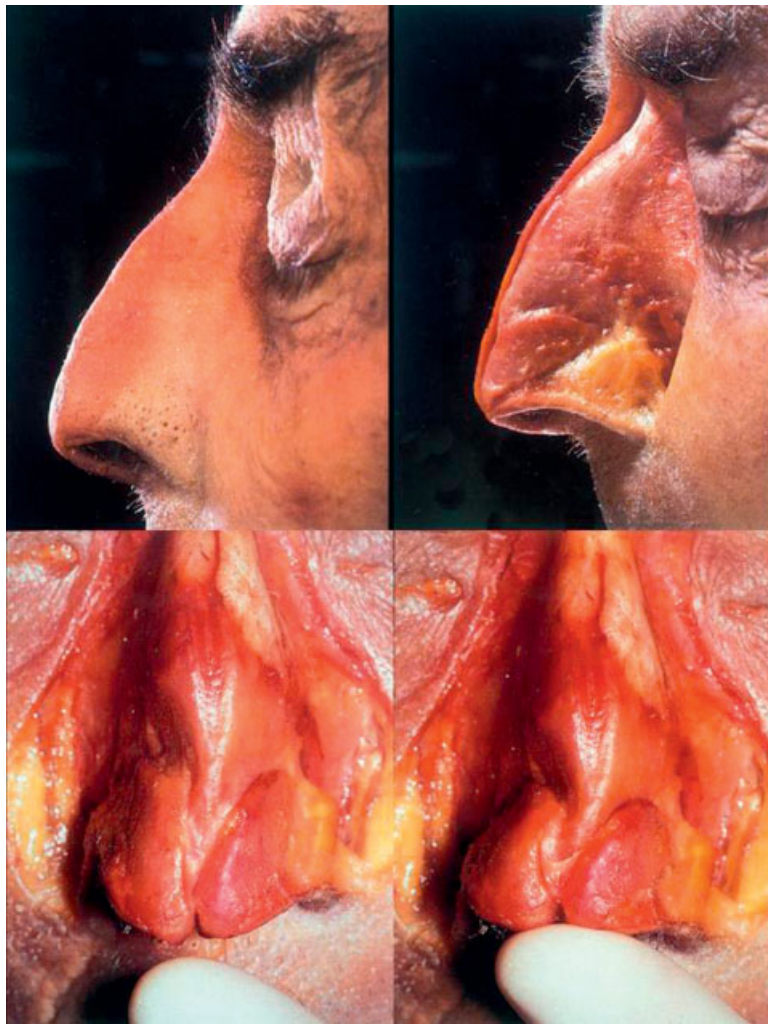
A key component of nasal tip anatomy lies in the scrolled attachment of the cephalic margins of the lower lateral cartilages to the caudal margin of the upper lateral cartilages. This region demonstrates characteristic changes during the aging process including gradual flattening of the cartilaginous recurvature and separation of the upper from the lower lateral cartilages. These changes have been demonstrated by histologic studies.<sup>7,8</sup>

## TIP UNDERPROJECTION AND UNDERROTATION

Nasal tip projection is defined as the horizontal distance from the alar crease of the facial plane to the nasal tip on lateral view, or the posterior-to-anterior distance that the nasal tip extends in front of the facial plane as seen on basal view.<sup>9</sup> The analysis of tip projection may be undertaken using several different techniques.

One of the most commonly used measurements is the Goode method, which defines ideal tip projection as a ratio of the distance from the nasion to the tip-defining points. Using the Goode method, this ideal ratio of tip projection to nasal length is 0.55:1 to 0.6:1.<sup>10</sup> Several alternate methods to define ideal tip projection have been proposed. With Simons's method, tip projection should equal the height of the upper lip. Crumley and Lanser described a right triangle with dimensions corresponding with nasal proportions; ideally, projection:height:length is equal to 3:4:5. Powell and Humphries defined the ideal relationship between tip projection and nasal height as a 2.8:1 ratio.

Nasal tip rotation is defined as movement of the nasal tip along an arc with constant distance from the facial plane.<sup>11</sup> A ptotic nasal tip may be otherwise described as underrotated. Thus, the terms *ptotic* and *underrotated* as applied to the nasal tip are used interchangeably. Tip rotation is described with reference to the Frankfurt horizontal plane and the long axis of the nostril. Ideally, the long axis of the nostril is oriented parallel to the columella, but often discrepancy exists between the two. When addressed surgically, the long axis of the nostril is first rotated to an angle favorable to the Frankfurt horizontal plane, then the columella is brought into balance with the ala.<sup>12</sup> The ideal angle varies with gender: For a woman an angle between 10



**Figure 1** Anatomy of the nose. The nasal tip is a dynamic structure, hinged by the upper lateral cartilages and by the recurvature of the lower lateral cartilages.

and 30 degrees is favored, whereas for a man an angle between 0 and 15 degrees is considered ideal.

### TIP SUPPORTS

The surgeon must understand the factors contributing to tip support and dynamics. Nasal tip support derives from the inherent strength of the lower lateral cartilages, the nasal septum, and the various ligaments and fibrous connections between the alar cartilages and adjacent structures. By convention, support mechanisms are divided into major and minor groups. The

major tip supports include the size, shape, and resilience of the medial and lateral crura of the lower lateral cartilages, the attachment of the medial crural footplate to the caudal septum, the scrolled attachment of the cephalic margins of the lower lateral cartilages to the caudal margin of the upper lateral cartilages and the interdomal ligamentous sling. The minor tip supports generally include the dorsal septum, membranous septum, anterior nasal spine, attachment of the lower lateral cartilages to the SSTE, the thickness of the SSTE, and the lateral crural attachment to the pyriform aperture (Table 1).

**Table 1 Nasal Tip Support Mechanisms**

Major Group	Minor Group
<ul style="list-style-type: none"> <li>• Strength and shape of lateral crura</li> <li>• Strength, shape, length of medial crura</li> <li>• Upper lateral union to lower lateral</li> <li>• Medial crural–septal fibrous union</li> <li>• Interdomal ligamentous sling</li> </ul>	<ul style="list-style-type: none"> <li>• Cartilaginous dorsal septum</li> <li>• Lateral crura–pyriform aperture</li> <li>• Skin thickness and its attachment to cartilage</li> <li>• Nasal spine</li> </ul>



The tripod theory, as proposed by Jack Anderson, provides a conceptual model with which to understand the relationship between projection and rotation. Importantly, it can be used to predict the effects that alar cartilage-modifying maneuvers are likely to have on both tip projection and rotation.

The tripod theory postulates that nasal tip projection and rotation may be understood by considering the tip as a tripod composed of the conjoined medial crura as the inferior tripod leg and the lateral crura as the two superior tripod legs. By changing the length of one component of the tripod, a corresponding change in nasal tip projection and rotation can be anticipated. For example, shortening the two lateral crura would be expected to increase tip rotation along with slight deprojection. Likewise, lengthening the conjoined medial crura alone would increase both projection and rotation.

### METHODS OF INCREASING NASAL PROJECTION AND ROTATION

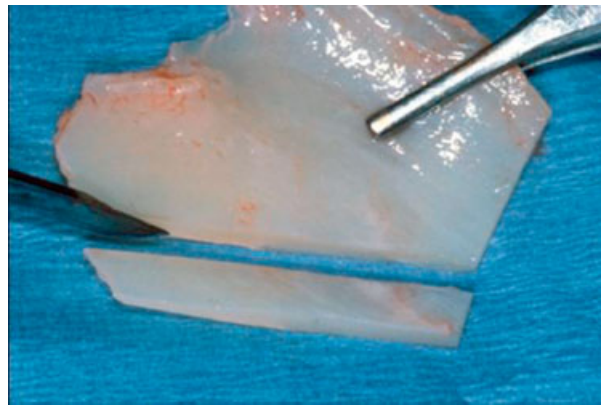
Alar cartilage-modifying techniques to address tip underrotation and underprojection in the aging nose include insertion of a columellar strut, tip grafting, *lateral crural steal*, *lateral crural overlay*, and the *tongue-in-groove* techniques. Adjunctive maneuvers commonly used in aging nose rhinoplasty include addressing alar-columellar discrepancy, premaxillary grafting, alar cephalic trim, and direct excision of excessive dorsal skin. Each of these options will be described below.

The surgical techniques described in this article may be used either independently or in combination depending on the findings and contributing factors present in each case, as well as on the degree of rotation or projection intended.

#### Columellar Strut

The columellar strut graft, along with septocolumellar fixation, provides the foundation upon which to rebuild and refine the nose. The structural integrity of the tripod segment formed by the conjoined medial crura is often compromised in the aged nose. That compromise may be due to congenitally weak crura, to traumatic or iatrogenic damage to tip support mechanisms, or to age-related resorption of the fat pad below the medial crura or of the premaxilla itself.<sup>5</sup> The latter is especially likely in the edentulous patient, where the loss of masticatory forces allows for the gradual resorption of bone in that region. Regardless of the etiology, the effects of diminished integrity of this inferior tripod segment cause the nose to collapse toward the face, effectively deprojecting and derotating the nasal tip.

A sturdy fragment of cartilage is desirable for columellar strut grafting. A favorable piece of septal



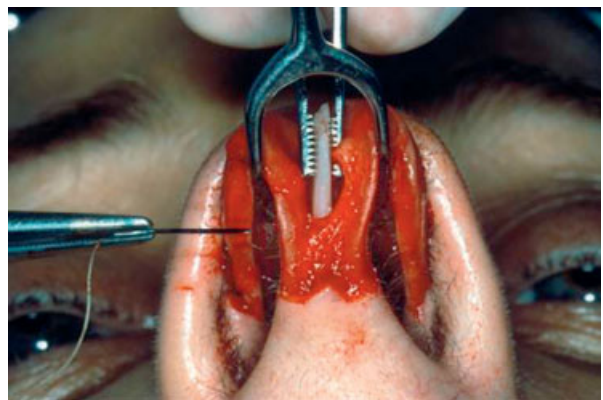
**Figure 2** Columellar strut: A sturdy strut is harvested from along the inferior border of nasal septal cartilage.

cartilage can usually be harvested from along the floor of the nose where the cartilaginous septum joins the maxillary crest (Fig. 2). After harvest, the graft is further trimmed to the appropriate size and shape using a no. 15 blade and a cutting block. A graft measuring 20 mm in length and 3 to 5 mm in width is typically adequate.

Once the columellar strut graft is prepared, a pocket is dissected between the limbs of the medial crura in the direction of the nasal spine while carefully preserving a layer of soft tissue overlying the nasal spine (Fig. 3). The columellar strut is then inserted into this pocket, to a depth that preserves a soft tissue cushion between the deep aspect of the strut and the nasal spine. The columellar strut is then sutured to the medial crura using multiple 4-0 plain gut sutures in horizontal mattress fashion.

The columellar strut adds substantially to the stability of the nasal base. In a study that employed objective measurements of nasal support in patients undergoing rhinoplasty, placement of a columellar strut alone increased nasal tip support 40% over baseline in the vector of the columella.<sup>12</sup>

Once the columellar strut is secured, the surgeon can then closely evaluate the contribution of the lateral



**Figure 3** Placement of the columellar strut in a pocket dissected between the medial crura.

crura to tip rotation. Considering again the tripod model, disproportionately long lateral crura will tend to have a derotating effect on the nasal tip. At this juncture, the surgeon may wish to consider using one of two cartilage-modifying techniques described for this purpose: the *lateral crural steal* or the *lateral crural overlay*. Both maneuvers increase rotation. The choice as to which technique to employ depends upon the status of tip projection and the need for increased projection versus the preference to maintain projection or deproject the tip.

### Tip Graft

Tip grafting is a powerful tool that can provide additional structural support as well as projection to the nasal tip. The tip graft was developed to provide a stable and durable tip support that appeared natural over time.<sup>13</sup> The graft is fashioned from autogenous cartilage, preferably septal cartilage, and is secured at the caudal margin of the medial crura. It should extend from the proximal end of the conjoined medial crura to just beyond the domes. The tip graft can provide a small increase in tip projection as well as a refined tip contour that accentuates favorable nasal light reflexes.

The shape of the graft is roughly hexagonal, with the projecting end wider than the proximal end. It is carved intentionally longer than required and fixated to the caudal border of the medial crura using 6-0 nylon sutures. Once in place, its shape and size are refined using a no. 15 blade to shave the cartilage to the exact specifications indicated. Circumferential beveling should be performed to minimize visible edges, an important consideration given the thinning of the SSTE often observed in the aging population.

### Lateral Crural Steal Technique

If increased rotation and projection are desirable, the *lateral crural steal* technique may be employed. This maneuver entails placing an interdomal mattress suture in such a way as to advance the lateral crura onto the medial crura.<sup>14,15</sup>

### Lateral Crural Overlay Technique

If increased tip rotation along with decreased projection or maintenance of projection is desirable, the *lateral crural overlay* technique may be employed. This maneuver involves dividing the lateral crura at its midsection and overlapping the proximal ends over the distal ends, then suturing the overlapped ends together using horizontal mattress sutures.<sup>14</sup> The degree of overlap is modified to impart the desired amount of tip deprojection. With regard to the tripod theory, lateral crural overlap effectively shortens the upper tripod limbs,

resulting in decreasing projection along with increasing rotation.

### Tongue-in-Groove Technique

The *tongue-in-groove* technique is another method of increasing tip rotation and controlling tip projection. The technique consists of advancing the medial crura cephaloposteriorly onto the caudal septum into a surgically created pocket between the crura.<sup>9</sup> The amount of tip rotation may be adjusted based on the degree of superior advancement of the medial crura onto the septum. Similarly, the projection may be decreased by positioning the medial crura posteriorly onto the septum. When the tongue-in-groove technique is employed, columellar strut placement is typically not required because the caudal septum takes the place of the columellar strut in stabilizing the medial crura and the base of the nose. Advocates of this technique note the predictability of the final tip position in comparison with that of other cartilage-modifying techniques that may be subject to changes with contracture during healing.

### Adjunctive Techniques and Other Considerations

Excessive caudal projection of the septal quadrangular cartilage may contribute to alar-columellar discrepancy or "columellar show" resulting in apparent underrotation of the nasal tip. Similarly, excessive caudal projection of the medial crural cartilages may contribute to the same problem.

Inadequate projection may arise from diminished support at the base of the lower tripod limb, where the medial crural feet lie adjacent to the premaxilla. In that situation, the lower limb of the tripod is weakened and apparently foreshortened. A useful technique to address this finding is the premaxillary graft. A graft of septal or auricular cartilage is placed in a surgical pocket at the base of the columella, beneath the feet of the medial crura and overlying the central premaxilla.<sup>16</sup> This maneuver moves the lower limb of the nasal tripod anteriorly, effectively raising the height of the base of that tripod limb and contributing to tip projection.

Direct excision of excess dorsal nasal skin may be indicated in the older patient. Given the multiple rhytides and lower incidence of unfavorable scar formation in this population, external incisions are more easily camouflaged. Skin excision can be performed either along the upper third of the nose in a horizontal crease or along the nasal dorsum or supratip to facilitate favorable redraping of the SSTE over the nasal structure.<sup>5</sup>

Excessively wide lateral crura may contribute to tip ptosis. A simple alar cephalic trim of cartilage creates an area of dead space that, with scar contracture, rotates

the tip upward to a more favorable position. The surgeon should be careful to preserve at least 8 mm of lateral crural width to ensure structural integrity of the lower lateral cartilage. Overresection of the lateral crura may result in weakened cartilages that are predisposed to buckling with scar contracture, leading to bossae formation.

The scroll is the region of overlapping attachment of the caudal border of the upper lateral cartilage to the cephalic border of the lower lateral cartilage. Overdevelopment of the scroll region can also contribute to tip ptosis. In younger patients, conservative resection of the scroll can effectively shorten the length of the lateral

crura (lateral tripod limbs) and consequently aid in rotating a ptotic tip. However, in the aging nose, an overdeveloped scroll region is not usually encountered. Conversely, as mentioned previously, the unfurling and separation of the cartilages in the scroll region is more characteristic of the aging nose.

At the conclusion of the case, the nasal cavity is often packed as part of the normal course of many surgeons' rhinoplasty technique. Although rarely a concern in young and healthy patients, bilateral nasal packing should be undertaken cautiously in elderly patients or in those with multiple, especially pulmonary comorbidities as blood oxygenation may be compromised.<sup>5</sup>



**Figure 4** Preoperative and 1-year postoperative photos of three patients who underwent open septorhinoplasty that included correction of tip underprojection and underrotation in each case.



## CONCLUSION

The nasal surgeon has at his or her disposal several proven methods for managing the aging nose. A method of repair should be chosen based on the desires and needs of the patient and the anatomy of the nose in question. The challenge presented to the nasal surgeon by aging nose rhinoplasty is to integrate a keen appreciation for nasal aesthetics and function with an intimate knowledge of tip anatomy and dynamics and to develop the surgical skill to apply a variety of techniques as needed to achieve a desired result.

Figure 4 demonstrates preoperative and 1-year postoperative photos of three patients who underwent open septorhinoplasty that included correction of tip underprojection and underrotation.

## REFERENCES

- Centers for Disease Control and Prevention (CDC). Trends in aging—United States and worldwide. *MMWR Morb Mortal Wkly Rep* 2003;52:101–104, 106
- Rohrich RJ, Hollier LH Jr, Janis JE, Kim J. Rhinoplasty with advancing age. *Plast Reconstr Surg* 2004;114:1936–1944
- Cochran CS, Ducic Y, DeFatta RJ. Restorative rhinoplasty in the aging patient. *Laryngoscope* 2007;117:803–807
- Stupak HD, Johnson CM Jr. Rhinoplasty for the aging nose. *Ear Nose Throat J* 2006;85:154–155
- Toriumi DM. Surgical correction of the aging nose. *Facial Plast Surg* 1996;12:205–214
- Daniel RK. The nasal tip: anatomy and aesthetics. *Plast Reconstr Surg* 1992;89:216–224
- Romo T III, Soliemanzadeh P, Litner JA, Sclafani AP. Rhinoplasty in the aging nose. *Facial Plast Surg* 2003;19:309–315
- Krmpotić-Nemanić J, Kostović I, Rudan P, Nemanić G. Morphological and histological changes responsible for the droop of the nasal tip in advanced age. *Acta Otolaryngol* 1971;71:278–281
- Kridel RWH, Scott BA, Foda HM. The tongue-in-groove technique in septorhinoplasty. A 10-year experience. *Arch Facial Plast Surg* 1999;1:246–256; discussion 257–258
- Toriumi DM. Rhinoplasty. In: Park SS, Day TA, Farrior EH, et al, eds. *Facial Plastic Surgery: The Essential Guide*. New York, NY: Thieme Medical Publishers; 2005:223–253
- Simons RL. Nasal tip projection, ptosis, and supratip thickening. *Ear Nose Throat J* 1982;61:452–455
- Johnson CM Jr, Toriumi DM. *Open Structure Rhinoplasty*. Philadelphia, PA: WB Saunders; 1990
- Beaty MM, Dyer WK II, Shawl MWW. The quantification of surgical changes in nasal tip support. *Arch Facial Plast Surg* 2002;4:82–91
- Foda HMT, Kridel RWH. Lateral crural steal and lateral crural overlay: an objective evaluation. *Arch Otolaryngol Head Neck Surg* 1999;125:1365–1370
- Kridel RWH, Konior RJ, Shumrick KA, Wright WK. Advances in nasal tip surgery. The lateral crural steal. *Arch Otolaryngol Head Neck Surg* 1989;115:1206–1212
- Pastorek N, Ham J. The underprojecting nasal tip: an endonasal approach. *Facial Plast Surg Clin North Am* 2004;12:93–106