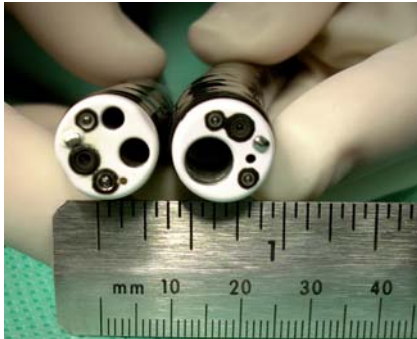

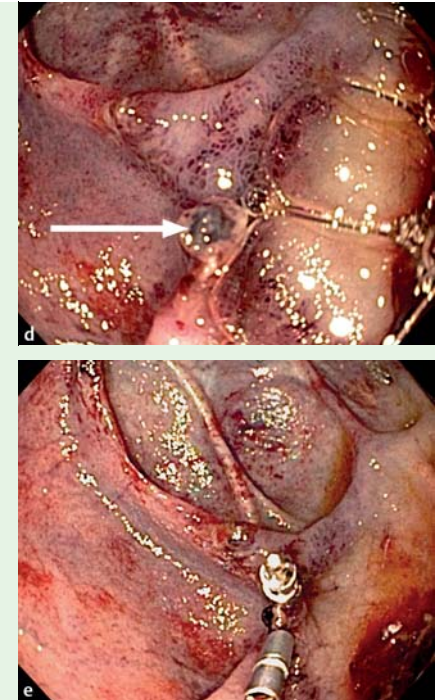
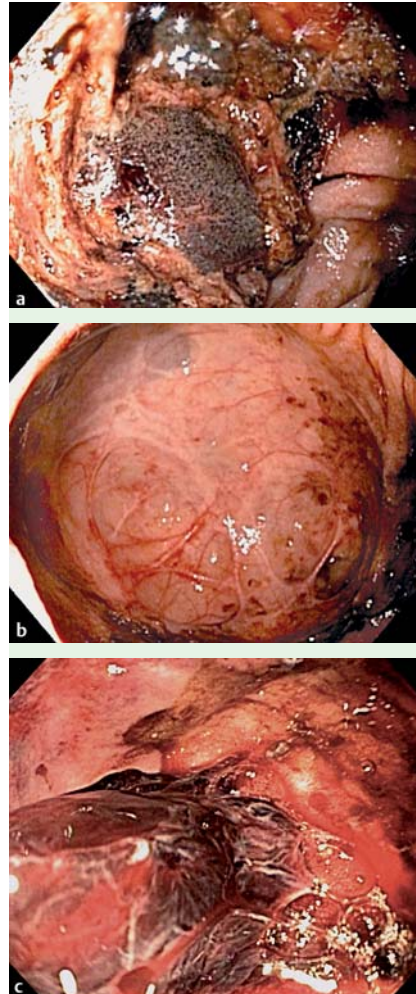
## Identification and treatment of a duodenal diverticular hemorrhage: an illustration of the usefulness of the jumbo-channel therapeutic endoscope



**Fig. 1** Note the difference between the 2.8- and 3.7-mm working channels of a conventional therapeutic endoscope (left) and the 6-mm channel of the jumbo therapeutic endoscope (right).

Hemorrhage from small-bowel diverticula is rare and requires a high degree of clinical suspicion and an adequate endoscopic view for the diagnosis [1,2]. Effective endoscopic therapy in this setting, as with most types of upper gastrointestinal bleeding, requires first that the lesion be adequately identified. Unfortunately, blood clot and particulate matter frequently obscure the field of view and prevent identification and treatment of the bleeding source. Conventional upper endoscopes with 2.8- and 3.7-mm working channels are often underpowered to effectively suction and clear blood clots and retained food material. Although repositioning of the patient, use of large-bore lavage tubes, and second look endoscopy after erythromycin infusion are useful adjunctive measures, endoscopically directed clearing of the field with simultaneous viewing would be ideal [3,4]. Recently, a “jumbo-channel” gastroscope (GIF-XTQ160, Olympus Corporation, Tokyo, Japan) has become widely available and boasts a 6-mm working channel for increased effectiveness in evacuating blood clots and debris (▶ Fig. 1).

Here we present a patient with an overt duodenal diverticular hemorrhage that was effectively identified and treated with the jumbo-channel gastroscope after a conventional therapeutic scope failed to clear the field.



**Fig. 2** **a** Field of view within the duodenum obstructed by clots and food debris. **b** Large duodenal diverticulum apparent after lavage and suction using the jumbo-channel therapeutic endoscope, with adherent clot (**c**) noted at the 6 o'clock position. **d** Removal of the clot reveals a vessel (arrow), which can now be easily isolated and repaired with hemoclips (**e**).

An 88-year-old woman presented to our institution with acute hematemesis and weakness. She underwent upper endoscopy using a double-channel therapeutic gastroscope (GIF 2T160, Olympus). Fresh and old blood were found throughout the upper gastrointestinal tract, with the medial segment of D2 markedly abnormal with adherent food debris (▶ Fig. 2a).

The initial impression was that of an ampullary malignancy; however, the blood clots and debris could not be cleared despite multiple attempts of flushing, suctioning, and the use of a polypectomy snare (Sensation, US Endoscopy, Mentor, Ohio, USA). The jumbo-channel gastro-

scope was then introduced and used to apply high-volume lavage followed by suction. This procedure quickly revealed an enormous duodenal diverticulum (▶ Fig. 2b), with an adherent clot at the 6 o'clock position (▶ Fig. 2c). The clot was suctioned out, revealing a prominent visible vessel (▶ Fig. 2d), which was injected with dilute epinephrine and treated with two hemoclips (Resolution, Boston Scientific, Natick, Massachusetts, USA) (▶ Fig. 2e). The patient recovered well without further bleeding episodes and was discharged 5 days later. Although hemorrhaging from duodenal diverticula is rare and has historically been treated with surgery, it can be effec-

tively treated endoscopically, as demonstrated in this case, provided that the lesion can first be seen [4]. Given the frequency that effective endoscopic treatment of acute upper gastrointestinal bleeding is complicated by blood clots and/or debris obscuring the source of bleeding and inhibiting treatment, the jumbo-channel therapeutic endoscope may represent an important step forward in the management of acute upper gastrointestinal bleeding. It is important not to overinterpret the results of this single case demonstration; however, it should be noted that the prototype of this scope was compared with conventional therapeutic endoscopes in a clinical trial by Kodali et al. and found to be superior in terms of aspirating blood, clots, and solid debris. It was also shown to be successful in clearing the stomach in 78% of patients in whom a conventional therapeutic endoscope was ineffective [5].

Endoscopy\_UCTN\_Code\_TTT\_1AO\_2AD

### M. T. Moyer, D. M. Bethards

Division of Gastroenterology and Hepatology, Penn State Hershey Medical Center, Hershey, Pennsylvania, USA

### References

- 1 Yin WY, Chen HT, Huang SM et al. Clinical analysis and literature review of massive duodenal diverticular bleeding. *World J Surg* 2001; 25: 848–855
- 2 Leivonen MK, Halttunen JA, Kivilaakso EO. Duodenal diverticulum at endoscopic retrograde cholangiopancreatography: analysis of 123 patients. *Hepatogastroenterology* 1996; 43: 961
- 3 Kwan V, Norton I. Endoscopic management of non-variceal upper gastrointestinal haemorrhage. *A J Surg* 2007; 77: 222–230
- 4 De astro LM, Herno JA, Pineda JR et al. Acute bleeding and anemia associated with intraluminal duodenal diverticulum: case report and review. *Gastrointest Endosc* 2003; 57: 976–979
- 5 Kodali VP, Peterson BT, Miller CA et al. A new jumbo-channel therapeutic gastroscope for acute upper gastrointestinal bleeding. *Gastrointest Endosc* 1997; 45: 409–415

### Bibliography

DOI 10.1055/s-0029-1215157  
Endoscopy 2009; 41: E230–E231  
© Georg Thieme Verlag KG Stuttgart · New York ·  
ISSN 0013-726X

### Corresponding author

#### M. T. Moyer, MD

Division of Gastroenterology and Hepatology  
Penn State Hershey Medical Center  
Hershey  
Pennsylvania 17033  
USA  
Fax: +1-717-531-6770  
mmoyer@psu.edu