Use of the light-emitting diode-illuminated endoscope for upper gastrointestinal endoscopy

We have developed the white light-emitting diode (LED)-illuminated endoscopes and previously reported our preliminary experiments with the prototype LED endoscope in the beagle [1]. Authors in *Nature* noted that the white LEDs we employed have been used for illuminating paintings in fine art museums, as they emit white light with good color rendering and homogeneous light distribution [2,3]. This supports the notion that these LEDs may also be suitable for use in gastrointestinal endoscopes, as these instruments must be able to indicate subtle changes in the color and mucosal structure of the gastrointestinal tract.

The prototype LED endoscopes were based on conventional endoscopes for studies in humans (Fujifilm Corporation, Saitama, Japan), and white LEDs were mounted on their tip (**Fig. 1**).

After obtaining Institutional Review Board approval, a patient with an early gastric carcinoma underwent endoscopy using this new endoscope.

We found that the white LEDs did not provide sufficient illumination for distant observation in the stomach. However, our prototype LED endoscope allowed clear visualization of the early gastric cancer by close observation. The LED endoscope showed a flat lesion, which was located at the anterior wall of the mid-gastric body and had ill-defined margins accompanied by slightly reddish or focally pale mucosa (**Fig. 2a**).

Indigo carmine chromoendoscopy emphasized the redness of the lesion and delineated the demarcation between the cancerous and non-cancerous mucosa (**Fig. 2b**). These findings corresponded to those from an examination with a conventional endoscope (**Fig. 2c, d**). We then subjected the lesion to endoscopic submucosal dissection using a conventional endoscope. Pathological evaluation of the excised tissue revealed that the lesion was an intramucosal differentiated adenocarcinoma and that both its lateral and vertical margins were free of carcinoma cells (**Fig. 3a, b**).

In conclusion, our observations show that our prototype LED-illuminated endoscope can clearly visualize early gastric cancers upon close observation.



Fig. 1 The prototype light-emitting diode (LED) endoscope. Two packages of white LEDs and a charge-coupled device (CCD) were attached to the distal end of the prototype LED endoscope.

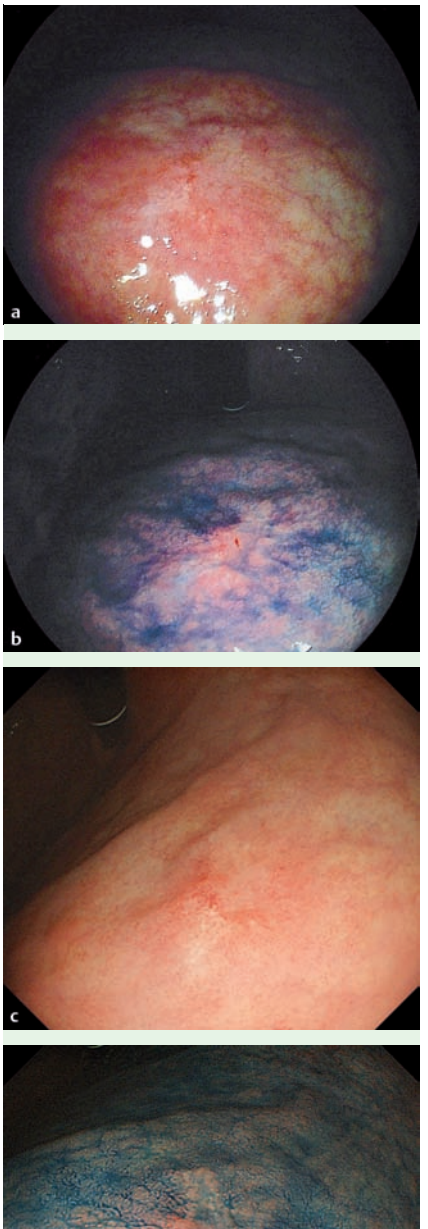

Fig. 2 An image of a superficially depressed-type early gastric carcinoma that was obtained using the LED endoscope and a conventional endoscope: **a** White LED endoscopic view; **b** view with indigo carmine dye. **c** Conventional endoscopic view; **d** view with indigo carmine dye.

Endoscopy_UCTN_Code_TTT_1AO_2AN

S. Kiyotoki[1], J. Nishikawa[1], H. Yanai[2], T. Okamoto[1], S. Higaki[1], T. Taguchi[3], I. Sakaida[1]

[1] Department of Gastroenterology and Hepatology, Yamaguchi University Graduate School of Medicine, Yamaguchi, Japan

[2] Department of Clinical Research, National Hospital Organization Kanmon Medical Center, Shimonoseki, Japan

[3] Luminescent Quantum Semiconductors Laboratory, Graduate School of Science and Engineering, Yamaguchi University, Yamaguchi, Japan

This document was downloaded for personal use only. Unauthorized distribution is strictly prohibited.

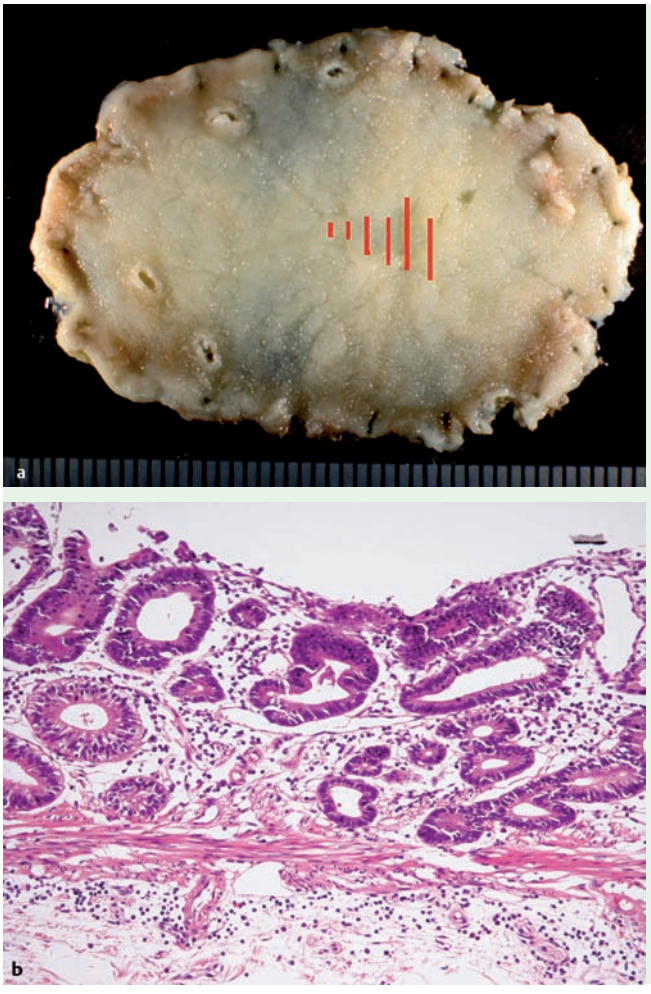

Fig. 3 **a** Macroscopic view of the resected specimen. The red lines indicate the carcinoma area. **b** Pathological analysis of the resected tissue revealed a well-differentiated adenocarcinoma in the mucosal layer (× 200).

References

1 *Yanai H, Okita K, Kikuchi K et al.* Preliminary experience with a gastrointestinal endoscope using a white light-emitting diode. Endoscopy 2006; 38: 290 – 291

2 *Sakuta H, Fukui T, Miyachi T et al.* Near-ultraviolet LED of the external quantum efficiency over 45 % and its application to high-color rendering phosphor conversion white LEDs. J Light Vis Env 2008; 32: 39 – 42

3 *Venema L.* The art of illumination. Nature 2007; 450: 1175

Bibliography

DOI 10.1055/s-0029-1214779
Endoscopy 2009; 41: E173 – E174

© Georg Thieme Verlag KG Stuttgart · New York ·

ISSN 0013-726X

Corresponding author

J. Nishikawa, MD, PhD
Department of Gastroenterology and Hepatology
Yamaguchi University Graduate
School of Medicine
Minamikogushi 1-1-1
Ube
Yamaguchi
Japan
755-8505
Fax: +81-836-22-2240
junnis @yamaguchi-u.ac.jp

This document was downloaded for personal use only. Unauthorized distribution is strictly prohibited.