

Unexplained melena associated with a history of endovascular stent grafting of abdominal aortic aneurysms: aortoduodenal fistula

Aortoduodenal fistulas (ADFs) are rare but potentially lethal causes of massive gastrointestinal tract bleeding. Here, we report the typical endoscopic findings of ADFs.

A 57-year-old man was admitted to our hospital with intermittent melena for 2 weeks. His medical history included implantation of a prosthetic graft for an abdominal aortic aneurysm at the age of 56 years. Hemoglobin level decreased from 14.5 g/dL in the previous month to 11.2 g/dL, and esophagogastroduodenoscopy (EGD) revealed no source of bleeding up to the second part of the duodenum. On day 3, melena recurred and hemoglobin level further decreased to 9.3 g/dL. Contrast-enhanced computed tomography (CT) scan showed a protruding aorta compressing the third part of the duodenum (● Fig. 1); EGD at this site revealed a raised lesion covered by an apparently normal mucosa with a central ulcer (● Fig. 2). Operative findings revealed fistula formation between the aorta – at 1.5 cm from the cranial margin of the graft – and the third part of the duodenum. Gastrojejunostomy with graft replacement was performed.

ADFs are classified as either primary or secondary. Incidences of secondary ADFs after endovascular stent grafting of abdominal aortic aneurysms have been reported to be about 1%. The duodenum, particularly its third part, is the most common site of fistula formation. Clinical manifestations include gastrointestinal bleeding, abdominal pain, and development of a pulsatile mass. Endoscopic features include a submucosal tumor with a small ulcer [1–4]. Diagnosis is difficult as endoscopists do not focus on a history of aortic aneurysm repair or consider the third part of the duodenum in patients with unexplained gastrointestinal bleeding.

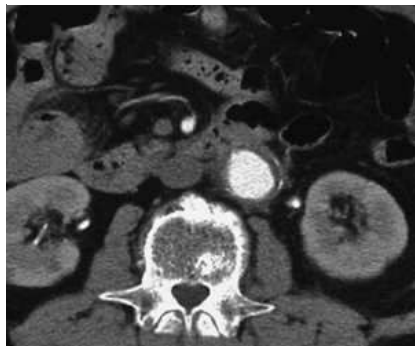


Fig. 1 Computed tomogram, showing a protruding aorta compressing the third portion of the duodenum.

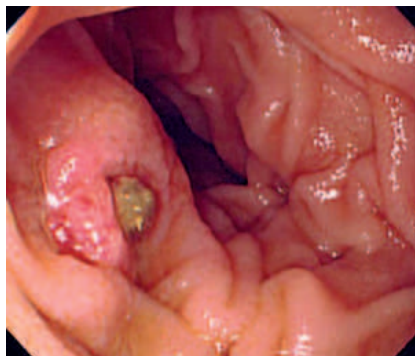

Fig. 2 Endoscopic image, showing a raised lesion covered by normal mucosa with a central ulcer.

Endoscopy_UCTN_Code_CCL_1AB_2AZ_3AD

**Y. Sukawa¹, A. Goto¹, H. Okuda²,
K. Suzuki¹, Y. Hasegawa¹, K. Yonezawa¹,
T. Abe¹, Y. Shinomura²**

¹ Department of Gastroenterology and Rheumatology, Kushiro City General Hospital, Kushiro City, Japan

² First Department of Internal Medicine, Sapporo Medical University, Sapporo, Japan

References

- 1 Katsinelos P, Paroutoglou G, Papaziogas B et al. Secondary aortoduodenal fistula with a fatal outcome: report of six cases. *Surg Today* 2005; 35: 677–681
- 2 Okano A, Takakuwa H, Matsubayashi Y. Aortoduodenal fistula resembling a submucosal tumor due to penetration of abdominal aortic aneurysm. *Intern Med* 2005; 44: 904
- 3 Geraci G, Pisello F, LiVolsi F et al. Secondary aortoduodenal fistula. *World J Gastroenterol* 2008; 14: 484–486
- 4 Saratzis N, Saratzis A, Melas N et al. Aortoduodenal fistulas after endovascular stent-graft repair of abdominal aortic aneurysms: single-center experience and review of the literature. *J Endovasc Ther* 2008; 15: 441–448

Bibliography

DOI 10.1055/s-0029-1214484

Endoscopy 2009; 41: E84

© Georg Thieme Verlag KG Stuttgart · New York · ISSN 0013-726X

Corresponding author

A. Goto, MD

Department of Gastroenterology and Rheumatology

Kushiro City General Hospital

1-12, Shunkodai

Kushiro city

085-0822

Japan

Fax: +81-0154-414080

kh8939@kushiro-cgph.jp