

# Efficacy and safety of H-APC in Barrett's esophagus: Italian prospective multicenter study



## Authors

Daive Massimi<sup>1</sup>, Roberta Maselli<sup>2,1</sup>, Silvia Pecere<sup>3</sup>, Cristiano Spada<sup>3</sup>, Gianluca Andrisani<sup>4</sup>, Francesco Maria Di Matteo<sup>4</sup>, Antonella La Terra<sup>5</sup>, Franco Coppola<sup>5</sup>, Antonio Capogreco<sup>1</sup>, Roberto De Sire<sup>1</sup>, Ludovico Alfarone<sup>1</sup>, Maddalena Menini<sup>1</sup>, Marco Spadaccini<sup>1</sup>, Cesare Hassan<sup>2,1</sup>, Alessandro Repici<sup>2,1</sup>

## Institutions

- 1 Digestive Endoscopy Unit, Department of Gastroenterology, IRCCS Humanitas Research Hospital, Rozzano, Italy
- 2 Department of Biomedical Sciences, Humanitas University, Pieve Emanuele, Italy
- 3 Digestive Endoscopy Unit, Fondazione Policlinico Universitario Agostino Gemelli IRCCS, Roma, Italy
- 4 Digestive Endoscopy Unit, Campus Bio-Medico University Hospital, Roma, Italy
- 5 Endoscopy Unit, Ospedale San Giovanni Bosco, Torino, Italy

## Key words

Endoscopy Upper GI Tract, RFA and ablative methods, Barrett's and adenocarcinoma, Reflux disease

received 9.10.2024

accepted after revision 16.12.2024

accepted manuscript online 3.2.2025

## Bibliography

Endosc Int Open 2025; 13: a25318227

DOI 10.1055/a-2531-8227

ISSN 2364-3722

© 2025. The Author(s).

This is an open access article published by Thieme under the terms of the Creative Commons Attribution-NonDerivative-NonCommercial License, permitting copying and reproduction so long as the original work is given appropriate credit. Contents may not be used for commercial purposes, or adapted, remixed, transformed or built upon. (<https://creativecommons.org/licenses/by-nc-nd/4.0/>)

Georg Thieme Verlag KG, Oswald-Hesse-Straße 50, 70469 Stuttgart, Germany

## Corresponding author

Dr. Roberta Maselli, Humanitas University, Department of Biomedical Sciences, Pieve Emanuele, Italy  
roberta.maselli@humanitas.it

Supplementary Material is available at  
<https://doi.org/10.1055/a-2531-8227>

## ABSTRACT

**Background and study aims** Hybrid argon plasma coagulation (H-APC) is a novel technique for ablation of neoplastic Barrett's esophagus (BE), consisting in submucosal fluid injection and subsequent APC of visible BE. The aim of this study was to assess H-APC efficacy, safety, and tolerability.

**Patients and methods** We prospectively included patients undergoing H-APC ablation at four Italian Hospitals from September 2022 to March 2024. Patients with BE C3M5 maximum extent, low- or high-grade dysplasia (LGD, HGD) or residual BE after endoscopic resection (ER) of visible lesions were included. Patients who had undergone previous ablative treatments were excluded. The primary endpoints were complete eradication of intestinal metaplasia (CE-IM) and dysplasia (CE-D). Secondary endpoints were safety in terms of major and minor adverse events (AEs) and tolerability, assessed using pain (0–10) and dysphagia (0–5) scores within 7 days post-ablation (NCT05645679).

**Results** Among the 51 enrolled patients (mean circumferential 0.43 cm; standard deviation [SD] 0.72, mean maximum longitudinal 2.20 cm; SD 1.09) who completed treatment (80 H-APC sessions), 45.1% (23/51) had prior ER of visible lesions. All patients achieved both CE-IM and CE-D (51/51), requiring a mean of 1.51 sessions (SD 0.83). Only one case of fever and absolute dysphagia was observed (1/51; 1.96% AEs). Regarding tolerability, mean pain score was 1.3 (SD 1.99) whereas mean dysphagia score was 1.28 (SD 0.56).

**Conclusions** The H-APC technique showed promising results in terms of effectiveness and safety with good tolerability in achieving initial CE-IM and CE-D in a selected population of BE patients.

## Introduction

Barrett's esophagus (BE) is an established risk factor for esophageal adenocarcinoma (EAC), a malignant condition with an increasing incidence and a 5-year survival rate of 5 to 20%. As a matter of fact, patients with low-grade (LGD) and high-grade (HGD) BE-associated dysplasia have an annual risk of progressing to EAC of 0.5% and 7%, respectively [1, 2].

Radiofrequency ablation (RFA) is the reference standard among endoscopic ablative treatments for dysplastic BE [3]. RFA has been shown to completely eradicate intestinal metaplasia up to 94% of cases [4, 5, 6, 7]. Despite convincing and corroborated outcomes in term of efficacy, the not negligible rate of adverse events (AEs) as high as 19.1% is considered a major drawback of the procedure. In particular, risk of thermal muscular injury has been shown to be difficult to prevent, translating in a 0.6% rate of perforation intra-procedurally, and a risk of post-procedure esophageal strictures requiring endoscopic dilations reported in 5.6% to 11.8% of cases [8].

Hybrid argon plasma coagulation (H-APC) is a new technique consisting of submucosal fluid injection and subsequent ablation through APC. Injection of solutions into the submucosa is aimed at limiting depth of thermal muscular injury, preventing both risk of perforations and strictures, possibly achieving more effective ablation of metaplastic/dysplastic mucosa [9, 10, 11, 12, 13, 14].

The specific aim of this study was to evaluate efficacy of this technique in completely eradicating intestinal metaplasia (CE-IM) and dysplasia (CE-D), maintaining a particular focus of procedure safety and tolerability.

## Patients and methods

We conducted a multicenter, prospective, single-arm study at four Italian hospitals. The study protocol was approved by the Institutional Review Board (IRB) of the coordinating center (Humanitas Research Hospital) and at each participating center. The study was registered on clinicaltrials.gov (NCT05645679) and reported according to the STROBE checklist. Site investigators and their research teams collected, reviewed, and entered the data into an electronic database maintained by the coordinating center. All authors had access to the study data and reviewed and approved the final manuscript.

Sample size was calculated based on the number of patients with BE managed annually at participating centers. Assuming an average of at least five new cases of untreated dysplastic BE per year across the four Italian referral centers and accounting for a possible dropout rate of up to 20%, we estimated a required sample size of 50 patients.

### Study population

Patients with BE 1 to 5 cm in length (Prague Classification  $\leq$  C3/ $\leq$  M5), and histologically confirmed low-grade (LGD) or high-grade dysplasia (HGD) or residual BE after endoscopic resection of visible lesions (LGD, HGD, or early esophageal adenocarcinoma  $\leq$  T1sm1) were eligible.

We excluded patients younger than 18 years of age. Other exclusion criteria included prior distal esophagectomy, previous ablation therapy of the esophagus, history of esophageal varices, or achalasia, active esophagitis grade B or higher (patients could be included after appropriate treatment of reflux esophagitis), esophageal stricture preventing advancement of the endoscope, anti-thrombotic therapy precluding endoscopy, uncontrolled coagulopathy, severe comorbidities, or life expectancy  $\leq$  2 years, as judged by the site investigator, pregnancy or planning to become pregnant during period of study participation.

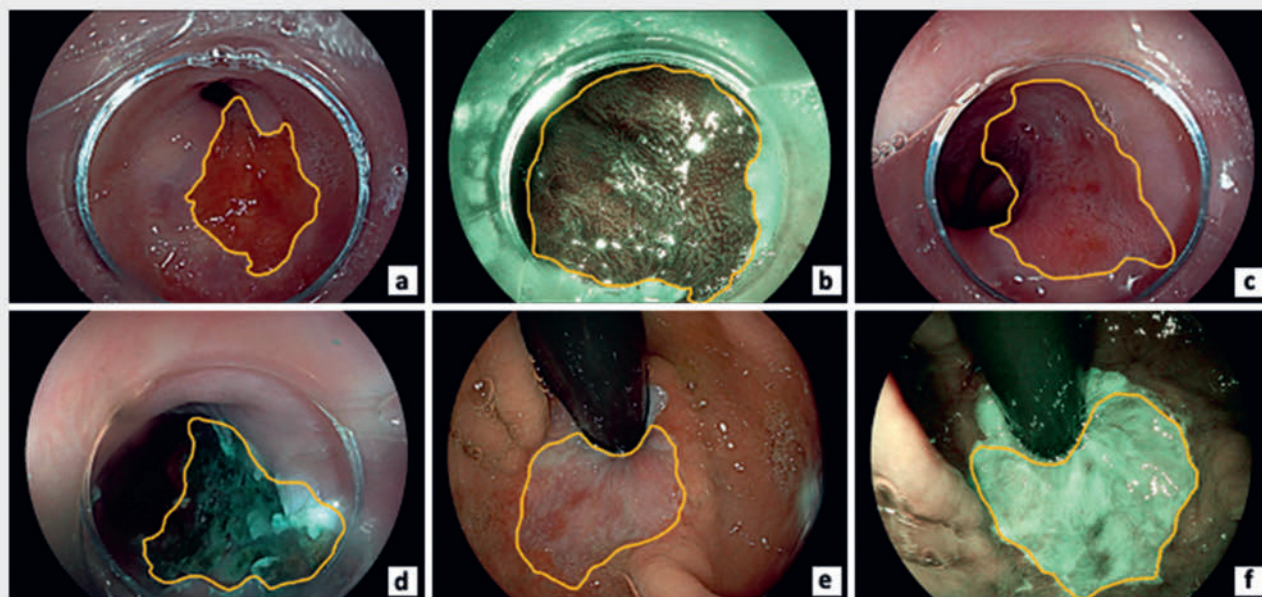
### Endoscopic procedure and follow-up endoscopy

All participating centers were trained by the study Principal Investigator and the device manufacturer (Erbe Elektromedizin GmbH [Erbe USA]) on the study protocol, data collection, and use of the Hybrid APC system. The H-APC probe combines WaterJet technology with APC. The probe comprises a central water channel for submucosa injection and a peripheral gas channel for APC. The rest of the technical characteristics of H-APC system are presented in the **Supplementary Material**. All the procedures were performed with a VIO3 Erbe Electrosurgical unit. Maximum extension per treatment session was limited to the hemi circumference to prevent stenosis formation.

Upper endoscopy procedures were performed on an inpatient/outpatient basis according to site standard of care for procedure sedation or anesthesia. Baseline examination required high-definition white light endoscopy and digital mucosal enhancement (narrow band imaging, Olympus America, Center Valley, Pennsylvania, United States; or I-Scan, Pentax Medical Corporation; blue light imaging BLI, Fujifilm) to assess baseline characteristics of BE. At initial examination, ablation was performed when there were no concerning lesions or nodularity. The treatment area could be marked or not at the discretion of each endoscopist using the APC catheter at Pulsed 25 or 30 W. Submucosal injection was performed using saline mixed with methylene blue; the starting setting for the water jet system was Effect 25–30. This setting could be increased in increments of 5 until the desired lift was obtained. After lifting, ablation was performed with pulsed APC at 60 W with an argon flow rate of 0.8 to 1.0 L/min all over the BE epithelium until a tan-brown chamois appearance of the tissue was achieved. Even in cases of circumferential BE, max 50% of the circumference was allowed by protocol. After H-APC treatment, the ablated tissue was removed using a transparent endoscopy cap followed by additional H-APC treatment for eventual small residual areas of BE. The setting for supplemental treatment was 40 W.

Within 7 days ( $\pm$  2 days), patients were contacted by the local investigator or a physician via phone call to administer tolerability questionnaires (**► Fig. 1** and **Supplementary Material**).

Endoscopic procedures were repeated every  $8 \pm 2$  weeks till complete eradication of visible intestinal metaplasia. During follow-up upper endoscopy, the neo-epithelium was closely examined using high-definition white light endoscopy and virtual chromoendoscopy. Random biopsies were performed on the entire length of the neo-epithelium at the 4 quadrants and at the esophagogastric junction and targeted biopsies are taken



► **Fig. 1** Hybrid-APC ablation process. **a** White light endoscopy (HD-WLI) images at baseline examination. **b** Blue light imaging (BLI) at baseline endoscopy. **c** HD-WLI at baseline examination after acetic acid spray. **d** Results of Hybrid-Argon plasma coagulation aimed at completely eradicating dysplastic and metaplastic mucosa. **e** Esophageal neo-epithelium after treatment with WLI. **f** Esophageal neo-epithelium after treatment with BLI.

of suspicious residual BE to histologically confirm achievement of CE-IM and CE-D.

Immediately after treatment, patients were prescribed high-dose proton pump inhibitor therapy twice daily, equivalent to at least, pantoprazole 40 mg bid. Additional acid-inhibiting medication could be prescribed at investigator discretion.

### Study endpoints

Rates of CE-IM and CE-D were the main outcomes. CE-IM was defined as complete eradication of all BE on endoscopy and in all biopsies obtained at first follow-up endoscopy after the maximum of five treatment sessions. Similarly, CE-D was defined as complete eradication of dysplasia in all biopsies obtained at first follow-up endoscopy.

The rate of major and minor AEs were secondary outcomes as well as patient tolerability, number of Hybrid APC treatments required to achieve CE-IM and CE-D, and duration of each treatment session. Procedure time (minutes) was calculated as time between the first submucosal injection and ablation of the last area of BE. Gastrointestinal bleeding was defined as a bleeding with a significant drop in hemoglobin values ( $Hb > 2\text{g/dL}$ ) or requiring transfusion within 24 hours of the procedure. Perforation was defined as exposure of the mediastinal/peritoneal space as a result of a muscular defect occurring during the procedure.

Besides bleeding and perforation, major AEs included fever persisting for more than 24 hours that developed during the first 24 hours after the procedure. Minor AEs comprised pain, dysphagia, gastrointestinal bleeding without need for blood transfusion or a drop in hemoglobin ( $Hb < 2\text{g/dL}$ ), and fever

lasting less than 24 hours that developed during the first 24 hours after the procedure. Finally, tolerability was defined as presence of post-procedure pain (rated on a scale of 0 to 10, where 0 indicates no pain and 10 signifies the worst imaginable pain) and dysphagia (also rated on a scale of 0 to 5, where 0 indicates absence of dysphagia and 5 indicates inability to swallow liquids and solids). Moreover, patients were questioned about their postoperative experience, including painkiller usage and visits to their general practitioner.

### Statistical analysis

Descriptive statistical analysis was conducted on the available data. For normally distributed variables, means with standard deviations (SDs) were calculated, whereas variables with skewed distributions were presented as medians with interquartile ranges (IQRs). Categorical variables were expressed as frequencies and percentages.

Univariate/multivariate analysis was used to assess the association between different variables (length of BE and circumferential involvement, worst BE histology, previous endoscopic treatment with endoscopic mucosal resection [EMR]/endoscopic submucosal dissection [ESD] prior to H-APC ablation), and efficacy (CE-D, CE-IM, number of ablative procedures) and safety outcomes (AEs). All statistical analyses were performed with STATA (ver. 18, Texas, United States).

## Results

### Population characteristics

From September 2022 to March 2024, 51 patients (82.3% males, mean age 61.1 years) were enrolled, all of whom completed the treatment protocol. Baseline characteristics of the patients and BE are shown in ► **Table 1**.

Overall, 45.1% (23/51) had previously undergone endoscopic resection—either EMR, ESD, or both—of visible lesions before ablative treatment sessions. Among this subgroup, 43.5% were diagnosed with adenocarcinoma, 43.5% had HGD, and 13% had LGD. Among those who proceeded directly to ablation, 75% had LGD and 25% had HGD.

There were no screening failures according to protocol inclusion/exclusion criteria (**Supplementary material**). In the baseline population, circumferential BE was present in 13% (3/23) of previously resected and 46% (13/28) of non-resected patients

(► **Fig. 2**). Reported BE lengths, including mean circumferential (C) and maximum (M) longitudinal, were calculated based on residual segments after endoscopic resection.

### Feasibility and effectiveness

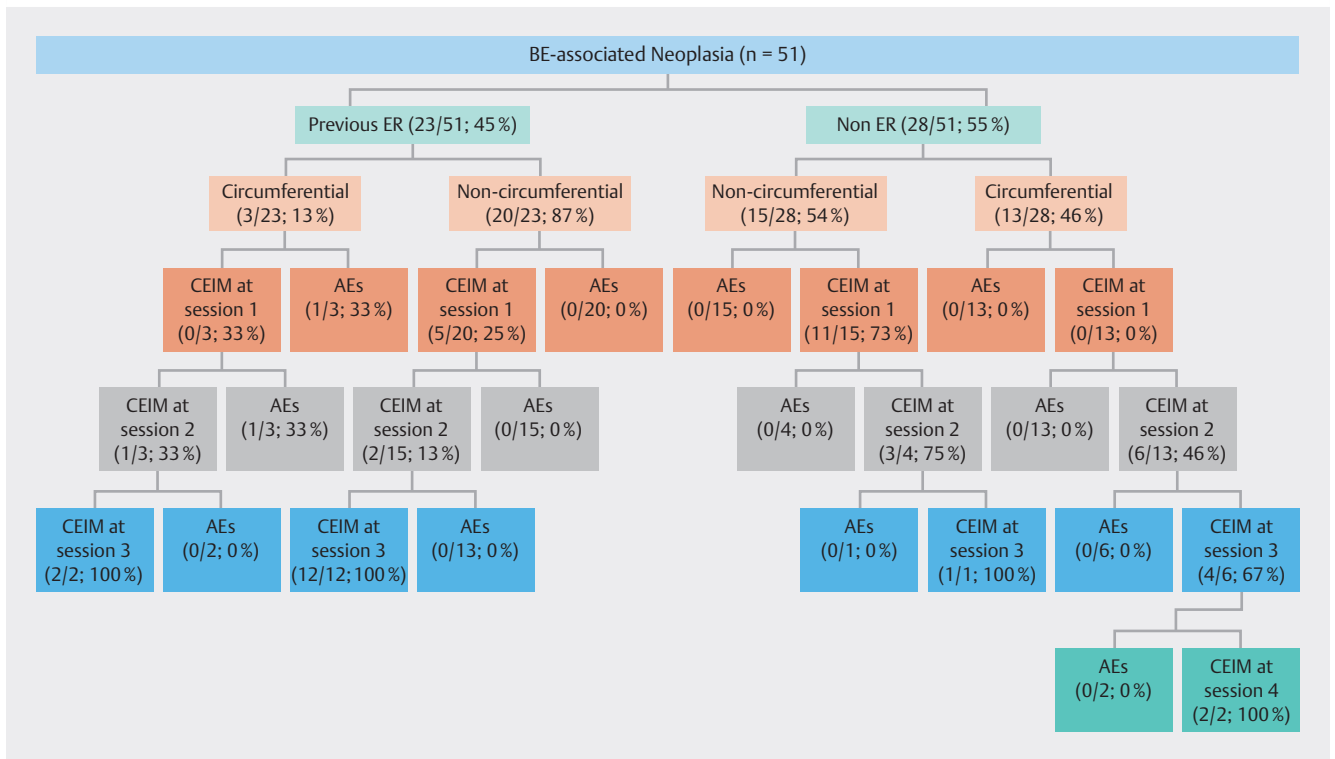
In all 51 patients, H-APC was technically feasible with a mean procedure time of 22.2 minutes (SD 11.3) (► **Fig. 3**). In all patients, eradication of dysplasia (CE-D) and intestinal metaplasia (CE-IM) were successful. The median number of treatments required to achieve complete eradication of intestinal metaplasia (CE-IM) was 1.0 (range 1 to 4; IQR 1.0 to 2.0).

All patients reached successful eradication of dysplasia (CE-D) and intestinal metaplasia (CE-IM). Mean number of ablation sessions required to achieve eradication was 1.51 (SD 0.83). Need for multiple sessions was independently associated with circumferential BE involvement ( $P = 0.0091$ ) and longitudinal BE extension of more than 2 cm ( $P = 0.0059$ ). In contrast, nei-

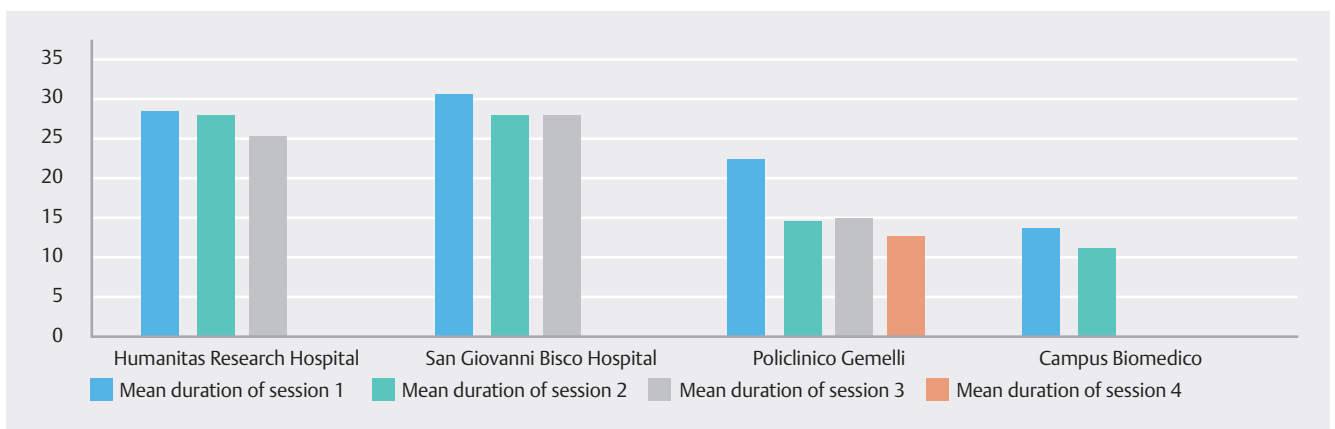
► **Table 1** Study population.

|  | Number | Percentage      |
|--|--------|-----------------|
| Enrolled patients                                | 51     | 100%            |
| Number of patients who completed treatment       | 51     | 100%            |
| Females:males                                    | 9:42   | 17.7%:82.3%     |
| Mean age   | 61.1   | Range 36–85     |
| Mean BMI   | 26.86  | Range 18.7–38.1 |
| Mean BE C length (cm)                            | 0.43   | Range 0–3.0     |
| Mean BE M length (cm)                            | 2.20   | Range 1.0–5.0   |
| Number of patients undergoing ER before ablation | 23/51  | 45.1%           |
| Technique of ER                                  |        |                 |
| ▪ Only EMR                                       | 10/23  | 43.5%           |
| ▪ Only ESD                                       | 12/23  | 52.2%           |
| ▪ EMR plus ESD                                   | 1/23   | 4.3%            |
| Worst histology from ER                          |        |                 |
| ▪ Low-grade dysplasia                            | 3/23   | 13%             |
| ▪ High-grade dysplasia                           | 10/23  | 43.5%           |
| ▪ Adenocarcinoma                                 | 10/23  | 43.5%           |
| Worst histology in the remaining BE              |        |                 |
| ▪ Intestinal metaplasia                          | 3/23   | 13%             |
| ▪ Low-grade dysplasia                            | 10/23  | 43.5%           |
| ▪ High-grade dysplasia                           | 10/23  | 43.5%           |
| ▪ Number undergoing direct Hybrid-APC            | 28/51  | 54.9%           |
| Worst histology in direct Hybrid-APC             |        |                 |
| ▪ LGD  | 21/28  | 75%             |
| ▪ HGD  | 7/28   | 25%             |

APC, argon plasma coagulation; BE, Barrett's esophagus; BMI, body mass index; C, circumference; EMR, endoscopic mucosal resection; ER, endoscopic resection; ESD, endoscopic submucosal dissection; HGD, high-grade dysplasia; M, maximum; LGD, low-grade dysplasia.



► **Fig. 2** Treatment flowchart. ER, endoscopic resection; CEIM, complete eradication of intestinal metaplasia.



► **Fig. 3** Average treatment duration (minutes). Mean treatment duration of four sessions at four involved centers (Humanitas Research Hospital, San Giovanni Bosco Hospital, Policlinico Gemelli, Campus Biomedico).

ther previous endoscopic treatment nor presence of adenocarcinoma as a worse histology were found to be factors associated with need for more ablative treatment (► **Table 2**).

### Safety and tolerability

None of the 80 procedures caused any major AEs. One patient experienced intense post-procedure pain associated with fever lasting less than 24 hours and total dysphagia that was conservatively managed (C2M3, ablated with pulsed APC at 60W for 25 minutes). No strictures, bleeding, or other AEs were reported.

No patients required endoscopic dilations during or after the treatment course and patients were reassessed within 7 days ( $\pm$  2 days) after each treatment and between treatments without evidence of any concern about dysphagia. The mean pain score was 1.3 (SD 1.99). Fourteen of 80 ablations required post-operative painkillers within 72 hours, all of which were paracetamol. Mean dysphagia score was 1.28 (SD 0.56). Two of 80 ablation sessions (2.5%) affected normal daily activities of patients during the following days. Univariate analysis did not identify any factors predictive of safety and tolerability outcomes (► **Table 3**).

► **Table 2** Univariate and multivariate analysis.

| ≥ 1 ablation session              | Univariate |          |         | Multivariate |          |         |
|-----------------------------------|------------|----------|---------|--------------|----------|---------|
|                                   | OR         | CI       | P value | OR           | CI       | P value |
| Longitudinal extension (M ≥ 2)    | 7.7        | 2.2–27.8 | 0.00017 | 3.4          | 1.4–11.3 | 0.0059  |
| Circumferential extension (C ≥ 1) | 4.8        | 1.6–14.8 | 0.0058  | 4.0          | 1.5–13.9 | 0.0091  |
| Previous endoscopic resection     | 2.3        | 0.7–8.1  | 0.1851  | –            | –        | –       |
| Adenocarcinoma at worst histology | 0.8        | 0.2–3.7  | 0.249   | –            | –        | –       |

C, circumference; CI, confidence interval; M, maximum; OR, odds ratio.

► **Table 3** Mean treatment duration and mean pain/dysphagia score.

| Session number | Mean duration (SD) in minutes | Mean pain score (SD) from 1 to 10 | Mean dysphagia score (SD) from 1 to 5 |
|----------------|-------------------------------|-----------------------------------|---------------------------------------|
| 1              | 23.2 (10.5)                   | 1.6 (2.2)                         | 1.3 (0.6)                             |
| 2              | 21.3 (12.9)                   | 0.7 (1.2)                         | 1.3 (0.5)                             |
| 3              | 24.0 (7.7)                    | 0.8 (1.3)                         | 1.3 (0.5)                             |
| 4              | 12.5 (3.5)                    | 0.0 (0.0)                         | 0.5 (0.7)                             |

SD, standard deviation.

## Discussion

This study represents the first multicenter Italian experience with Hybrid-APC (H-APC), conducted across four referral centers specializing in BE and advanced third-space endoscopy. Its primary objective was to evaluate real-world feasibility, safety, and efficacy of H-APC, focusing on complete eradication of intestinal metaplasia (CE-IM) and dysplasia (CE-D), assessing AEs (particularly strictures), and examining patient-reported outcomes such as pain and dysphagia. The study's rigorous inclusion criteria—excluding patients with prior ablative therapies and including those with previous extensive endoscopic resections—underscore its relevance to real-world clinical practice, particularly in high-risk cases characterized by a higher likelihood of post-procedure stenosis, scar tissue, and fibrosis. All patients achieved CE-IM and CE-D without any major AEs reported, except one case of post-procedure pain associated with fever (< 24 h), which was conservatively managed.

Risk of AEs, particularly perforation and stenosis, has indeed historically conditioned ablative therapy of BE. Moreover, pain and dysphagia reported by patients after RFA ablation sessions have raised concerns about tolerability of the procedure [15, 16, 17, 18]. Hybrid-APC was conceived for this purpose: to reduce risk of deep muscle injury without compromising treatment effectiveness. This technique was designed to achieve CE-IM with only one device, by lifting the submucosa with a needle-free high-pressure water jet, preventing muscle injury

and damage to deep submucosal vessels during argon plasma ablation [11, 19].

This study confirms the aim for which the H-APC was developed, achieving high ablative efficacy and eliminating potential AEs.

A prior investigation on the H-APC technique by Knabe et al. indicated similar promise regarding a more favorable outcome in terms of AEs and patient tolerability with hybrid-APC compared with RFA, the current standard for BE ablation, without affecting efficacy. According to that trial, eradication rates for RFA versus H-APC were 74.2% versus 82.9%, respectively. Strictures necessitating further treatment were observed in 3.7% of H-APC patients compared with 14.9% in the RFA group. In addition, a more favorable tolerability profile was reported, as reflected by lower mean pain scores (4.56/10 over 7.54 days for RFA versus 2.07/10 over 3.59 days for hybrid-APC) [20].

To confirm these results, our study relied on meticulous tracking of the tolerance profile of the technique through accurate phone recordings of patient symptoms conducted weekly following each treatment session. Hybrid APC was very well tolerated by patients, 91.8% of whom did not change their daily activities following the first ablation session and the mean pain and dysphagia scores after the first ablation session were 1.7 and 1.4, respectively. Although patient-reported outcomes were meticulously tracked, lack of validation for these questionnaires limits generalizability of the tolerability findings.

The efficacy confirmation relied on meticulous biopsy protocol extended to the full length of the neo-epithelium, and all biopsies were assessed by expert pathologists.

One limitation of our study could be the limited circumferential extension of BE in the enrolled patients and the protocol design, which limited treatment to hemi-circumference. This could explain the low number of sessions required to achieve CE-IM and a lower stricture rate than previous studies enrolling patients with longer BE [21, 22, 23]. Indeed, the need for multiple sessions was independently associated with circumferential BE involvement ( $P = 0.0091$ ) and longitudinal BE extension of more than 2 cm ( $P = 0.0059$ ). As previously stated, this is due, in part, to the protocol design, which limited maximum extension per treatment session to the hemi-circumference to prevent stenosis formation.

Noteworthy, neither previous endoscopic treatment nor presence of adenocarcinoma as a worse histology were found

to be factors associated with need for more ablative treatment. Moreover, considering that the mean circumferential extension of the treated patients was 0.43 cm (range 0–3 cm) and mean longitudinal extension was 2.20 cm (range 1–5 cm), mean procedure time was 22.2 minutes (SD 11.3), reflecting even in this case the protocol limitation to half-circumferential ablation and the relatively short BE segments treated. Although the technique demonstrated reproducibility across tertiary centers, a learning curve is expected, as with all ablation modalities. It is unclear whether H-APC, in general, may require more endoscopic expertise than RFA. Considering previous RFA experience, endoscopist experience correlates with successful BE eradication [24]. A learning curve must be assumed, as with all ablation techniques, but given the procedure time and efficacy endpoints in our study, it appears that the technique may be highly reproducible in tertiary referral centers, where these patients should be addressed. In these respects, multicenter studies such as the present study, with multiple examiners, may be more representative than single-center trials with one or a few dedicated and highly experienced endoscopists, which may represent an underexamined study bias. Given its safety profile and efficacy, H-APC appears particularly suitable for patients at high risk of recurrence or stricture formation, especially those who require targeted treatment. Limited circumferential extension of BE in the enrolled patients was offset by the substantial number of patients enrolled who underwent multiple endoscopic resections (EMR and ESD) before ablation, many of whom had adenocarcinomas. In fact, the ability to modulate injection power made it possible to achieve adequate BE lift and effective and safe ablation in every case, even overcoming the potential limitation of submucosal fibrosis due to previous endoscopic resection. In this respect, Hybrid-APC could be a beneficial choice for ablating BE in patients at high risk of recurrence and strictures following endoscopic treatments, with shortened BE extension. This technique seems to be the ideal option for a targeted and highly effective treatment.

The lack of follow-up data, particularly the recurrence rate, represents the main limitation of our study. Although the study was designed to evaluate immediate outcomes, we plan to conduct follow-up analyses once a complete dataset is available. In the future, it will be essential to assess whether the rate of initial CE-IM and CE-D is confirmed at follow-up in terms of sustained CE-IM and CE-D, as well as oncological reliability of this new technique to prevent and avoid esophageal adenocarcinoma.

## Conclusions

The findings from our investigation appear highly encouraging. They indicate notable efficacy and safety, a promising tolerability profile, and a reduced number of treatment sessions needed to attain initial CE-D and CE-IM even after previous endoscopic resection. Moreover, there is substantial consistency across various centers and among endoscopists with varying expertise levels. However, conclusive evidence should be derived from extensive multicenter randomized trials directly comparing

hybrid-APC and RFA, the current standard of care, in a real-life multicenter environment.

## Conflict of Interest

The authors declare that they have no conflict of interest.

## Clinical trial

ClinicalTrials.gov (<http://www.clinicaltrials.gov/>)  
Registration number (trial ID): NCT05645679  
Type of Study: Prospective Multi Center Study

## References

- [1] Singh S, Manickam P, Amin AV et al. Incidence of esophageal adenocarcinoma in Barrett's esophagus with low-grade dysplasia: a systematic review and meta-analysis. *Gastrointest Endosc* 2014; 79: 897–909.e4
- [2] Rastogi A, Puli S, El-Serag HB et al. Incidence of esophageal adenocarcinoma in patients with Barrett's esophagus and high-grade dysplasia: a meta-analysis. *Gastrointest Endosc* 2008; 67: 394–398
- [3] Herrero LA, van Vilsteren FGI, Pouw RE et al. Endoscopic radiofrequency ablation combined with endoscopic resection for early neoplasia in Barrett's esophagus longer than 10 cm. *Gastrointest Endosc* 2011; 73: 682–690
- [4] Orman ES, Li N, Shaheen NJ. Efficacy and durability of radiofrequency ablation for Barrett's esophagus: Systematic review and meta-analysis. *Clin Gastroenterol Hepatol* 2013; 11: 1245–1255 doi:10.1016/j.cgh.2013.03.039
- [5] Phoa KN, Pouw RE, van Vilsteren FGI et al. Remission of Barrett's esophagus with early neoplasia 5 years after radiofrequency ablation with endoscopic resection: A Netherlands cohort study. *Gastroenterology* 2013; 145: 96–104
- [6] Shaheen NJ, Sharma P, Overholt BF et al. Radiofrequency ablation in Barrett's esophagus with dysplasia. *N Engl J Med* 2009; 360: 223–224
- [7] Van Vilsteren FGI, Pouw RE, Seewald S et al. Stepwise radical endoscopic resection versus radiofrequency ablation for Barrett's oesophagus with high-grade dysplasia or early cancer: a multicentre randomised trial. *Gut* 2011; 60: 765–773
- [8] Phoa KN, van Vilsteren FGI, Weusten BLAM et al. Radiofrequency ablation vs endoscopic surveillance for patients with Barrett esophagus and low-grade dysplasia. *JAMA* 2014; 311: 1209
- [9] Yahagi N, Neuhaus H, Schumacher B et al. Comparison of standard endoscopic submucosal dissection (ESD) versus an optimized ESD technique for the colon: an animal study. *Endoscopy* 2009; 41: 340–345 doi:10.1055/s-0029-1214473
- [10] Sold MG, Grobholz R, Post S et al. Submucosal cushioning with water jet before endoscopic mucosal resection: Which fluids are effective? *Surg Endosc* 2008; 22: 443–447
- [11] Norton ID, Wang L, Levine SA et al. In vivo characterization of colonic thermal injury caused by argon plasma coagulation. *Gastrointest Endosc* 2002; 55: 631–636 doi:10.1067/mge.2002.123418
- [12] Neuhaus H, Wirths K, Schenk M et al. Randomized controlled study of EMR versus endoscopic submucosal dissection with a water-jet hybrid-knife of esophageal lesions in a porcine model. *Gastrointest Endosc* 2009; 70: 112–120

- [13] Kaehler GFBA, Sold MG, Fischer K et al. Selective fluid cushion in the submucosal layer by water jet: advantage for endoscopic mucosal resection. *Eur Surg Res* 2007; 39: 93–97
- [14] Johans W, Luis W, Janssen J et al. Argon plasma coagulation (APC) in gastroenterology: experimental and clinical experiences. *Eur J Gastroenterol Hepatol* 1997; 9: 581–587 doi:10.1097/00042737-199706000-00006
- [15] Schulz H, Miehke S, Antos D et al. Ablation of Barrett's epithelium by endoscopic argon plasma coagulation in combination with high-dose omeprazole. *Gastrointest Endosc* 2000; 51: 659–663
- [16] Gupta M, Iyer PG, Lutzke L et al. Recurrence of esophageal intestinal metaplasia after endoscopic mucosal resection and radiofrequency ablation of Barrett's esophagus: results from a US Multicenter Consortium. *Gastroenterology* 2013; 145: 79–86.e1
- [17] Pasricha S, Bulsiewicz WJ, Hathorn KE et al. Durability and predictors of successful radiofrequency ablation for Barrett's esophagus. *Clin Gastroenterol Hepatol* 2014; 12: 1840–1847.e1
- [18] Manner H, Rabenstein T, Pech O et al. Ablation of residual Barrett's epithelium after endoscopic resection: a randomized long-term follow-up study of argon plasma coagulation vs. surveillance (APE study). *Endoscopy* 2014; 46: 6–12 doi:10.1055/s-0033-1358813
- [19] Manner H, Neugebauer A, Scharpf M et al. The tissue effect of argon-plasma coagulation with prior submucosal injection (Hybrid-APC) versus standard APC: A randomized ex-vivo study. *United European Gastroenterol J* 2014; 2: 383–390
- [20] Knabe M, Wetzka J, Welsch L et al. Radiofrequency ablation versus hybrid argon plasma coagulation in Barrett's esophagus: a prospective randomised trial. *Surg Endosc* 2023; 37: 7803–7811 doi:10.1007/s00464-023-10313-5
- [21] Manner H, May A, Kouti I et al. Efficacy and safety of Hybrid-APC for the ablation of Barrett's esophagus. *Surg Endosc* 2016; 30: 1364–1370 doi:10.1007/s00464-015-4741-5
- [22] Shimizu T, Samarasena JB, Fortinsky KJ et al. Benefit, tolerance, and safety of hybrid argon plasma coagulation for treatment of Barrett's esophagus: US pilot study. *Endosc Int Open* 2021; 09: E1870–E1876 doi:10.1055/a-1492-2450
- [23] Knabe M, Beyna T, Rösch T et al. Hybrid APC in combination with resection for the endoscopic treatment of neoplastic Barrett's esophagus: A prospective, multicenter study. *Am J Gastroenterol* 2022; 117: 110–119
- [24] Fudman DI, Lightdale CJ, Poneris JM et al. Positive correlation between endoscopist radiofrequency ablation volume and response rates in Barrett's esophagus. *Gastrointest Endosc* 2014; 80: 71–77