

# Efficacy and safety of conservative treatment for colonic diverticular bleeding: Prospective study



## Authors

Hirosato Doi<sup>1</sup>, Masanori Takahashi<sup>1</sup>, Keita Sasajima<sup>1</sup>, Takehiro Yoshii<sup>1</sup>, Ryo Chinzei<sup>1</sup>

## Institutions

1 Digestive Internal Medicine, Saitama Red Cross Hospital, Saitama, Japan

## Key words

Endoscopy Lower GI Tract, Lower GI bleeding, Diagnosis and imaging (inc chromoendoscopy, NBI, iSCAN, FICE, CLE...)

received 26.9.2024

accepted after revision 16.12.2024

accepted manuscript online 2.1.2025

## Bibliography

Endosc Int Open 2025; 13: a25097426

DOI 10.1055/a-2509-7426

ISSN 2364-3722

© 2025. The Author(s).

This is an open access article published by Thieme under the terms of the Creative Commons Attribution-NonDerivative-NonCommercial License, permitting copying and reproduction so long as the original work is given appropriate credit. Contents may not be used for commercial purposes, or adapted, remixed, transformed or built upon. (<https://creativecommons.org/licenses/by-nc-nd/4.0/>)

Georg Thieme Verlag KG, Oswald-Hesse-Straße 50, 70469 Stuttgart, Germany

## Corresponding author

Dr. Hirosato Doi, Saitama Red Cross Hospital, Digestive Internal Medicine, 1-5 Shintoshin, 330-8553 Saitama, Japan  
[creamy1106@yahoo.co.jp](mailto:creamy1106@yahoo.co.jp)

## ABSTRACT

**Background and study aims** This prospective study aimed to establish the efficacy and safety of conservative treatment for non-severe cases of colonic diverticular bleeding and to verify whether early colonoscopy is necessary only in limited cases.

**Patients and methods** Patients who were urgently hospitalized due to hematochezia and were diagnosed with colonic diverticular bleeding were included. During hospitalization, early colonoscopy within 24 hours after admission was performed only when both systolic blood pressure < 90 mm Hg and extravasation on contrast-enhanced computed tomography were observed. However, in patients who failed to recover from hemorrhagic shock, interventional radiology was performed. In other cases, patients received conservative treatment.

**Results** Of the 172 patients, 15 (8.7%) met the criteria for undergoing early colonoscopy; 12 and three attained successful hemostasis via early colonoscopy and interventional radiology, respectively. Meanwhile, 157 patients received conservative treatment, resulting in spontaneous hemostasis in 148 patients (94.3%). The remaining nine patients required hemostatic intervention. No patient died from bleeding. Between the conservative treatment and the urgent hemostasis groups, the early rebleeding rate within 30 days (14.6% vs. 33.3%,  $P = 0.0733$ ) and the overall 1-year cumulative rebleeding rate after 30 days of hospitalization (9.2% vs. 23.1%,  $P = 0.2271$ ) were not significant. In multivariate analyses, only systolic blood pressure and extravasation were associated with a requirement for hemostatic intervention in 24 patients. Moreover, multivariate analyses showed that a history of diverticular bleeding, undergoing hemodialysis, or use of oral thienopyridine were significantly associated with late rebleeding.

**Conclusions** Conservative treatment for non-severe colonic diverticular bleeding is appropriate and efficient.

## Introduction

Colonic diverticular bleeding is the most common cause of lower gastrointestinal bleeding, accounting for more than one-fourth of total cases [1, 2], and has been increasing along with

an elevated number of patients with colonic diverticula and taking antithrombotic drugs [3]. Colonic diverticular bleeding generally stops spontaneously in 87% to 96% of patients [4, 5, 6]. Japanese guidelines for colonic diverticular bleeding advocate early colonoscopy within 24 hours of a hospital visit to

identify the stigma of recent hemorrhage (SRH) [7], which is considered an indicator of a bleeding point. However, recent studies on the effectiveness of early colonoscopy have not reported improved outcomes regarding rebleeding rate and length of hospital stay [8,9]. However, some severe cases require hemostatic intervention, and detecting such cases is important. In addition, the effectiveness of hemostatic methods, such as endoscopic band ligation (EBL), over-the-scope clip (OTSC), and endoscopic detachable snare ligation [10, 11, 12], and new techniques, such as the underwater method, gel immersion endoscopy, and traction devices, have been reported [13, 14, 15]; however, the SRH identification rate is initially low, ranging from 15% to 42% even when early colonoscopy is performed [7, 8, 16, 17, 18, 19].

Considering the high rate of spontaneous hemostasis of diverticular bleeding, SRH may spontaneously regress during conservative treatment, except in some cases. Based on these hypotheses, we developed a treatment strategy for diverticular bleeding. In cases with both low systolic blood pressure, which could be regarded as an indicator of hemodynamic instability, and extravasation on contrast-enhanced computed tomography (CECT), which would indicate the site of active bleeding, early colonoscopy was performed. In the other cases, conservative treatment with fasting and fluid administration was administered. We previously conducted a retrospective study using this treatment strategy, and spontaneous hemostasis was achieved in all patients in the conservative treatment group [20]. Based on this background, the present prospective study aimed to establish the efficacy and safety of conservative treatment for non-severe cases of colonic diverticular bleeding and to verify that early colonoscopy is necessary only in limited cases.

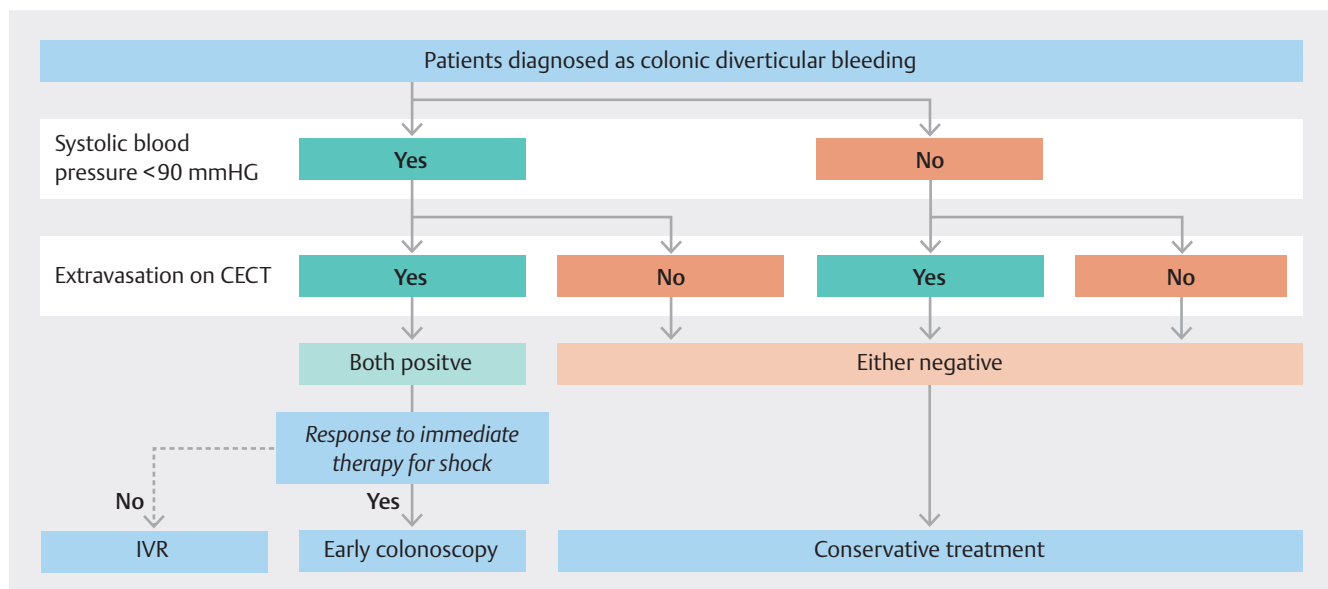
## Patients and methods

### Patients

Consecutive outpatients with bloody stools between January 2017 and December 2023 were eligible for inclusion. Inclusion criteria were as follows: 1) urgent hospitalization due to hematochezia and 2) colonic diverticulum observed on CECT or previous colonoscopy. Exclusion criteria were as follows: 1) colonoscopy was not performed within 7 days of hospitalization; 2) total colonoscopy was not possible; 3) CECT was not performed due to allergy to contrast media or severe renal dysfunction (estimated glomerular filtration rate  $< 30 \text{ mL/min/1.73 m}^2$ ), and 4) other bleeding sources were identified. Presumptive diverticular bleeding was diagnosed when spontaneous hemostasis was achieved without hemostatic intervention and no source of bleeding other than diverticular bleeding was found on colonoscopy or other examinations [7, 8]. This study was approved by the institutional Ethics Review Board at our hospital. All patients provided informed consent regarding the risks and benefits of their treatment depending on their physical condition. The trial was registered at UMIN-CTR (UMIN000028007).

### Flowchart of treatment strategy

Treatment options are shown in ► Fig. 1. In all cases during hospital visits, procedures such as infusion first were performed to stabilize the patient's general condition. All patients underwent CECT to assess extravasation within the bowel lumen. Only when both low systolic pressure ( $< 90 \text{ mm Hg}$ ) and extravasation were observed was early colonoscopy performed within 24 hours. When SRH was identified, endoscopic hemostasis was performed using a clipping method or an OTSC. Conversely, if SRH was not observed because of spontaneous he-



► Fig. 1 In cases with both systolic pressure  $< 90 \text{ mmHg}$  and extravasation on contrast-enhanced computed tomography, early colonoscopy within 24 h after admission was performed. However, in patients who failed to recover from hemorrhagic shock, interventional radiology was performed. In other cases, conservative treatment with fasting and fluid administration was administered. IVR, interventional radiology; CECT, contrast-enhanced computed tomography

mostasis, follow-up observation without colonoscopy was performed. In cases in which patients could not recover from shock or when endoscopic hemostasis was challenging, interventional radiology (IVR) was performed to achieve hemostasis by arterial embolization. Otherwise, if a patient's vital signs were stable during the hospital visit or extravasation was not detected on CECT, conservative treatment with fasting and fluid resuscitation without early colonoscopy was administered. An elective colonoscopy was performed within 1 week after spontaneous hemostasis. In addition, even if conservative treatment was chosen, if vital signs became unstable again after admission or if bleeding persisted for > 24 hours, a colonoscopy was performed as soon as possible.

Food intake was resumed for > 24 hours after disappearance of hematochezia, meals were gradually solidified each day, and patients were discharged with a regular diet. Regarding indications for blood transfusion, in principle, patients with a serum hemoglobin (Hb) level < 7 g/dL were considered for blood transfusion. However, in some patients with comorbidities or general conditions such as shock, blood transfusion was considered even if the Hb level was 9 g/dL. Antithrombotic drugs were generally continued when vital signs were stable but were discontinued in patients who were in shock and immediately resumed after hemostasis.

## Rebleeding

Rebleeding was defined as presence of fresh blood in the stool along with low blood pressure (systolic blood pressure drops > 20 mm Hg) or a decrease in Hb level  $\geq 2.0$  g/dL. Early and late rebleeding were defined as rebleeding within 30 days of hospitalization and after 30 days of hospitalization, resulting in a second hospitalization, respectively. Presence or absence of rebleeding was evaluated in all patients until April 2024 according to the following methods: 1) in the case of outpatients in our hospital, it was evaluated on the onset day or at a recent visit; and 2) in cases of patients who were not followed up in our hospital, it was evaluated by telephone call with a questionnaire survey, which provided a recent history of the presence or absence of hospitalization due to hematochezia.

## Colonoscopy

Colonoscopy was performed after preparation with 2 L of polyethylene glycol in all patients, whether early or elective. Carbon dioxide insufflation was used to reduce abdominal discomfort, except in patients with chronic obstructive pulmonary disease. PCF-Q260AZI (Olympus, Tokyo, Japan), which has a water jet system, was used for early colonoscopy with a cap attachment, and PCF-Q260AZI, CF-XZ1200AZI, or CF-H260AZI (Olympus, Tokyo, Japan) was used for elective colonoscopy.

If SRH was identified, hemostasis was performed using only the clipping method or OTSC. With regard to OTSC (OTSC 12/6 t, 2200 mm; Ovesco Endoscopy, Tübingen, Germany), we have been using it in our hospital since August 2019 and actively used it in cases that met the following criteria: 1) cases that were not difficult to insert because reinsertion was necessary; and 2) cases in which the bleeding point could be reliably identified because of its high cost. If possible, clips (HX-610–135;

Olympus, Tokyo, Japan) were placed directly on the visible vessel or stigmata. When direct placement was difficult because of the diverticular dome location, massive hemorrhage, or small diverticular orifice, indirect placement was performed using multiple clips in a zipper fashion [21].

## Interventional radiology

IVR was performed in the femoral artery using a 4F Shepherd hook catheter and a nonionic contrast medium was injected into the superior mesenteric artery (5 mL/s) and inferior mesenteric artery (3 mL/s) to identify bleeding sites. Once bleeding sites were identified, a microcatheter was carefully advanced to each and arterial embolization was performed using coils. Embolization was selectively performed whenever possible to minimize intestinal ischemia.

## Statistical analysis

Mean  $\pm$  standard deviation, median, or percentage was used for all data. Categorical data were compared using the chi-square test or Fisher's exact test, whereas continuous data were compared using the Wilcoxon rank-sum test. The relationship between the necessity for hemostatic intervention and background was examined using multivariate logistic regression analyses. The Kaplan-Meier method and log-rank test were used in the time-to-event analysis of patients with cumulative late bleeding and the Cox proportional hazard model was used to examine the factors affecting late bleeding. JMP (version 14; SAS Institute Inc., United States) was used for the statistical analysis, and  $P < 0.05$  was considered statistically significant.

## Results

### Patient characteristics

Of 248 patients who met the inclusion criteria, 76 patients were excluded due to failure to perform colonoscopy within 7 days in 38, incapability of cecal intubation in one, other sources of bleeding in 20 (angiodyplasia in six, upper gastrointestinal bleeding in four, small intestinal bleeding in two, ischemic colitis in two, tumor bleeding in two, rectal ulcer in two, and rectal varices in two), and difficulty using iodinated contrast medium in 17. Consequently, 172 patients were enrolled in this prospective study. Patient characteristics are shown in ► **Table 1**. Of the participants, there were 125 males and 47 females, with an average age of  $70.0 \pm 12.6$  years (range, 34–97). Diverticula were located on the right side in 51 patients, on the left side in 12, and bilaterally in 109. A total of 44 patients (25.6%) had a previous history of diverticular bleeding and antithrombotic drugs were administered to 59 patients (34.3%): single antiplatelet therapy in 39, anticoagulant therapy in 25, and dual antiplatelet therapy in 10. A total of 32 patients (18.6%) had a systolic blood pressure < 90 mm Hg on arrival and 42 patients (24.4%) showed extravasation on CECT.

### Treatment outcome of hemostasis

Treatment outcomes are presented in ► **Table 2** and ► **Table 3**. Of 172 patients, 157 (91.3%) received conservative treatment according to our strategy: 111 with neither of the two signs,

► **Table 1** Patient characteristics.

Patients (n = 172)	
Age (years, mean ± SD)	70.0 ± 12.6 (34–97)
Sex (male/female)	125/47
<b>Localization of diverticulum</b>	
▪ Right-sided	51 (29.7%)
▪ Left-sided	12 (7.0%)
▪ Bilateral	109 (63.3%)
<b>Previous history of diverticular bleeding</b>	44 (25.6%)
<b>Hypertension</b>	106 (61.6%)
<b>Diabetes</b>	22 (12.8%)
<b>Dyslipidemia</b>	36 (20.9%)
<b>Hemodialysis</b>	11 (6.4%)
<b>Chronic kidney disease</b>	39 (22.7%)
<b>Liver cirrhosis</b>	3 (1.7%)
<b>Medications</b>	
▪ <b>Antithrombotic drugs (total)</b>	59 (34.3%)
▪ <b>Aspirin</b>	28 (16.3%)
▪ <b>Thienopyridine derivative</b>	21 (12.2%)
▪ <b>Dual antiplatelet therapy</b>	10 (5.8%)
▪ <b>Anticoagulants</b>	25 (14.5%)
▪ <b>Nonsteroidal anti-inflammatory drugs</b>	14 (8.1%)
<b>Systolic Blood Pressure (mm Hg, mean ± SD)</b>	122.9 ± 31.1
▪ <b>Less than 90mmHg</b>	32 (18.6%)
<b>Heart rate (bpm, mean ± SD)</b>	88.4 ± 18.9
<b>Loss of consciousness</b>	16 (9.3%)
<b>Extravasation on CECT</b>	42 (24.4%)
CECT, contrast-enhanced computed tomography; SD, standard deviation.	

17 with only systolic blood pressure < 90 mm Hg, and 29 with only extravasation on CECT. Consequently, 148 patients (94.3%) experienced spontaneous hemostasis. The remaining nine patients received hemostatic interventions due to intermittent bleeding, resulting in endoscopic hemostasis in eight patients. However, one patient underwent elective surgery due to difficulty identifying SRH in the ascending colon via colonoscopy, despite repeated life-threatening rebleeding. Meanwhile, 15 patients met the criteria for early colonoscopy and 12 patients underwent endoscopic intervention, achieving successful initial hemostasis in all cases with SRH identification. The remaining three patients underwent IVR due to difficulty recovering from hemorrhagic shock. Bleeding sites were located in the right-sided colon in 14 cases and the left-sided colon in only one case. Although two of six patients with direct replacement and both two patients with zipper fashion experienced early rebleeding after initial endoscopic hemostasis, none of

the patients with OTSC suffered from rebleeding. All patients eventually achieved successful hemostasis and no patients died of hemorrhagic shock, although one patient who received conservative treatment, a 74-year-old woman on dialysis, died of sepsis from phlegmon of the lower extremities after achieving spontaneous hemostasis.

A total of 24 patients required hemostatic intervention, whereas 148 patients achieved spontaneous hemostasis. In the univariate analysis, as shown in ► **Table 4**, significant differences were observed between patients who required hemostatic intervention and those who achieved spontaneous hemostasis in terms of systolic blood pressure < 90 mm Hg (62.5% vs. 11.5%,  $P < 0.0001$ ), positive extravasation (58.3% vs. 18.9%  $P = 0.0001$ ), and patients on hemodialysis (16.7% vs. 4.7%,  $P = 0.0494$ ). Multivariable logistic analyses showed systolic blood pressure < 90 mm Hg (odds ratio [OR] 21.39,  $P < 0.0001$ , 95% confidence interval [CI] 6.83–66.99) and positive extravasation (OR 5.84,  $P = 0.0024$ , 95% CI 1.87–18.21) as significant relative factors for hemostatic intervention. Moreover, risk factors for patients in the conservative treatment group who required hemostatic intervention were examined, but no significant differences were found between patients with systolic blood pressure < 90 mm Hg (22.2% vs. 10.1%,  $P = 0.2523$ ) or positive extravasation (11.1% vs. 18.9%,  $P = 0.4556$ ), indicating that meeting either of these criteria would not be an indicator for early colonoscopy. No other significant associated factors were identified.

Hospitalization costs were lower in the conservative treatment group (\$2,068 ± 681) compared with the urgent hemostasis group (\$3,228 ± 2,992,  $P = 0.0101$ ), whereas median length of hospital stay did not differ between the two groups (8 days vs. 8 days,  $P = 0.0932$ ). In addition, there was no significant difference in the early rebleeding rate after hospitalization (14.6% vs. 33.3%,  $P = 0.0733$ ) and the overall 1-year cumulative late rebleeding rate (9.2% vs. 23.1%,  $P = 0.2271$ ) between the two groups.

### Factors related to early and late rebleeding

The early rebleeding rate within 30 days after hospitalization was 16.3% across all patients, with a 95% CI of 11.5% to 22.5%. No significant difference was observed between the conservative treatment group (14.6%) and the urgent hemostasis group (33.3%,  $P = 0.0733$ ). In addition, multivariate logistic analyses showed that no clinical backgrounds, except that all patients were male, significantly related to early rebleeding. Late rebleeding, occurring after 30 days of hospitalization, was observed in 32 patients (18.6%, 95% CI 13.5–25.1) during an observation period of 45.9 ± 22.7 months. The cumulative late rebleeding rate at 1, 3, and 5 years was 10.3%, 19.6% and 22.5%, respectively, with no significant difference between the two groups. Multivariable analyses using the Cox proportional hazard model, as shown in ► **Table 5**, identified a previous history of diverticular bleeding (hazard ratio [HR] 2.66, 95% CI 1.30–5.40,  $P = 0.0082$ ), hemodialysis (HR 4.40, 95% CI 1.57–10.66,  $P = 0.0070$ ), and oral administration of thienopyridine derivatives (HR 2.49, 95% CI 1.03–5.43,  $P = 0.0432$ ) as significantly related factors to late rebleeding.

► **Table 2** Study treatment outcomes.

	Total (n = 172)	Urgent hemostasis (n = 15)	Conservative treatment (n = 157)	P value
<b>Hemostatic intervention</b>	24 (14.0%)	15 (100%)	9 (5.7%)	< 0.0001
<b>Mortality</b>	1 (0.6%)	0 (0%)	1 (0.6%)*	0.9128
<b>Early rebleeding</b>	28 (16.3%)	5 (33.3%)	23 (14.6%)	0.0733
<b>Late rebleeding</b>	32 (18.6%)	4 (26.7%)	28 (17.8%)	0.2955
<b>Cumulative late rebleeding</b>				0.2271
▪ 1-year	10.3%	23.1%	9.2%	
▪ 3-year	19.6%	30.8%	18.5%	
▪ 5-year	22.5%	30.8%	21.7%	
<b>Blood transfusion</b>	75 (43.6%)	12 (80.0%)	63 (40.1%)	0.0032
▪ <b>Units of blood</b> (mean ± SD)	2.9 ± 4.8	8.5 ± 8.7	2.4 ± 3.9	0.0002
<b>Periods of fasting</b> (days, mean ± SD, median)	3.2 ± 1.5 (3)	3.1 ± 1.8 (3)	3.3 ± 1.5 (3)	0.6029
<b>Length of stay</b> (days, mean ± SD, median)	9.2 ± 6.8 (8)	13.9 ± 20.2 (8)	8.8 ± 3.5 (8)	0.0932
<b>Hospitalization costs</b> (USD, mean ± SD)	2190 ± 1124	3228 ± 2992	2068 ± 681	0.0101

SD, standard deviation; USD, United States dollar; one dollar was converted to 145 Japanese yen.

\*One patient died due to sepsis from phlegmon of the lower extremities after achieving spontaneous hemostasis.

► **Table 3** Treatment outcomes of hemostatic intervention.

		Rebleeding rate after initial hemostasis	Second hemostasis for rebleeding
<b>Urgent hemostasis group (n = 15)</b>			
<b>Clipping</b>	Direct placement (6)	33.3% (2)	Direct placement (1), OTSC (1)
	Zipper fashion (2)	100% (2)	OTSC (1), IVR (1)
<b>OTSC (4)</b>		0%	
<b>IVR (3)</b>		33.3% (1)	IVR (1)
<b>Conservative treatment group (n = 9)</b>			
<b>Clipping</b>	Direct placement (4)	0%	–
<b>OTSC (4)</b>		0%	–
<b>Elective surgery (1)</b>		0%	–
<b>Total (n = 29, including second hemostasis)</b>		Rebleeding rate after hemostasis	
<b>Clipping</b>	Direct placement (11)	18.2% (2)	
	Zipper fashion (2)	100% (2)	
<b>OTSC (10)</b>		0%	
<b>IVR (5)</b>		20.0% (1)	
<b>Elective surgery (1)</b>		0%	

IVR, interventional radiology; OTSC, over-the-scope clip.

## Discussion

Although early intervention for colonic diverticular bleeding has been extensively discussed, this is the first report of a prospective study using spontaneous hemostasis as the primary

endpoint. The rate of spontaneous hemostasis in the conservative treatment group in this study was 94.3%, which is consistent with results from our previous observational study [20]. Conversely, all patients in the urgent hemostasis group requir-

► **Table 4** Factors requiring hemostatic intervention.

	Requiring intervention (n = 24)	Spontaneous hemostasis (n = 148)	Univariate analysis	Multivariate analyses		
			P value	OR	95% CI	P value
Age (years, mean ± SD)	72.5 ± 10.7	69.6 ± 12.8	0.2830			
Sex (male)	21 (87.5%)	104 (70.3%)	0.0596			
Hypertension	18 (75.0%)	88 (59.5%)	0.1085			
Diabetes	5 (20.8%)	17 (11.5%)	0.1704			
Dyslipidemia	6 (25.0%)	30 (20.3%)	0.3848			
Hemodialysis	4 (16.7%)	7 (4.7%)	0.0494	1.15	0.19–6.86	.8767
Liver cirrhosis	0 (0%)	3 (2.0%)	0.6353			
<b>Medications</b>						
▪ Antithrombotic (total)	11 (45.8%)	48 (32.4%)	0.1468			
▪ Aspirin	7 (29.2%)	21 (14.2%)	0.0670			
▪ Thienopyridine	3 (12.5%)	18 (12.2%)	0.5899			
▪ Dual antiplatelet therapy	3 (12.5%)	7 (4.7%)	0.1478			
▪ Anticoagulants	5 (20.8%)	20 (13.5%)	0.2536			
▪ Nonsteroidal anti-inflammatory drugs	2 (8.3%)	12 (8.1%)	0.6115			
Systolic blood pressure < 90 (mm Hg)	15 (62.5%)	17 (11.5%)	<0.0001	21.39	6.83–66.99	<.0001
Heart rate (bpm, mean ± SD)	86.5 ± 23.9	88.7 ± 18.0	0.5884			
Loss of consciousness	5 (20.8%)	11 (7.4%)	0.0519			
Extravasation on CECT	14 (58.3%)	28 (18.9%)	0.0001	5.84	1.87–18.21	.0024
<b>Laboratory data</b>						
Hemoglobin level (g/dL, mean ± SD)	10.9 ± 3.0	11.0 ± 2.5	0.8984			
White blood cells count (×10 <sup>3</sup> /mm <sup>3</sup> , mean ± SD)	7.6 ± 2.3	7.7 ± 3.0	0.9286			
Platelet count (×10 <sup>4</sup> /mm <sup>3</sup> , mean ± SD)	20.6 ± 5.8	22.2 ± 9.2	0.4152			
UN/Cre ratio (mean ± SD)	19.6 ± 10.1	21.2 ± 8.0	0.3895			
Albumin level (g/dL, mean ± SD)	3.5 ± 0.5	3.7 ± 0.5	0.1388			
PT-INR (mean ± SD)	1.1 ± 0.2	1.0 ± 0.2	0.4272			

CECT, contrast-enhanced computed tomography; CI, confidence interval; OR, odds ratio; PT-INR, international normalized ratio of prothrombin time; SD, standard deviation; UN/Cre, urea nitrogen/creatinine.

ed hemostatic intervention, suggesting that this approach might be a useful strategy for identifying patients who need hemostatic intervention.

Even though recent studies about diverticular bleeding have been designed to perform early colonoscopy as soon as possible after hospital admission (e.g., within 24 hours) [8, 9], our hemostatic results were comparable to those studies. In most previous studies of endoscopic intervention, the primary endpoint was identification rate of SRH, and cases with identified SRH were considered eligible for treatment. However, the rate of identification of SRH varies from institution to institution, ranging from 15% to 47% [7, 8, 16, 17, 18, 19], and there is a relatively large discrepancy compared with spontaneous hemostasis

rates reported in the past [4, 5, 6]. This suggests that SRH might not always indicate the necessity for endoscopic hemostasis.

Because the colon is less exposed to digestive fluids than the upper gastrointestinal tract, hemostatic intervention is not required as often as it is for upper gastrointestinal bleeding. In addition, most diverticular bleeding, generally thought to be caused by a breakage in the vulnerable part of the vasa recta located deep within the diverticulum cave [22], is inherently difficult to identify. Moreover, SRH, which is considered an indication for endoscopic hemostasis, is defined as active bleeding, visible vessel, or adherent clot [7]. Although there is no dispute that the first two are indications that hemostatic intervention is

► **Table 5** Factors associated with cumulative late rebleeding.

	Univariate analysis			Multivariate analysis		
	HR	95% CI	P value	HR	95% CI	P value
<b>Male</b>	1.33	0.61–3.37	0.4969			
<b>Previous history of diverticular bleeding</b>	2.95	1.46–5.93	0.0013	2.66	1.30–5.40	0.0082
<b>Hypertension</b>	1.20	0.59–2.59	0.6177			
<b>Diabetes</b>	0.66	0.16–1.84	0.4807			
<b>Dyslipidemia</b>	0.75	0.25–1.79	0.5484			
<b>Hemodialysis</b>	4.51	1.68–10.26	0.0003	4.40	1.57–10.66	0.0070
<b>Medications</b>						
▪ <b>Antithrombotic (total)</b>	1.83	0.90–3.67	0.0831			
▪ <b>Aspirin</b>	1.45	0.58–3.18	0.3799			
▪ <b>Thienopyridine</b>	2.81	1.18–6.01	0.0079	2.49	1.03–5.43	0.0432
▪ <b>Dual antiplatelet therapy</b>	1.65	0.40–4.66	0.3999			
▪ <b>Anticoagulants</b>	1.74	0.70–3.83	0.1859			
▪ <b>Nonsteroidal anti-inflammation drugs</b>	0.31	0.02–1.46	0.0824			
<b>Systolic blood pressure &lt; 90 (mm Hg)</b>	1.83	0.80–3.82	0.1174			
<b>Loss of consciousness</b>	0.58	0.09–1.91	0.4451			
<b>Extravasation on contrast-enhanced CT</b>	2.10	1.01–4.25	0.0371	1.33	0.61–2.80	0.4587
<b>Urgent hemostasis group</b>	0.53	0.21–1.79	0.2271			
<b>Hemostatic intervention</b>	1.57	0.63–3.45	0.2140			

CI, confidence interval; CT, computed tomography; HR, hazard ratio.

necessary, the finding of adherent clot varies from observer to observer and, above all, represents a state of spontaneous hemostasis. Furthermore, presence of a clot does not necessarily indicate a bleeding site. In other words, the high rate of spontaneous hemostasis might imply that endoscopic hemostasis is not necessary for adherent clots. This might explain why several previous reports have shown that hemostatic intervention for SRH did not prevent early rebleeding [8, 23]. At least in this study, all patients in the early colonoscopy group were found to have active bleeding or visible vessels, suggesting that a no-treatment observational study should be used for adherent clots in the future.

Next, cases requiring hemostatic intervention in diverticular bleeding are those with persistent bleeding that cannot be expected to stop spontaneously, leading to circulatory instability. From this perspective, our strategy was to use CECT as an indicator of persistent bleeding and blood pressure at presentation as an indicator of hemodynamic instability as criteria for early colonoscopy, and to perform early colonoscopy only when both criteria are met. In other words, if only one of the criteria is met, hemostatic intervention is not considered necessary. For instance, if extravasation is observed on CECT, it indicates persistent bleeding at the time of imaging, but if blood pressure is stable, the bleeding is likely to be of a level that does not affect

hemodynamics. This is because CECT can detect blood flow as low as 0.5 mL/min [24], and if the bleeding does not affect circulation, there is a high possibility that it would stop spontaneously. Conversely, even in cases of temporary hemodynamic instability, absence of extravasation on CECT suggests that spontaneous hemostasis has already been achieved. In addition, hypotension may be due to vagal reflex and cannot necessarily be attributed to hypovolemic shock. Regarding the Shock Index, heart rates in elderly patients may not increase as much as in younger patients because they may be taking drugs that affect this, such as  $\beta$ -blockers and calcium channel blockers, or they may have decreased sensitivity to catecholamines. There are some reports indicating that the Shock Index is not a valid indicator for gastrointestinal bleeding in a high proportion of elderly patients [25]. Moreover, in our previous retrospective study, heart rate was not associated with urgent hemostasis. Therefore, we selected blood pressure as a simple and more sensitive indicator. Given the high rate of spontaneous hemostasis, this strategy appears appropriate; in fact, 94.3% of patients in the conservative treatment group achieved spontaneous hemostasis. Similar validation in a multicenter study is needed in the future.

There was no significant difference in early rebleeding rates between the conservative treatment group and the urgent he-

mostasis group. In the urgent hemostasis group, early rebleeding after endoscopic hemostasis occurred only after using clipping methods, and no patients rebled after OTSC. This suggests that early rebleeding might be preventable if the bleeding point is identified and a reliable hemostatic method is used. Various recent reports have shown the effectiveness of EBL, which is certainly an effective and less costly treatment [26, 27, 28]. However, there have been reports of delayed perforation in a very small number of cases [29, 30, 31]. In this regard, the efficacy and safety of OTSC have recently been reported [11, 32]. Although the cost of OTSC needs to be addressed, it is expected to become widely used as a safe hemostatic treatment device.

As with previous reports, this study did not find any benefit of early colonoscopy and endoscopic hemostasis in reducing the late rebleeding rate [33, 34]. Diverticular bleeding often occurs in patients with multiple colonic diverticula, making it difficult to identify the bleeding point. Late rebleeding may also occur even after successful endoscopic hemostasis, suggesting the possibility of bleeding from another diverticulum. Given these factors, preventing late rebleeding is currently challenging. With the increasing number of patients taking antithrombotic drugs and those on dialysis, the total number of diverticular bleeding cases is likely to rise further, presenting a major issue for the future.

This study has several strengths. First, this strategy reduces the burden not only on medical personnel but also on patients. Urgent endoscopic procedures, especially at night, cause significant physical and psychological stress to medical staff, and even more to the patient, who must undergo bowel preparation while in a poor general condition. Considering that nearly 90% of diverticular bleeding achieves hemostasis spontaneously and the rate of identification of SRH by early colonoscopy is low, this strategy, which aims to identify only life-threatening bleeding, could be useful in clinical practice. Second, it is cost-effective in cases of diverticular bleeding. Diverticular bleeding is known to recur in approximately one-third of patients [33, 35], often within a few months. In addition, a large proportion of patients are older, and repeated endoscopic examinations are costly and physically demanding. In the absence of preventive measures for diverticular bleeding, once other bleeding sources have been ruled out by colonoscopy, cases with repeated spontaneous hemostasis can be managed with conservative treatment alone, in accordance with this strategy.

However, this study also presents two limitations. The first is use of CECT for evaluation of active bleeding. Although CECT is quick and allows evaluation of blood flow throughout the body, it poses challenges due to radiation exposure and risk of contrast nephropathy in patients with severe renal dysfunction. Magnetic resonance imaging is also difficult to use in the presence of severe renal dysfunction and does not allow dynamic study of the entire intestinal tract. Although ultrasonography contrast agents can be used regardless of renal function, they make it difficult to evaluate intestinal blood flow. Currently, real-time evaluation of intestinal blood flow is only possible with CECT, and development of contrast agents that can be used even in renal impairment is a major challenge. Second, this was a single-center, single-arm study. Although a random-

ized controlled trial is desirable to clarify the usefulness of a treatment strategy, we have confirmed the usefulness of this strategy in a retrospective study. Given that most cases of colonic diverticular bleeding achieve spontaneous hemostasis, performing colonoscopy in all cases is burdensome for both the medical staff and patients. A multicenter study is necessary to further validate the usefulness of this strategy.

## Conclusions

In summary, most colonic diverticular bleeding stops spontaneously. However, there are a small number of cases requiring hemostatic intervention, and it is important to detect these cases. We believe that widespread use of this strategy is expected to provide efficient medical care that is less burdensome physically, psychologically, and economically, not only for patients but also for healthcare professionals.

## Acknowledgement

We would like to express our gratitude to Keisuke Watanabe, Hideto Imai, Ryuichi Watanabe, and Satoru Ishida for their assistance in data collection and patient care.

## Conflict of Interest

The authors declare that they have no conflict of interest.

## Clinical trial

UMIN Japan (<http://www.umin.ac.jp/english/>)  
Registration number (trial ID): UMIN00028007  
Type of Study: Prospective, Single-Center study

## References

- [1] Oakland K, Guy R, Uberoi R et al. Acute lower GI bleeding in the UK: patient characteristics, interventions and outcomes in the first nationwide audit. *Gut* 2018; 67: 654–662 doi:10.1136/gutjnl-2016-313428
- [2] Niikura R, Yasunaga H, Yamaji Y et al. Factors affecting in-hospital mortality in patients with lower gastrointestinal tract bleeding: a retrospective study using a national database in Japan. *J Gastroenterol* 2015; 50: 533–540
- [3] Isohata N, Nagata K, Utano K et al. Recent trends in the prevalence and distribution of colonic diverticula in Japan evaluated using computed tomography colonography. *World J Gastroenterol* 2021; 27: 4441–4452 doi:10.3748/wjg.v27.i27.4441
- [4] Olafsson GD, Hreinsson JP, Björnsson ES. Incidence of diverticular bleeding: a population-based study. *Scand J Gastroenterol* 2019; 54: 205–209 doi:10.1080/00365521.2019.1566494
- [5] Takada H, Kadokura M, Yasumura T et al. Extravasation and fluid collection on computed tomography imaging in patients with colonic diverticular bleeding. *PLOS ONE* 2020; 15: e0229884
- [6] Poncet G, Heluwaert F, Voirin D et al. Natural history of acute colonic diverticular bleeding: A prospective study in 133 consecutive pa-



- tients. *Aliment Pharmacol Ther* 2010; 32: 466–471 doi:10.1111/j.1365-2036.2010.04362.x
- [7] Jensen DM, Machicado GA, Jutabha R et al. Urgent colonoscopy for the diagnosis and treatment of severe diverticular hemorrhage. *N Engl J Med* 2000; 342: 78–82 doi:10.1056/NEJM20001133420202
- [8] Niikura R, Nagata N, Yamada A et al. Efficacy and safety of early vs elective colonoscopy for acute lower gastrointestinal bleeding. *Gastroenterology* 2020; 158: 168–175 e6 doi:10.1053/j.gastro.2019.09.010
- [9] Ichita C, Nakajima M, Ohbe H et al. Effectiveness of early colonoscopy in patients with colonic diverticular hemorrhage: Nationwide inpatient analysis in Japan. *Dig Endosc* 2023; 35: 520–528
- [10] Ishii N, Setoyama T, Deshpande GA et al. Endoscopic band ligation for colonic diverticular hemorrhage. *Gastrointest Endosc* 2012; 75: 382–387 doi:10.1016/j.gie.2011.07.030
- [11] Doi H, Sasajima K, Takahashi M. Using an over-the-scope clip for colonic diverticular hemorrhage. *Dig Endosc* 2019; 31: e80–e81 doi:10.1111/den.13384
- [12] Akutsu D, Narasaka T, Kobayashi K et al. Newly developed endoscopic detachable snare ligation therapy for colonic diverticular hemorrhage: a multicenter phase II trial (with videos). *Gastrointest Endosc* 2018; 88: 370–377
- [13] Saito M, Sudo G, Takai S et al. Direct clipping using underwater inversion method for colonic diverticular bleeding. *VideoGIE* 2022; 7: 187–189 doi:10.1016/j.vgie.2022.01.008
- [14] Yamamoto K, Shiratori Y, Ikeya T. Utility of the gel immersion method for treating massive colonic diverticular bleeding. *Clin Endosc* 2021; 54: 256–260 doi:10.5946/ce.2020.081
- [15] Okagawa Y, Fujii R, Sumiyoshi T et al. A novel technique using a multiloop traction device for colonic diverticular bleeding. *Endoscopy* 2023; 55: E47–E48 doi:10.1055/a-1893-5973
- [16] Ochi M, Kamoshida T, Hamano Y et al. Early colonoscopy and urgent contrast enhanced computed tomography for colonic diverticular bleeding reduces risk of rebleeding. *World J Clin Cases* 2021; 9: 2446–2457 doi:10.12998/wjcc.v9.i11.2446
- [17] Oguri N, Ikeya T, Kobayashi D et al. Effectiveness of risk scoring systems in predicting endoscopic treatment in colonic diverticular bleeding. *J Gastroenterol Hepatol* 2020; 35: 815–820 doi:10.1111/jgh.14901
- [18] Smoot RL, Gostout CJ, Rajan E et al. Is early colonoscopy after admission for acute diverticular bleeding needed? *Am J Gastroenterol* 2003; 98: 1996–1999 doi:10.1111/j.1572-0241.2003.07635.x
- [19] Seth A, Khan MA, Nollan R et al. Does urgent colonoscopy improve outcomes in the management of lower gastrointestinal bleeding? *Am J Med Sci* 2017; 353: 298–306
- [20] Doi H, Sasajima K, Takahashi M et al. Effectiveness of conservative treatment without early colonoscopy in patients with colonic diverticular hemorrhage. *Can J Gastroenterol Hepatol* 2020; 2020: 3283940
- [21] Ishii N, Hirata N, Omata F et al. Location in the ascending colon is a predictor of refractory colonic diverticular hemorrhage after endoscopic clipping. *Gastrointest Endosc* 2012; 76: 1175–1181 doi:10.1016/j.gie.2012.07.040
- [22] Meyers MA, Alonso DR, Gray GF et al. Pathogenesis of bleeding colonic diverticulosis. *Gastroenterology* 1976; 71: 577–583
- [23] SenGupta N, Tapper EB, Feuerstein JD. Early versus delayed colonoscopy in hospitalized patients with lower gastrointestinal bleeding: a meta-analysis. *J Clin Gastroenterol* 2017; 51: 352–359 doi:10.1097/MCG.0000000000000602
- [24] Loffroy R. Multidetector CT angiography for the detection of colonic diverticular bleeding: when, how, and why? *Dig Dis Sci* 2013; 58: 1822–1824 doi:10.1007/s10620-013-2710-1
- [25] Saffouri E, Blackwell C, Laursen SB et al. The Shock Index is not accurate at predicting outcomes in patients with upper gastrointestinal bleeding. *Aliment Pharmacol Ther* 2020; 51: 253–260
- [26] Kobayashi K, Nagata N, Furumoto Y et al. Effectiveness and adverse events of endoscopic clipping versus band ligation for colonic diverticular hemorrhage: a large-scale multicenter cohort study. *Endoscopy* 2022; 54: 735–744 doi:10.1055/a-1705-0921
- [27] Okamoto T, Nakamura K, Yamamoto K et al. Safety and effectiveness of endoscopic band ligation for colonic diverticular bleeding in elderly patients. *Digestion* 2021; 102: 760–766 doi:10.1159/000513310
- [28] Nagata N, Niikura R, Ishii N et al. Cumulative evidence for reducing recurrence of colonic diverticular bleeding using endoscopic clipping versus band ligation: systematic review and meta-analysis. *J Gastroenterol Hepatol* 2021; 36: 1738–1743 doi:10.1111/jgh.15370
- [29] Tominaga N, Ogata S, Esaki M. Rare complication of endoscopic band ligation for colonic diverticular bleeding. *JGH Open* 2020; 4: 1244–1245 doi:10.1002/jgh3.12407
- [30] Sato Y, Yasuda H, Fukuoka A et al. Delayed perforation after endoscopic band ligation for colonic diverticular hemorrhage. *Clin J Gastroenterol* 2020; 13: 6–10 doi:10.1007/s12328-019-01027-0
- [31] Takahashi S, Inaba T, Tanaka N. Delayed perforation after endoscopic band ligation for treatment of colonic diverticular bleeding. *Dig Endosc* 2016; 28: 484 doi:10.1111/den.12627
- [32] Kawano K, Takenaka M, Kawano R et al. Efficacy of over-the-scope clip method as a novel hemostatic therapy for colonic diverticular bleeding. *J Clin Med* 2021; 10: 2891 doi:10.3390/jcm10132891
- [33] Gobinet-Suguro MS, Nagata N, Kobayashi K et al. Treatment strategies for reducing early and late recurrence of colonic diverticular bleeding based on stigmata of recent hemorrhage: a large multicenter study. *Gastrointest Endosc* 2022; 95: 1210–1222 e12 doi:10.1016/j.gie.2021.12.023
- [34] Watanabe S, Miyakawa A, Sato A et al. Development of risk scores for early and late recurrence of colonic diverticular hemorrhage. *Eur J Gastroenterol Hepatol* 2023; 35: 248–254 doi:10.1097/MEG.0000000000002478
- [35] Sato Y, Aoki T, Sadashima E et al. Long-term risks of recurrence after hospital discharge for acute lower gastrointestinal bleeding: A large nationwide cohort study. *Clin Gastroenterol Hepatol* 2023; 21: 3258–3269 e6 doi:10.1016/j.cgh.2023.05.021